

# Prilog poznavanju nasilja u kasnosrednjovjekovnom Ivancu (grobovi 202 i 204)

---

Krznar, Siniša; Belaj, Juraj; Bedić, Željka

Source / Izvornik: **Prilozi Instituta za arheologiju u Zagrebu, 2010, 27, 225 - 240**

Journal article, Published version

Rad u časopisu, Objavljena verzija rada (izdavačev PDF)

Permanent link / Trajna poveznica: <https://um.nsk.hr/um:nbn:hr:291:247352>

Rights / Prava: [Attribution 3.0 Unported](#)/[Imenovanje 3.0](#)

Download date / Datum preuzimanja: **2024-09-17**



INSTITUT ZA  
ARHEOLOGIJU

Repository / Repozitorij:

[RIARH - Repository of the Institute of archaeology](#)

# Prilog poznavanju nasilja u kasnosrednjovjekovnom Ivancu (grobovi 202 i 204)

## *A Contribution to the Knowledge of Violence in the Late Middle Ages in Ivanec (graves 202 and 204)*

Izvorni znanstveni rad  
Srednjovjekovna arheologija

*Original scientific paper  
Medieval archaeology*

UDK/UDC 904:726.8(497.5Ivanec)"652"

Primljeno/Received: 01. 05. 2010.

Prihvaćeno/Accepted: 09. 12. 2010.

SINIŠA KRZNAR  
JURAJ BELAJ  
Institut za arheologiju  
Ljudevita Gaja 32  
HR-10000 Zagreb  
sinisa.krznar@iarh.hr  
juraj.belaj@iarh.hr

ŽELJKA BEDIĆ  
Odsjek za arheologiju HAZU  
A. Kovačića 5  
HR-10000 Zagreb  
zbedic@hazu.hr

*Arheološkim istraživanjima na lokalitetu Stari grad u Ivancu do sada je pronađeno 270 grobova. Početak ukopavanja pokojnika na nalazištu može se datirati u kraj 11. ili početak 12. stoljeća, a kraj u početak 17. stoljeća. Grobovi obrađeni u ovom radu mogu se na temelju stratigrafskih odnosa datirati u drugu polovicu 13. ili početak 14. stoljeća, a razlikuju se od ostalih po prisutnosti perimortalnih trauma te nalazu noževa uz pokojnike. Grob 202 jedini je do sada pronađeni grob na ovome lokalitetu koji ima nadgrobnu ploču. Perimortalne traume pronađene na kosturima iz ovih grobova dovele su do smrti analiziranih jedinki. Na temelju svojih karakteristika mogu se svrstati u kategoriju posjekotina i smatrati posljedicom nasilja među pojedincima.*

*Ključne riječi: Ivanec, nasilje, groblje, kasni srednji vijek, perimortalne traume*

*Archaeological excavations carried out so far at the Stari Grad site in Ivanec have revealed 270 graves. The first graves at the site can be dated back to the end of the 11<sup>th</sup> or the beginning of the 12<sup>th</sup> centuries, and the last to the beginning of the 17<sup>th</sup> century. Based on stratigraphic relationships, the graves covered in this article can be dated back to the second half of the 13<sup>th</sup> or the beginning of the 14<sup>th</sup> centuries; they differ from others in that the deceased buried in them displayed perimortal traumas and had been buried with knives at their side. So far, grave 202 is the only grave found at the site which was covered by a gravestone. The perimortal traumas found on the skeletons from these graves are responsible for the death of the individuals analysed. Based on their characteristics, these traumas can be classified as cut wounds resulting from intentional violence between individuals.*

*Key words: Ivanec, violence, cemetery, Late Middle Ages, perimortal traumas*

### Uvod

Grad Ivanec smješten je na cesti koja iz Varaždina vodi preko Lepoglave za Krapinu. U središnjem gradskom parku, sjeverno od župne crkve, nalazi se lokalitet *Stari grad*, tako nazvan prema renesansnome kaštelu koji se do sredine prošloga stoljeća ovdje nalazio. U arheološkim istraživanjima koja od 1998. godine provodi Institut za arheologiju ustanovljen je dug kontinuitet nastanjanja ovoga položaja. U najstarije nalaze ubrajaju se ulomci prapovijesnih keramičkih posuda te antičkih opeka, tegula i također keramičkih posuda. O životu u kasnoj antici najrječitije govori pronađeni ulomak kasnoantičkoga nadgrobnog žrtvenika – are iz 3. ili 4. stoljeća nakon Krista (Belaj 2008: 44–45, sl. 64). Najstariji, pak, koliko-toliko sačuvani slojevi na lokalitetu obilježeni su nalazima provincijalne antičke keramike – “smeđi” sloj – te, iznad njega, sloj srednjovjekovnoga naselja – “crni” sloj. Prema oblicima i fakturama pronađenih

### Introduction

The town of Ivanec is located on the road leading from Varaždin, via Lepoglava, to Krapina. Located in the central city park, north of the parish church, is the site of *Stari grad*, named after a Renaissance citadel that existed here until the middle of the 20<sup>th</sup> century. Archaeological excavations conducted by the Institute of Archaeology since 1998 have established a long period of continuous habitation at the site. The oldest findings include fragments of prehistoric ceramic vessels, as well as antique bricks, tegulae and, again, ceramic vessels. The most eloquent testimony to the way of life in Late Antiquity is a fragment of a Late Antique grave altar, i.e. an ara, from the 3<sup>rd</sup> or 4<sup>th</sup> century AD (Belaj 2008: 44–45, fig. 64). The oldest, fairly well-preserved strata at the site contain provincial antique ceramics (the “brown” stratum), overlaid by a medieval settlement stratum (the “black” stratum). The shapes and structures of the ceramic

keramičkih ulomaka potonji sloj možemo preliminarno i s oprezom datirati u 9. ili 10. stoljeće (Belaj 2008: 40). Od tragova naselja nešto je mlađe groblje na redove, ukopano u spomenuti sloj. Radiokarbonskom analizom izotopa atoma ugljika (<sup>14</sup>C) utvrđeno je da su pojedini grobovi ukopani krajem 11. ili početkom 12. te početkom 13. stoljeća, dakle u vrijeme trajanja bjelobrdske kulture i prije provale Mongola (Belaj 2008: 37–38). Možda je tome groblju suvremena bila crkva čiji su temelji otkriveni 2009. godine u sjevernome dijelu lokaliteta, unutar središnje, pravokutne renesansne kule (tlocrt 1), a čija se istraživanja nastavljaju (Belaj, Sirovica 2010). Svetost je ovoga prostora nastavljena i u narednim stoljećima – uskoro je, tek nekoliko metara jugozapadnije, građena još jedna crkva – župna crkva sv. Ivana Krstitelja koja nam je poznata i iz povijesnih izvora. Moguće je da je građena nakon što je starija crkva srušena jer su u temeljima gotičke crkve nađeni ulomci kapitela romaničkih oblika – možda ostaci susjedne, romaničke crkve (Belaj, Sirovica 2010). Temelji gotičke crkve, koji su bili tek neznatno, za nekoliko stupnjeva drukčije orijentacije, presjekli su pojedine starije grobove. Ukopavanje se nastavilo i u crkvi i uokolo nje. Čini se da su posljednji grobovi u ovu crkvu ukopani početkom 17. stoljeća, kada započinje ukapanje u obližnjoj novoj župnoj crkvi sv. Marije Magdalene. U to je vrijeme crkvu i groblje oko nje već mogao zaokružiti i kaštel koji je s vremenom nastao uz crkvu i uslijed brojnih dogradnji rasta. Stoga je i samo ukapanje moralo prestati.

Iz navedenoga je vidljivo da se na lokalitetu ukopavalo barem pet do pet i pol stoljeća. Tijekom dosadašnjih istraživanja otkriveno je i arheološki istraženo 270 grobova unutar i uokolo dviju pronađenih crkava. Oni se, na temelju nalaza, pojedinih značajki, ali prvenstveno stratigrafskoga odnosa mogu razvrstati u više faza ukopavanja. U grubim crtama, jer za više ovom prigodom nema prostora, istaknut ćemo osnovne značajke pojedinih faza ukopavanja.

Najstarijoj fazi pripadaju grobovi u kojima su pronađene karičice sa S-petljom te grobovi koji su imali kamenu oblogu po rubovima ukopa. Kod nekih je grobova obloga dobro uočljiva, dok je kod više njih ostalo sačuvano tek po nekoliko komada kamenova te se ne može sa sigurnošću tvrditi je li doista riječ o oblozi. Najveća je gustoća grobova ove faze uočena na prostoru starije crkve, gdje se oni međusobno čak i presijecaju. U grobovima ove faze nalazi su vrlo rijetki, ističu se srebrne S-karičice.

Tijekom srednje faze ukopavanja nestaju obloge grobova, a pokojnici su i dalje sahranjeni s rukama ispruženima uz tijelo, šake su im ponekad položene na zdjelicu ili pod nju. Starija srednja faza također je vezana uglavnom uz stariju crkvu: ovoj fazi pripadaju pojedini grobovi pronađeni unutar broda i svetišta romaničke crkve te relativno brojni dječji grobovi pronađeni uza zidove ove crkve. Nalazi su rijetki, češće brončani negoli željezni (prstenje na primjer), a nerijetko se u grobovima nalaze pojedinačni životinjski zubi – vjerojatno amuleti.

U grobovima mlađe srednje faze nalazi su također rijetki: njima pripadaju i noževi iz grobova 202 i 204 o kojima će biti riječ u ovome radu. Grobovi ove faze bili su uglavnom pažljivo ukopani u redove i na području romaničke crkve nisu se međusobno presijecali. Unutar gotičke crkve ipak se

fragments allow us to date the latter stratum, preliminarily and with caution, back to the 9<sup>th</sup> or 10<sup>th</sup> century (Belaj 2008: 40). The traces of the settlement are marginally predated by a row-grave cemetery, also found in this stratum. Radiocarbon analysis has dated certain graves back to the late 11<sup>th</sup> or early 12<sup>th</sup> century, and the beginning of the 13<sup>th</sup> century, i.e. to the period of the Bijelo Brdo culture, before the Mongol invasion (Belaj 2008: 37–38). The cemetery may have been contemporaneous with a church the foundations of which were discovered in 2009 in the northern area of the site, inside the central rectangular Renaissance tower (plan 1), which is still being excavated (Belaj, Sirovica 2010). The sanctity of the site was preserved throughout the following centuries and another church was soon built only several metres further to the southwest – the parish Church of St. John the Baptist known to us from historical sources. It may have been built after the older church had been torn down because the foundations of the Gothic church contain fragments of Romanesque-style capitals – possibly the remains of a neighbouring Romanesque church (Belaj, Sirovica 2010). The foundations of the Gothic church, oriented in a slightly different direction, bisect certain earlier graves. Graves continued to be dug both within the church and around it. The last graves in this church seem to date back to the beginning of the 17<sup>th</sup> century, when burials started in the nearby new parish church of St. Mary Magdalene. By that time the church and the surrounding cemetery might have already been encircled by the citadel which had developed around the church and kept expanding. Consequently, burials had to be discontinued.

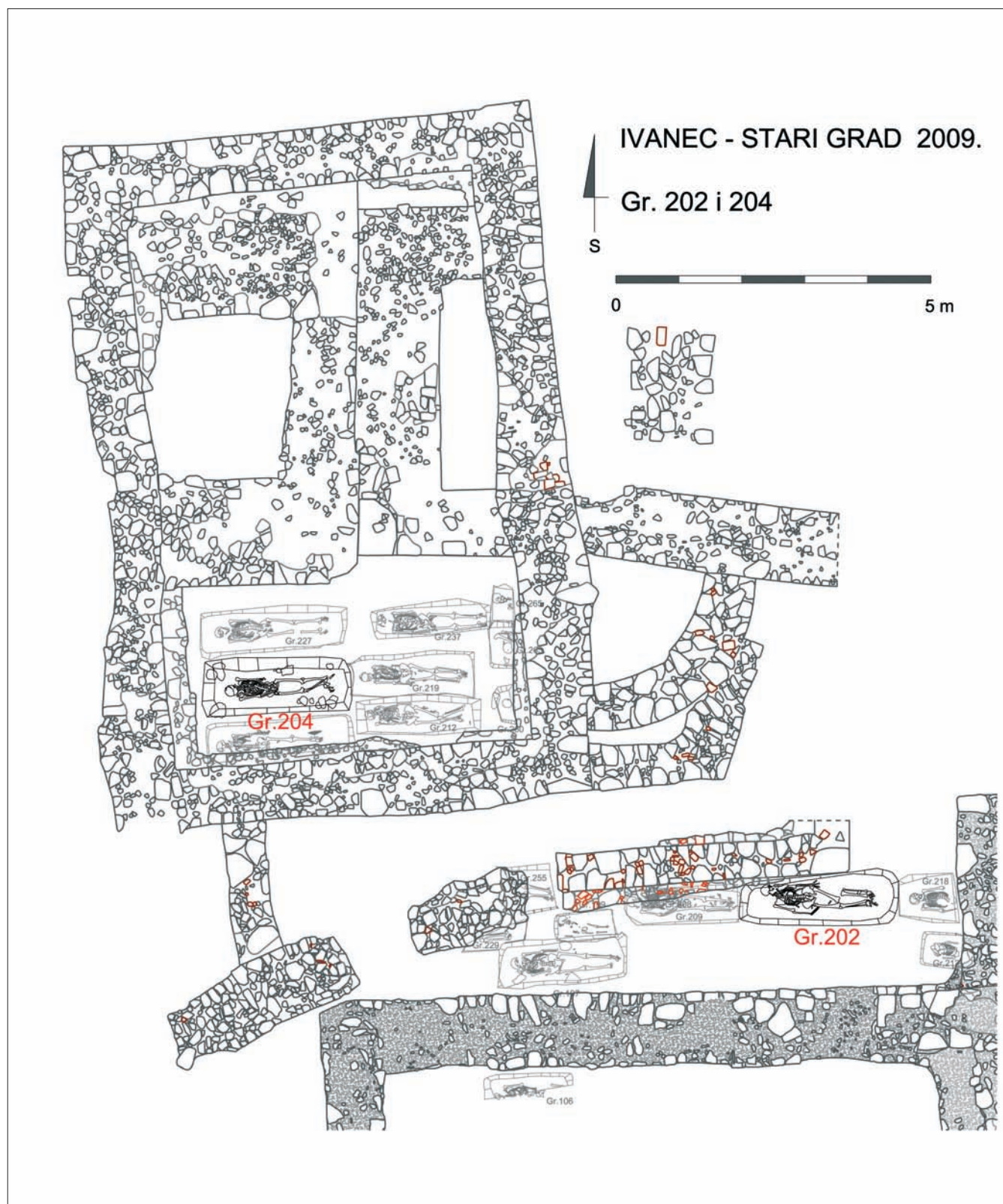
It can be concluded from the above that burials were conducted at this site for at least five to five and a half centuries. Excavations conducted so far have revealed 270 graves in and around the two churches, which were all archaeologically investigated. Based on the findings, some particular characteristics and, primarily, their stratigraphic relationship, the graves can be divided into several burial phases. Due to space constraints, we will only briefly outline the basic traits of individual burial phases.

The oldest phase consists of graves containing S-shaped loops and graves lined with stone. While the stone lining is highly visible on some graves, on many others only several pieces of stone remain, making it impossible to claim with certainty that they were, indeed, stone-lined.

In this phase, grave density is the highest in the area of the older church, where they sometimes bisect each other. Standing out among the rare findings from these graves are silver S-shaped loops.

During the middle phase, the stone lining disappeared but the deceased were still buried with arms to their sides and their arms sometimes placed under or over the pelvis. The early middle phase is also predominantly linked with the older church: it includes individual graves found within the nave and the sanctuary of the Romanesque church, as well as a relatively large number of children's graves found along its walls. Findings are rare, more often made of bronze than iron (rings, for instance) and the presence of individual animal teeth in the graves – presumably amulets – is not uncommon.

Findings from the graves belonging to the late middle



Tlocrt 1 Ivanec – Stari grad, tlocrt dijela lokaliteta s ucrtanim grobovima mlađega srednjeg horizonta (nacrtale: N. Kovačević, I. Peharda i A. Kudelić)

Plan 1 Ivanec, Stari grad, section of the site with late middle horizon graves (drawing: N. Kovačević, I. Peharda and A. Kudelić)

malo međusobno sijeku, što možda govori o intenzivnijem ukopavanju te faze upravo na tom području. Najvjerojatnije je ova faza ujedno i prva faza ukopavanja u noviju, gotičku crkvu sv. Ivana i uz nju, a grobovi su u njoj slabo očuvani jer su uglavnom poslije bili uništeni grobovima mlađih faza

phase are also rare: they include knives from graves 202 and 204, of which there will be further mention in this article. Most of the graves of this phase were carefully positioned in rows and, in the Romanesque church, did not bisect each other. Within the Gothic church, however, there is a certain

kad je ukopavanje bilo najintenzivnije. Time bismo grobove ove faze, okvirno dakako, mogli smjestiti u 13. stoljeće, osobito u njegovu drugu polovicu, te možda još i u iduće, 14. stoljeće.

Grobove najmlađe faze treba vezati isključivo uz mlađu, gotičku crkvu sv. Ivana. Na prostoru starije crkve i njezine okolice oni nisu ni uočeni. U ovim se grobovima često nalaze tragovi lijesa i/ili čavala, a pokojnici su pokopani s rukama prekrženima na prsima ili trbuhu. Vrlo su česti nalazi željeznih pređica. Posljednji ukopani grobovi u crkvi sv. Ivana probili su debeli izolacijski sloj žute gline ispod kamenog popločenja. Čini se da je tih nekoliko grobova ukopano već u vrijeme kada je Stari grad postojao, stoga smijemo pretpostaviti da je riječ o grobovima samih vlasnika Staroga grada.

### Antropološka analiza

Antropološka analiza osteološkog materijala s lokaliteta Stari grad provedena je na 243 kostura. Kako je taj broj grobnih cjelina istraživao u nekoliko sezona, do sada su preliminarno objavljeni podaci samo za prva 34 groba, tj. za one istražene do 2004. godine (Novak et al. 2005). Ti grobovi pripadaju različitim fazama ukopavanja na lokalitetu i vremenski pokrivaju cijeli tijek njegova trajanja. Najstariji se grobovi mogu datirati u kraj 11. ili početak 12. stoljeća, kao što je radiokarbonskom analizom utvrđeno za grob 25, a najmlađi u prvu polovicu 17. stoljeća (Belaj 2008: 26, 38).

Traume na analiziranom osteološkom materijalu pokazuju učestalost nasilja u određenom vremenskom periodu, njegovu distribuciju unutar arheološke populacije i jesu li traume posljedica nasilja ili nesretnih slučajeva. Veći broj trauma na glavi i licu povezuje se s povećanim rizikom od nasilja u nekoj zajednici (Walker 1989; 1997; Alvrus 1999; Standen, Ariazza 2000). Takve traume, koje su rezultat nasilja, posebno su zanimljive jer svjedoče o povremenim epizodama nasilnih sukoba iz prošlosti. Traume izazvane oružjem s oštrim sječivom nerijetko završavaju i smrću osobe ili osoba uključenih u sukob.

Na lokalitetu Ivanec – Stari grad perimortalne ozljede zamijećene su na kosturnim ostacima iz dvaju grobova (grobovi 202 i 204) koji će u ovom radu biti detaljnije opisani.

### Materijal i metode

U ukupnom do sada istraženom uzorku najzastupljeniji su dječji kosturi (89), zatim muški (76), a najmanje je osoba ženskog spola (63). Zbog vrlo slabe očuvanosti, spol i starost nisu se mogli ustanoviti kod 15 osoba. Spol je na kostima određen na temelju morfologije zdjelice (Phenice 1969) i lubanje (Krogman, Iscan 1986). Starost u trenutku smrti određena je pomoću većeg broja metoda, uključujući: stupanj srastanja lubanjskih šavova (Meindl, Lovejoy 1985), promjene na spojnoj ploštini preponske kosti zdjelice (Gilbert, McKern 1973; Brooks, Suchey 1990), promjene na zglobnoj ploštini bočne kosti zdjelice (Lovejoy et al. 1985) te promjene na prednjim krajevima rebra (Iscan et al. 1984; 1985). Osim ovih metoda, u obzir je uzeta i pojava degenerativnih promjena na zglobnim ploštinama dugih kostiju i kralježaka (Pfeiffer 1991) i stupanj istrošenosti zuba (Lovejoy 1985).

degree of bisection, which may indicate that the digging of graves in this area had intensified during this period. This phase was probably also the first phase during which graves were dug in and around the new Gothic church of St. John; these graves are poorly preserved because they were destroyed by the graves of later phases, when grave digging was the most intense. Graves from this phase could thus be dated, approximately of course, back to the 13<sup>th</sup> century, in particular its second half, and perhaps also to the following, 14<sup>th</sup> century.

The graves of the latest phase should be linked exclusively to the more recent Gothic church of St. John. None were found in the older church or its surroundings. These graves frequently reveal traces of coffins and/or nails, and the deceased are buried with their arms crossed on the chest or the abdomen. Iron buckles can frequently be found. The last graves dug in the church of St. John broke through the thick insulating layer of yellow clay underneath the stone slabs. These several graves seem to date back to the time when Stari Grad already existed, so we may presume that they belong to the owners of Stari Grad.

### Anthropological analysis

Anthropological analysis of the osteological material from the Stari Grad site was conducted on 243 skeletons. As the excavations of these grave units continued during several seasons, preliminary data has so far been published only for the first 34 graves, i.e. those examined by 2004 (Novak et al. 2005). These graves belong to various burial phases and cover the entire temporal duration of the site. The oldest graves can be dated back to the end of the 11<sup>th</sup> or the beginning of the 12<sup>th</sup> century, as established by carbon dating for grave no. 25, and the most recent ones to the first half of the 17<sup>th</sup> century (Belaj 2008: 26, 38).

The traumas on the analysed osteological material reveal the frequency with which violence occurred in a particular period of time, its distribution within the archaeological population and whether they were caused by intentional violence or accidents. The large number of traumas to the head and face is linked with the increased risk of intentional violence in a given community (Walker 1989; 1997; Alvrus 1999; Standen, Ariazza 2000). Traumas caused by intentional violence are of particular interest because they bear testimony to sporadic episodes of violence in the past. Traumas caused by bladed weapons frequently result in the death of the person, or persons, involved in the conflict.

The perimortem injuries observed on skeletal remains from two graves (graves 202 and 204) at the Ivanec – Stari Grad site will be described in further detail later in this article.

### Material and methods

The highest number of skeletons in the inspected sample were subadults (89), followed by males (76) and females, which were the least numerous (63). The sex and age of 15 skeletons could not be determined due to the poor state of their preservation. Sex was determined on the basis of pelvic (Phenice 1969) and cranial (Krogman, Iscan 1986) morphology. Age at the time of death was determined by a number of methods, including: cranial suture closure

Schmorlovi defekti nastaju uslijed prolapsa intervertebralnog diska u tijelo kralješka, a morfološki se prepoznaju kao plitki okrugli ili bubrežasti defekti na superiornoj ili inferiornoj plohi trupa kralješka. Prisutnost tih defekata obično se povezuje s jakim mehaničkim opterećenjima kralježnice (Schmorl, Junghanns 1971). Trošenje zglobne hrskavice koja se stanjuje do te mjere da na nekim područjima zgloba može potpuno nestati uzrokuje degenerativni osteoartritis. Tada dolazi do kontakta između koštanih elemenata u zglobu što izaziva kondenziranje ili skleroziranje suphondralne kosti te se na rubovima zglobova stvara novo koštano tkivo – osteofit, a prema stupnju može biti blagi, umjereni ili jaki. Razvoju osteoartritisa najviše pridonose mehanički stres i fizička aktivnost (Hough, Sokoloff 1989).

Linearna hipoplazija zubne cakline makroskopski je defekt u obliku tankih paralelnih linija na površini labijalne strane zubne cakline (Pindborg 1970). Taj subadultni poremećaj Goodman i Rose (1991) povezuju s gladovanjem, nedostatkom vitamina A, C i D, prisutnošću anemije i psihičkom i/ili fizičkom traumom. Pomoću formule koja koristi duljinu bedrene kosti izračunata je visina kostura (Trotter, Gleser 1952).

Traumatske promjene na kostima dijele se na antemortalne i perimortalne. Antemortalne traume karakterizira remodelirana lezija ili fraktura koja je nastala prije smrti (Aufderheide, Rodriguez-Martin 1998). Perimortalne traume (nastale u trenutku smrti ili oko njega) na koštanom se materijalu prepoznaju po boji kosti na rubovima koja je jednaka okolnoj kosti (Ubelaker, Adams 1994) i po tome što nema tragova zacjeljivanja kosti (Aufderheide, Rodriguez-Martin 1998). Traume se razlikuju i po oružju kojim su nanesene. Teški i tvrdi predmeti uzrokuju depresijske frakture, a predmeti oštih bridova ubodne rane i posjekotine. Ubodne rane su dublje nego šire i imaju polirane rubove. Kod posjekotina rana je šira nego dublja i kost je polirana na mjestu inicijalnog kontakta između oštrice i kosti, dok je usporedni rub posjekotine grub i nepravilan. Na taj se način može rekonstruirati kut i smjer iz kojeg je udarac nanesen (Šlaus 2006: 184). Prema Wenhamu (1989), kriteriji koji se također koriste za utvrđivanje ozljeda nastalih oštrobridnim predmetom jesu: glatka, ravna površina reza, jasno definiran rub posjekotine i prisutnost paralelnih tragova na odsječenom dijelu kosti.

## Rezultati

Prilikom analize skeletnih ostataka iz Ivanca ustanovljena je prisutnost nekoliko perimortalnih trauma na kosturima iz grobova 202 i 204. Ukupna učestalost perimortalnih trauma u uzorku odraslih osoba iz Ivanca iznosi 1,4% (2/139), odnosno samo 0,9% (2/228) u ukupnom analiziranom uzorku. Perimortalne su traume rijetko zabilježene kod arheoloških populacija tijekom srednjeg i novog vijeka. Učestalost perimortalnih trauma po osobi tijekom tih razdoblja na području Hrvatske, Srbije te Bosne i Hercegovine nigdje nije viša od 2,3% osim u Čepinu (15,0%) gdje se radilo o upadu akindija i masakru te gdje su perimortalne traume zabilježene i na djeci (Šlaus et al. 2010: 361–362).

re (Meindl, Lovejoy 1985), surface changes in pubic bones (Gilbert, McKern 1973; Brooks, Suchey 1990), changes to the articular surface of the ilium (Lovejoy et al. 1985), and changes at the sternal end of the ribs (Iscan et al. 1984; 1985). In addition to these methods, degenerative changes in the articular surfaces of long bones and vertebrae (Pfeiffer 1991) were also taken into consideration, as well as the degree of tooth abrasion (Lovejoy 1985).

Schmorl's nodes are caused by the protrusion of the intervertebral disk into the vertebral body and can morphologically be described as flat circular or reniform defects on the superior or inferior surface of the body of vertebra. The presence of these defects is frequently connected with the vertebral column being subject to heavy mechanical stress (Schmorl, Junghanns, 1971). Abrasion of the articular cartilage, thinned down to such an extent that it may completely disappear in some areas of the joint, causes degenerative osteoarthritis, at which point the bone elements of the joint come into contact, causing condensation or sclerosis of the subchondral bone, which leads to the formation of new bone tissue – osteophyte, which can be mild, moderate or severe. The main contributors to the development of osteoarthritis are mechanical stress and physical activity (Hough, Sokoloff 1989). Linear enamel hypoplasia is a macroscopic defect in the form of thin parallel lines on the labial enamel surface (Pindborg 1970). Goodman and Rose (1991) established a connection between this subadult condition and hunger, insufficiency of vitamins A, C and D, anaemia, and mental and/or physical trauma. The height of the skeleton was calculated by means of a formula using the length of the thigh bone (Trotter, Gleser 1952).

Bone traumas are divided into antemortem and perimortem. Antemortem trauma is characterized by remodelled lesions or fractures which occurred before death (Aufderheide, Rodriguez-Martin 1998). Perimortem bone trauma (occurring at or around the time of death) can be recognised by the identical colour of the bone edges and the surrounding bone (Ubelaker, Adams 1994) and the fact that the bone had not healed (Aufderheide, Rodriguez-Martin 1998). Traumas also differ according to the type of weapons used to inflict them. Hard and heavy objects cause depression fractures, while objects with sharp edges cause stab wounds and cut wounds. Stab wounds are deeper than they are wide and have polished surfaces. A cut wound is wider than it is deep and the bone is polished at the point of initial contact between the blade and the bone, while the parallel edge of the cut is rough and irregular. It is thus possible to reconstruct the angle and direction of the blow (Šlaus 2006: 184). According to Wenham (1989), the criteria used for determining whether injuries were caused by a sharp-edged object also include: a smooth and straight surface of the cut, a clearly defined edge of the cut wound and the presence of parallel traces on the part of the bone that had been cut off.

## Results

The analysis of skeletal remains from Ivanec established the presence of several perimortem traumas on the skeletons from graves 202 and 204. The frequency of perimortem traumas in the adult sample from Ivanec is 1.4%

### Grob 202<sup>1</sup>

Grob 202 otkriven je sjeverno od broda gotičke, a jugoistočno od svetišta romaničke crkve. Bio je izrazito duboko ukopan, oko pola metra dublje od ostalih grobova ove faze, a poklopljen je bio masivnom nadgrobnom pločom o kojoj će biti još riječi. Ovaj grob vjerojatno pripada srednjoj fazi ukopavanja: nalazi se ispod groba 177 koji pripada mlađoj fazi, a prigodom čijeg ukopa položaj starijeg groba očito nije bio poznat. To je vidljivo po pokušajima razbijanja nadgrobne ploče prigodom ukopa groba 177 (Belaj 2009: 93, sl. 3). Izrazito dubok ukop ovoga groba presjekao je nekoliko grobova starijih od njega. Pokojnik je bio položen na leđa, s rukama uz tijelo (sl. 1, 2), a u desnoj je ruci imao željezni predmet (vjerojatno nož<sup>2</sup>), dužine oko 12 cm (sl. 3).

Radi se o ukopu muškarca čija je starost u trenutku smrti procijenjena na 45 do 50 godina. Kostur je očuvan u potpunosti, s odlično očuvanim korteksom. Procijenjena visina kostura je 181,5 cm. Na kosturu je zabilježeno mnoštvo promjena koje su posljedica teških životnih uvjeta, ali i relativno visoke životne dobi. Na desnoj palčanoj kosti prisut-

(2/139), i.e. a mere 0.9% (2/228) in the entire analysed sample. Perimortem traumas are rare among the archaeological populations of the Middle and Modern Ages. In these periods, the frequency of perimortem traumas per person on the territory of Croatia, Serbia and Bosnia and Herzegovina never exceeds 2.3%, except in Čepin (15.0%) which was attacked by the Akinji who massacred the population and where perimortem traumas can also be found on children (Šlaus et al. 2010: 361–362).

### Grave 202<sup>1</sup>

Grave 202 was discovered north of the nave of the Gothic and southeast of the sanctuary of the Romanesque church. It was dug in particularly deeply, approximately half a metre more deeply than other graves from this phase, and covered with a massive gravestone, which will be discussed in further detail later. This grave probably belongs to the middle phase: it is located under grave 177, which belongs to the later phase, and the position of the older grave was obviously unknown at the time of its digging. This can be



Sl. 1 Grob 202 (snimila: F. Sirovica)

Fig 1 Grave 202 (photo: F. Sirovica)

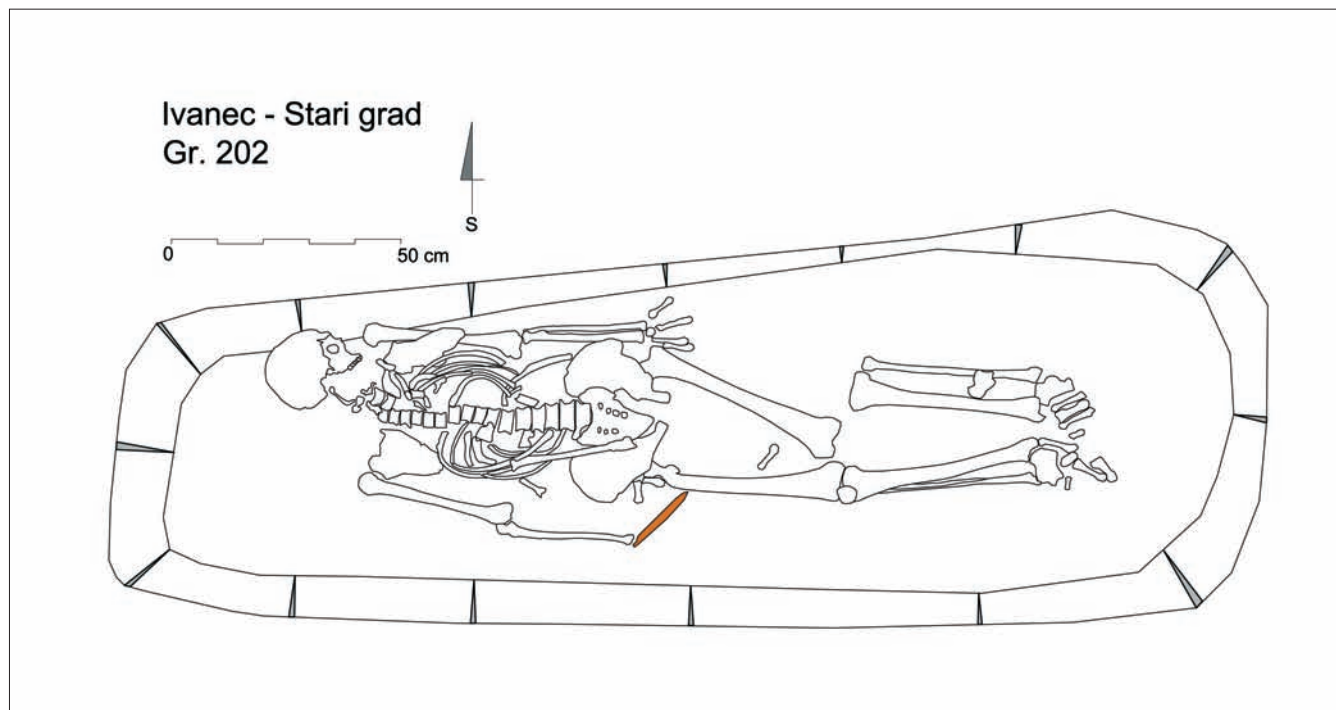
na je antemortalna dobro zarasla fraktura distalne trećine dijafize koja se očituje po blagom posteriornom pomaku. Linija frakture prisutna je i na distalnoj zglobojnoj ploštini, a

1 Grobovi obrađeni u članku (br. 202 i 204) prikazuju se opisno za potrebe ovdje obrađene teme, a detaljna kataloška obrada s tipološko-kronološkim određenjem priloženog materijala donijet će se u okviru obrade lokaliteta, odnosno srednjovjekovnog groblja *Ivanec – Stari grad*.

2 Konzervacija metalnih nalaza je u tijeku.

concluded from the attempts to break the gravestone during the digging of grave 177 (Belaj 2009: 93, fig. 3). This grave was dug in so deeply that it bisected several older

1 The graves discussed in this article (nos. 202 and 204) are being described for the purposes of the topic discussed; detailed catalogue processing and the typological and chronological definition of the material will be provided as part of the processing of the site, i.e. the Ivanec – Stari Grad medieval cemetery.



Sl. 2 Grob 202 (nacrtala: A. Kudelić)  
 Fig. 2 Grave 202 (drawing: A. Kudelić)



Sl. 3 Detalj: nož u grobu 202 (snimila: F. Sirovica)  
 Fig. 3 Detail: knife in Grave 202 (photo: F. Sirovica)

njena duljina iznosi cca 11 milimetara. Antemortalna fraktura također je prisutna na 11. lijevom rebro, a očituje se po remodeliranom kalusu i blagom zaraslom periostitisu koji je posljedica lokalizirane traume. Na temelju položaja, ove se frakture vežu uz posljedice nesretnog slučaja ili pada, a ne namjernog nasilja (Kilgore et al. 1997; Ortner, Putschar 1985). Blagi zarasli periostitis također je prisutan na lisnim i goljeničnim kostima, a u takvoj se distribuciji uglavnom veže uz nespecifične bakterijske infekcije, specifične zarazne bolesti ili metaboličke bolesti (Mann, Murphy 1990; Ortner 2003). Schmorlovi defekti, koji se uglavnom povezuju s kontinuiranim teškim fizičkim radom, prisutni su na 11. i 12. prsnom kralješku. Degenerativni osteoartritis zastupljen je u blagom obliku koštanih nodula na kralješcima, ramenima, laktovima, kukovima i koljenima, u umjerenom obliku na slabinskim kralješcima te u jakom obliku na prvom vratnom kralješku. Pregledom zubi zamiječena je linearna hipo-

graves. The deceased lay supine, with his arms to his sides (Fig. 1 and 2), holding in his arm an iron object (probably a knife<sup>2</sup>), approximately 12 cm in length (Fig. 3).

This is the grave of a man whose age at death has been estimated at 45 to 50. The skeleton is preserved in full, with excellently preserved cortex. The height of the skeleton has been estimated at 181.5 cm. The skeleton displays many changes caused both by difficult living conditions and relatively advanced age. The right radius displays a well-healed antemortem fracture of the distal third of the diaphysis manifested by a slight posterior shift. The fracture line extends to the distal articular surface, and is approximately 11 mm in length. There is another antemortem fracture, on the 11<sup>th</sup> left rib, manifested by a remodelled callus and slight healed periostitis caused by a localized trauma. Based on their location, these fractures are associated with an accident or fall, not intentional violence (Kilgore et al. 1997; Ortner, Putschar 1985). Slight healed periostitis is also visible on the tibiae and fibulae: this distribution is predominantly associated with non-specific bacterial infections, specific infectious diseases or metabolic diseases (Mann, Murphy 1990; Ortner 2003). Schmorl's nodes, usually associated with continuous hard physical labour, are present on the 11<sup>th</sup> and 12<sup>th</sup> thoracic vertebrae. Mild degenerative osteoarthritis in the form of bony nodules is present on the vertebrae, shoulders, elbows, hips and knees; moderate on lumbar vertebrae and severe on the 1<sup>st</sup> cervical vertebra. The examination of teeth revealed linear enamel hypoplasia and moderate to severe abrasion of occlusal surfaces, which further corroborated the man's age. A perimortem trauma on the skull was caused by intentional violence. The trauma is a cut, located on the left parietal bone, 39 mm inferior and lateral to the

<sup>2</sup> The conservation of metal items is under way.





Sl. 4 Polirani rub posjekotine na lijevoj tjemenoj kosti osobe iz groba 202 (snimio: S. Krzmar)

Fig 4 Polished surface of the cut wound on the left parietal bone of the person from grave 202 (photo: S. Krzmar)

plazija zubne cakline. Također je uočena umjerena do jaka istrošenost okluzalnih ploština zubi što ide u prilog starosti ovog muškarca. Na lubanji se izdvaja perimortalna trauma kao posljedica nasilja. Trauma je smještena na lijevoj tjemenoj kosti, 39 mm inferiorno-lateralno od bregme. Riječ je o posjekotini čija sačuvana duljina iznosi 58 mm. Postmortalno nedostaje dio kosti pa se potpuna duljina posjekotine ne može ustanoviti. Udarac, prilikom kojeg je nastala ova posjekotina, najvjerojatnije je probio svod lubanje. Na temelju poliranog superiornog ruba posjekotine može se zaključiti da je udarac zadan odozgo prema dolje (sl. 4).

### Grob 204

Grob 204 bio je ukopan nedaleko od temelja broda romaničke crkve. Pokojnik je bio sahranjen na leđima, s rukama položenima na zdjelicu (sl. 5, 6). Na prsa mu je bio položen dugi željezni nož s drškom na kojoj se nalaze ispupčenja za pričvršćivanje oplate (dužina noža je oko 37 cm zajedno s drškom) (sl. 7).

Kosti pripadaju muškarcu starome između 45 i 50 godina. Visina mu je procijenjena na 179 cm. Kostur je veoma dobro očuvan. Na obje lisne i goljениčne kosti prisutan je blagi zarasli periostitis. Schmorlovi defekti zabilježeni su na šest prsnih i dva slabinska kralješka. Osteoarthritis je prisutan u blagom, umjerenom i jakom obliku. Kod muškarca iz ovog groba blagi oblik je zabilježen na ramenima, koljenima, sedmom vratnom i petom slabinskom kralješku. Umjereni oblik prisutan je na ključnim kostima te na petom i šestom vratnom kralješku, a jaki na drugom i trećem vratnom te četvrtom i petom prsnom kralješku. Pregledom zubi ustanovljen je interproksimalni karijes na trećem lijevom kutnjaku donje čeljusti. Na ovome kosturu zabilježen je znatno veći broj perimortalnih trauma koje su posljedica nasilja. Riječ je o šest posjekotina, od kojih je pet smješteno na lubanji, a jedna na postkranijumu: 1) najveća posjekotina duljine 110 mm smještena je na lijevoj strani čeone kosti i lijevoj tjemenoj kosti – superiorni rub je inicijalan i poliran, a udarac je u potpunosti probio stijenku lubanje. Udarac je zadan odozgo prema dolje (sl. 8); 2) posjekotina koja je u potpunosti probila stijenku lubanje (sl. 9) nalazi se na lije-

bregma and 58 mm long. The full length of the cut wound cannot be determined due to the postmortem disappearance of part of the bone. The blow which caused the cut most probably broke through the cranial vault. Based on the polished superior surface of the cut we can conclude that the blow was delivered in a downward direction (Fig. 4).

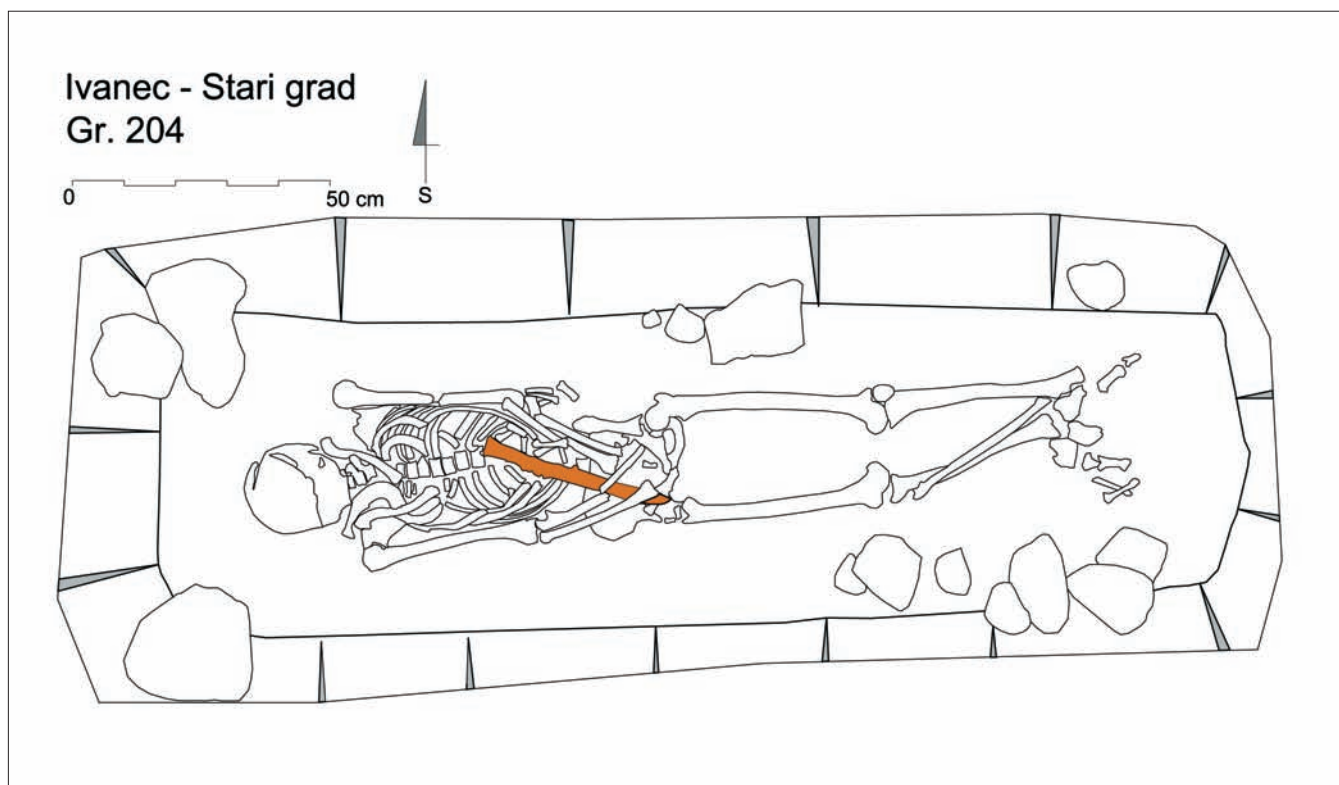
### Grave 204

Grave 204 is located not far from the foundations of the Romanesque church nave. The deceased was buried supine, hands placed on the pelvis (Fig. 5, 6). A long iron knife was placed on his chest, with bulges on the tang for attaching the scales of the handle (the length of the knife, including the handle, is approximately 37 cm) (Fig. 7).

The bones belong to a man between 45 and 50 years of age, of an estimated height of 179 cm. The skeleton is very well preserved. A slight healed periostitis can be observed on both tibiae and fibulae. Schmorl's nodes are present on six thoracic and two lumbar vertebrae. Osteoarthritis is present in mild, moderate and severe form: the mild form was observed on the shoulders, knees, seventh cervical and fifth lumbar vertebrae; the moderate form is present on the clavicles and the fifth and sixth cervical vertebrae and the severe form on the second and third cervical and fourth and fifth thoracic vertebrae. The examination of teeth revealed interproximal caries on the third left molar of the lower jaw. This skeleton displays more numerous perimortem traumas caused by intentional violence: six cut wounds, of which five located on the skull and one on the postcranium: 1) the largest cut wound is 110 mm long and located on the left side of the frontal bone and the left parietal bone – the superior edge is initial and polished, and the blow broke through the cranial wall. The blow was delivered in a downwards direction (Fig. 8); 2) the cut wound which broke through the cranial wall (Fig. 9) is located on the left parietal bone, 71 mm superior, lateral to the lambda and perpendicular to the first wound – the initial cut is lateral and 46 mm long, and the dimensions of the part of the bone torn off at the medial section as the weapon was being pulled out are 37x9 mm, which allows us to conclude that the blow was delivered in a downward direction, from left to right; 3) on the left parietal bone there is a cut wound with a lateral 80-mm long initial edge parallel to the previous one and located 20 mm to its side – it is slightly semi-circular in shape, it broke through the cranial wall and the direction of the blow is the same as in the previous cut wound (Fig. 9); 4) on the upper jaw, there is a cut approximately 52 mm in length, extending from the right incisor (a smaller section extending to the first premolar – 4x2 mm) to the first left molar, which are completely cut through – the blow was delivered in a downward direction, from left to right (Fig. 10); 5) the cut wound is on the left side of the lower jaw and the second molar is diagonally cut in half by the same blow which cut off part of the upper jaw; 6) on the posterior section of the left ulna, 179 mm superior to the distal end, there is a triangular polished bone surface, 11x6 mm in size – the blow was delivered in a downward direction, from right to left (Fig. 11).



Sl. 5 Grob 204 (snimila: F. Sirovica)  
Fig. 5 Grave 204 (photo: F. Sirovica)



Sl. 6 Grob 204 (nacrtala: A. Kudelić)  
Fig. 6 Grave 204 (drawing: A. Kudelić)



Sl. 7 Detalj: nož u grobu 204 (snimila: F. Sirovica)  
 Fig. 7 Detail: knife in Grave 204 (photo: F. Sirovica)

voj tjemenoj kosti 71 mm superiorno-lateralno od lambde i okomita je u odnosu na prvu – inicijalni rez je lateralan i duljine je 46 mm, a otkinuti dio kosti prilikom vađenja oružja na medijalnom dijelu je dimenzija 37×9 mm po čemu se može zaključiti da je udarac zadan odozgo lijevo prema dolje desno; 3) na lijevoj tjemenoj kosti prisutna je posjekotina s lateralnim inicijalnim rubom duljine 80 mm, paralelna je s prethodnom i smještena 20 mm lateralno od nje – blago je polukružnog oblika, probila je stijenku lubanje, a smjer udarca je isti kao i kod prethodne posjekotine (sl. 9); 4) na gornjoj čeljusti smještena je posjekotina dužine oko 52 mm koja se proteže od desnog očnjaka (malim dijelom zahvatila je i prvi pretkutnjak – 4×2 mm) do prvoga lijevog kutnjaka koji su u potpunosti presječeni – udarac je zadan odozgo lijevo prema dolje desno (sl. 10); 5) posjekotina se nalazi na lijevoj strani donje čeljusti, gdje je dijagonalno po pola presječen drugi kutnjak što je posljedica istog udarca koji je odsjekao dio gornje čeljusti; 6) na posteriornom dijelu lijeve lakatne kosti, 179 mm superiorno od distalnog kraja, prisutna je trokutasta polirana površina kosti dimenzija 11×6 mm – udarac je zadan odozgo desno prema dolje lijevo (sl. 11).

### Zaključna razmatranja

Međuljudsko se nasilje može, u nekom obliku, pronaći u svim društvima i vrlo vjerojatno u svim fazama ljudske evolucije (Keeley 1996). Podaci o ratovima ili nekim manjim sukobima često su zabilježeni u povijesnim izvorima. O njima nam svjedoče i očuvane fortifikacije te navalno i obrambeno oružje. Sukladno nekim autorima (npr. Ubelaker 1978, Hassan 1981) podaci o nasilju koji se mogu iščitati iz analiza skeletnog materijala ne daju stvarnu sliku o toj problematici. Razlozi za to su mnogobrojni. Jedan od bitnih uzroka jest to što brojne ozljede mekog tkiva, koje mogu dovesti do smrtnih posljedica, ne ostavljaju nikakve tragove na kostima. Također i česta loša očuvanost skeleta dovodi do

### Conclusions

In one form or another, interhuman violence can be found in all societies and, most probably, all phases of human evolution (Keeley 1996). Historical sources contain frequent records of wars and minor conflicts which are further corroborated by preserved fortifications and naval and defence weapons. According to some authors (e.g. Ubelaker 1978, Hassan 1981), information on intentional violence that can be derived from the analysis of skeletal material does not provide a realistic picture. There are many reasons for that, one of the main being that numerous soft tissue injuries which can be potentially lethal leave no traces on the bones. The frequently poor state of skeletal preservation can also cause difficulties in distinguishing between perimortem injuries and postmortem damage; also, persons

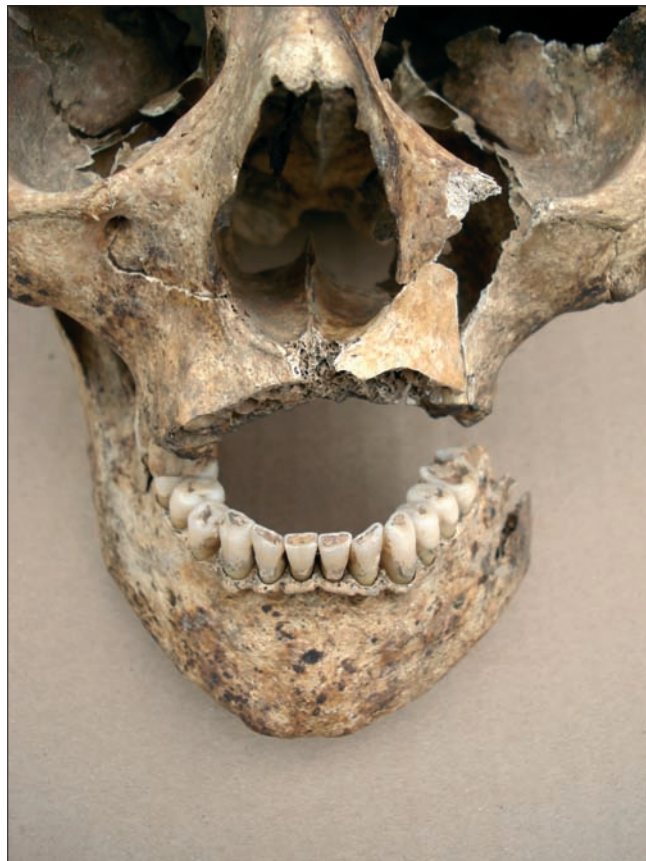

Sl. 8 Velika posjekotina koja je zahvatila čeonu i lijevu tjemenu kost osobe iz groba 204 (snimio: S. Krznar)

Fig. 8 Large cut wound on the frontal and parietal bones of the person from Grave 204 (photo: S. Krznar)



Sl. 9 Perimortalne posjekotine (broj 2 i 3) na stražnjem dijelu lijeve tjemene kosti osobe iz groba 204 (snimio: S. Krznar)  
Fig. 9 Perimortem cut wounds (nos. 2 and 3) at the back of the left parietal bone of the person from Grave 204 (photo: S. Krznar)



Sl. 10 Posjekotina koja je presjekla zube i kost gornje čeljusti osobe iz groba 204 (snimio: S. Krznar)  
Fig. 10 Cut wound, cutting off the teeth and the maxillary bone of the person from Grave 204 (photo: S. Krznar)



Sl. 11 Detalj presječne lijeve ulne iz groba 204 (snimio: S. Krznar)  
Fig. 11 Detail of the cut-off left ulna from Grave 204 (photo: S. Krznar)

težeg razlikovanja perimortalnih ozljeda od postmortalnih oštećenja, a ponekad su osobe koje su stradale nasilnim putem pokopane izvan regularnih groblja što dovodi do njihova težeg pronalaska i lošije očuvanosti (Dawson et al. 2003: 115). Na području Hrvatske, perimortalne traume koje su posljedica nasilja, zabilježene su na svega nekoliko kasnosrednjovjekovnih i ranonovovjekovnih arheoloških nalazišta. Od svega dva kostura, pronađena u romaničkoj kapeli na nalazištu Ozalj – Stari grad, jedan je pokazivao znakove perimortalnih trauma. Radi se o kosturu mlađe osobe od 11 – 12 godina, na kojem je prisutna obrambena fraktura desne lakatne kosti te velika posjekotina na desnoj tjemenoj kosti koja je najvjerojatnije posljedica udarca sjekiricom (Šlaus 1994: 172). Na kasnosrednjovjekovno-ranonovovjekovnom groblju oko crkve svetog Martina na Martin-Bregu, pronađeni su kosturi 57 odraslih osoba od kojih je šest pokazivalo prisutnost perimortalnih trauma. Sve su traume prisutne na kosturima muških osoba (Belaj 2007: 89–97). Istu spolnu pripadnost imaju i pojedinci s prisutnošću perimortalnih trauma na lokalitetu Udbina – Sv. Jakov. Od 96 analiziranih odraslih osoba s ovog lokaliteta perimortalne traume prisutne su na kosturima šestorice muškaraca. Traume su uglavnom smještene na lubanji i vratnim kralješcima te se svega kod jednog kostura nalaze i na ostatku tijela (Vyroubal 2007: 19–32). Nešto drugačiju distribuciju s obzirom na spol i lokaciju pokazuju perimortalne traume s nalazišta Crkvari i Kliškovac. Od 74 analizirana kostura odraslih osoba, traume su prisutne na njih devet. Traume lubanje prisutne su kod dvaju muškaraca i jedne žene, a one na postkranijumu kod četiriju žena i dvaju muškaraca. Na temelju takve distribucije smatra se da su te traume rezultat nasilja koje su provodile brze i lako naoružane jedinice u cilju pljačkanja i teroriziranja civilnog stanovništva, a ne posljedica sukoba dviju vojski (Šlaus, Novak 2006: 224–225). Najviše je perimortalnih trauma zabilježeno na kasnosrednjovjekovnom groblju u Čepinu gdje su čak 22 od 147 kostura imala tragove perimortalnih trauma. Zabilježene su kod 12 muškaraca, 7 žena i 3 djeteta. Brojne perimortalne traume (52 posjekotine) pronađene na skeletima žena iz Čepina te njihov čest smještaj na postkranijumu govori nam da su one posljedica mučenja koje su na toj populaciji proveli turski akindžijski odredi (Šlaus et al. 2010: 369–370). Za razliku od njih, traume na lokalitetu Ivanec – Stari grad nalaze se isključivo na skeletima muških članova populacije i smještene su uglavnom na lubanji. Samo je jedna posjekotina na postkranijumu, i to na lijevoj podlaktici, a najvjerojatnije je nastala kada je ruka bila u obrambenom položaju (instinktivna reakcija da se rukom brani glava). Time su traume iz Ivanca po distribuciji prema spolu te položaju na tijelu sličnije traumama koje se javljaju na Martin-Bregu i Udbini nego onima iz Kliškova, Crkvara ili Čepina. Međutim, brojem od 6 perimortalnih posjekotina, od kojih je pet locirano na lubanji, kostur iz groba 204 razlikuje se od svih na navedenim lokalitetima te je sličniji kosturima vojnika poginulih u bici kod Towtona 1461. godine. Od 28 lubanja pronađenih u masovnoj grobnici, na njih 27 prisutne su perimortalne traume. Ukupno je na njima zabilježeno 113 perimortalnih trauma, što čini prosjek od 4,2 traume po osobi. Na pojedinoj lubanji je prisutna

who died a violent death were sometimes buried out of bounds of regular cemeteries, which makes them difficult to find and causes their skeletons to be in poor state of preservation (Dawson et al. 2003: 115). On the territory of Croatia, perimortal traumas caused by intentional violence were recorded only at several late medieval and early Modern Age archaeological sites. Out of the only two skeletons found in the Romanesque chapel at the Ozalj – Stari Grad site, one displayed signs of perimortal trauma. It was the skeleton of a young person, 11-12 years of age, displaying a defence fracture of the right ulna and a large cut wound on the right parietal bone, most probably caused by an axe (Šlaus 1994: 172). Out of the 57 adult skeletons found in the late medieval / early Modern Age cemetery surrounding the church of St. Martin at Martin-Breg, six displayed perimortal traumas. All skeletons displaying traumas were males (Belaj 2007: 89–97). Individual skeletons displaying perimortal traumas at the Udbina - Sv. Jakov site were also males. Out of the 96 adult skeletons that were analysed from this site, perimortal traumas were displayed by six males. Traumas were mostly located on the skull and cervical vertebrae; only one skeleton displayed traumas to other parts of the body (Vyroubal 2007: 19–32). Perimortal traumas at the Crkvari and Kliškovac sites were distributed slightly differently in terms of sex and location. Out of the 74 adult skeletons that were analysed, traumas were displayed by nine. Two males and one female had suffered cranial and four females and two males postcranial trauma. Based on this pattern of distribution, it has been concluded that the traumas were not caused by two clashing armies, but by quick and lightly armed units intent on looting and terrorizing the civilian population (Šlaus, Novak 2006: 224–225). By far the highest occurrence of perimortal trauma has been recorded at the late medieval cemetery of Čepin, where as many as 22 skeletons: 12 males, 7 females and 3 children, out of 147 displayed traces of perimortal trauma. Numerous perimortal traumas (52 cut wounds) found on female skeletons from Čepin and their frequent occurrence on the postcranium tell us that they were caused by torture inflicted on this population by the Turkish Akinji detachments (Šlaus et al. 2010: 369–370). By contrast, traumas at the Ivanec – Stari Grad site were found exclusively on male skeletons, mostly on the skull. There was only one postcranial cut wound, on the left forearm, most probably inflicted when the arm assumed a defence position (instinctive reaction to defend one's head with one's arm). By their distribution in terms of sex and position on the body, the traumas from Ivanec resemble more closely those from Martin-Breg and Udbina than those from Kliškovac, Crkvari or Čepin. However, with its six perimortal cut wounds, of which five located on the skull, the skeleton from Grave 204 differs from all skeletons at the above locations, resembling rather more closely the skeletons of soldiers killed in the battle of Towton in 1461. Out of the 28 skulls found in the mass grave, perimortal traumas were displayed by 27. The total of 113 perimortal traumas registered on them constitutes an average of 4.2 traumas per person. Individual skulls displayed a minimum of one and a maximum of thirteen traumas. Cut wounds were the most frequent (65%), followed by blunt

najmanje jedna a najviše trinaest trauma. Najzastupljenije su posjekotine (65%), zatim traume nastale udarcem tvrdim predmetom (25%), a najrjeđe su ubodne traume. Kod 13 kostura zabilježene su i ukupno 43 postkranijalne traume. Ta velika razlika između trauma na lubanjama i ostatku tijela sugerira da je kod nasilja glava bila primarni cilj napada (Novak 2007: 90–103).

Niti jedna ozljeda na kosturima iz grobova 202 i 204 iz Ivanca ne pokazuje znakove zarašćivanja te ih se sa sigurnošću može dovesti u vezu s događajima koji su doveli do smrti analiziranih pojedinaca. Smještaj i izgled posjekotina sugerira da su nastale prilikom izravnog sukoba s protivnikom koji je držao oružje u desnoj ruci. Sve perimortalne ozljede nanese su oštrim, dugim sječivom poput mača ili sablje. Kako su oba pokojnika ukopana s priložima, unutar granica groblja, a grob 202 i ispod kamene ploče ukrašene uklesanim križem, te na temelju položaja perimortalnih posjekotina, možemo zaključiti da se ovdje ne radi o ukopima zločinaca koje je društvo osudilo na smrt. Vjerojatnije je da su ove smrtonosne ozljede posljedica sukoba između pojedinaca ili sudjelovanja u vojnom sukobu.

Zanimljivo je, kao što se iz rada vidi, da se iz mnoštva grobova upravo ova dva groba izdvajaju prema barem dvama kriterijima. Jedino je kod pokojnika iz ovih grobova antropološkom analizom uočeno da su bili ubijeni. I upravo su u ovim grobovima, od svih grobova mlađega srednjeg horizonta, pronađeni noževi priloženi uz pokojnika. Čini se da nam veza između uzroka njihove smrti i predmeta pronađenih u njihovim grobovima daje pravo da koristimo izraz "prilozi" kada govorimo o ovim noževima u grobovima kasnosrednjovjekovnoga razdoblja. Premda se radi o samo dva groba, spomenuta se "veza" nameće sama po sebi; puno je teže povjerovati da je riječ o pukoj slučajnosti. Teško se suzdržati od, barem, nagađanja: koja je mogla biti priroda te veze? Možda su ubijeni noževe dobili da se obrane "po putu", i to možda ne samo zato što su ubijeni, već i stoga što zbog naglog "odlaska" nisu dobili posljednju pomast pa im je kao popudbina dana zaštita druge vrste. Nagađati možemo, no sa zaključcima ipak nećemo brzati. Bolje je pričekati da nam novija arheološka iskopavanja, ali i antropološke analize, podastru komparativni materijal. U do sada poznatome gradivu analogni slučajevi nisu zabilježeni ili nam još nisu poznati.

Grob 202 dodatno se razlikuje od svih ostalih grobova otkrivenih u Ivancu po kamenoj ploči kojom je bio poklopljen – što je izuzetak na ovome lokalitetu. To, naravno, vrijedi za do sada istraženu površinu. Pogledamo li, na primjer, plan crkvenoga groblja u mjestu Klátová Nová Ves – Sádok u okrugu Topol'čany u Slovačkoj, na kojemu su označeni položaji nadgrobni kamenova, možemo vidjeti da bi, da smo na toj lokaciji, koja je slične površine, proveli istraživanja istog obujma kao naša, bio pronađen samo jedan grob. Međutim, budući da su istraživanja provedena na toj lokaciji bila ekstenzivnija, nađeno ih je 28, na puno većem prostoru uokolo crkve, od kojih šest unutar cinkture (Hanuliak 1979: 172, sl. 6). Možda, dakle, i u Ivancu, u široj okolici srednjovjekovnih crkava, leže i druge kamene nadgrobne ploče.

force traumas (25%) and penetrating traumas, which were the most infrequent. A total of 43 postcranial traumas were registered on 13 skeletons. The considerable discrepancy in the number of traumas to the skull and the rest of the body suggests that, in cases of intentional violence, the head was the primary aim of the attack (Novak 2007: 90–103).

None of the injuries suffered by the skeletons from graves 202 and 204 from Ivanec display any signs of healing and can be linked with certainty to the events which caused the death of the individuals analysed. The position and appearance of the cut wounds suggests that they were inflicted in direct combat with an adversary holding a weapon in his right hand. All perimortem injuries were inflicted by long sharp blades, such as swords or sabres. Based on the fact that both deceased were buried with goods within the perimeter of the cemetery, that Grave 202 was located underneath a stone slab decorated by an engraved cross, and the position of perimortem cut wounds, we can conclude that the persons buried were not criminals condemned to death by the society. The fatal wounds were more probably the result of a conflict between individuals or an armed conflict.

It is interesting to note that, as shown by this article, at least two criteria single out these two graves from among many others. Firstly, only in these two graves did anthropological analysis establish killing as the cause of death, and, secondly, only in these two graves, out of all graves of the late middle horizon, were knives found lying next to the deceased. The link between the cause of their death and the items found in their graves seems to allow us to use the term "grave goods" when speaking about the knives in the late medieval graves. Even though we are dealing with only two graves, this "link" simply imposes itself; coincidence is a far less credible option. It is, however, very difficult to refrain from conjecture: what could have been the nature of this link? The killed men may have been given knives to defend themselves "along the way", perhaps not only because they had been killed but also because, due to their sudden departure, they never received the last rites and were, therefore, provided with a different form of protection to help them on the way. We may engage in speculation but we will not jump to conclusions. We had better wait for new archaeological excavations and anthropological analyses to provide us with comparative material. No analogous cases have been recorded in the existing material or, at least, we are not aware of them yet.

Grave 202 differs even further from all other graves discovered in Ivanec due to the gravestone it was covered by, which is an absolute exception at this site. This, of course, applies to the area examined so far. If, for instance, we examine the plan of an area covering a similar surface, i.e. that of the church graveyard in Klátová Nová Ves – Sádok, in the Topol'čany district in Slovakia, on which the positions of gravestones are marked, we can see that, had the excavations carried out at this location been similar in scope to ours, only one grave covered with a gravestone would have been found. However, since the excavations carried out at this location were more extensive, 28 such graves were found, of which six within the precinct wall (Hanuliak 1979: 172, fig. 6). Thus, other gravestones may yet be found in the

I sam izgled ploče vrlo je zanimljiv (sl. 12). Ploča je bila izrađena od bijeloga vapnenca, izduženoga je oblika, a dimenzije su joj 177x55x23 cm. Ukrašena je jednostavnim prikazom križa: krakovi su križa prikazani s po dvije paralelno uklesane linije koje kontinuirano teku tako da se u središtu sijeku i čine kvadrat. Prikaz je to toliko jednostavan da bismo ga češće očekivali na srednjovjekovnim nadgrobnicama<sup>3</sup>. Jedino je uz gornju stranicu ploče urezana tanka linija, poput bordure, dok je iznad nje dublje uklesan niz visećih trokuta<sup>4</sup>.

Pri datiranju ovog spomenika u obzir treba uzeti njegovu vrlo skromnu ukrašnost, kako po pitanju izvedbe, tako

areas surrounding the medieval churches in Ivanec.

The appearance of the gravestone is in itself very interesting (Fig. 12): it is made of white limestone, elongated, and its dimensions are 177x55x23 cm. It is decorated by a simple representation of a cross, each arm of the cross represented by two parallel engraved lines forming a rectangle at the point of their intersection. The representation is so simple that one might expect it to occur on medieval gravestones more frequently.<sup>3</sup> Just a thin line, resembling a border, is engraved along the upper edge of the stone; above it, a string of suspended triangles is engraved more deeply.<sup>4</sup>

When dating this monument, one must take into consi-



Sl. 12 Nadgrobna ploča postavljena na grob 202 (snimila: F. Sirovica)  
Fig. 12 Gravestone covering Grave 202 (photo: F. Sirovica)

3 Najsljedniji nama poznati križ uklesan na nekom nadgrobnom spomeniku nalazi se na tzv. križnome kamenu (*Kreuzstein*) koji se nalazi uz rub ceste "Kiselo polje" (*Saures Feld*) kraj sela Oberschedena nedaleko od Göttingena u Donjoj Saskoj (<http://www.m-beuermann.de/kreuzsteine.htm>, 30. 12. 2008.; <http://www.suehnekreuz.de/nieder/scheden.htm>, 30. 12. 2008.; Riebeling 1977, Nr.4524.12; Müller, Baumann 1988, Nr. 4524.12). Naziva se tako prema križu koji je plitko uklesan u pravokutni kameni blok. Drugi naziv za tu vrstu spomenika je "smrtni kamen" ili "kamen od ubojstva" (*Mordsteine*). Točna funkcija tih spomenika ne može se odrediti sa stopostotnom sigurnošću jer su uglavnom bili postavljeni od 13. do 16. stoljeća, no poopćeno se vjeruje da su "križni kamenovi" bili znak pokore, podignuti za dobro duše ljudi koji su umrli iznenadnom i nasilnom smrću, kao obrana od krvne osvete te kao podsjetnik na taj čin ili događaj, a podizali bi ih sami ubojice na mjestu zločina. Iako se, eto, i ovdje javlja "ubojstvo kao motiv" i premda je spomenuti križ vrlo sličan našem križu, ne želimo reći da je grob 202 doista poklopljen jednim takvim "smrtnim kamenom" u sekundarnoj uporabi. Štoviše, čak bi bilo vjerojatnije da su pojedini donjosaški primjerci "križnih kamenova" – oni koji oblikom podsjećaju na nadgrobne ploče – u primarnoj uporabi to i bili. Na ovome smo mjestu samo željeli svratiti pozornost na tu vrstu kamenih spomenika prisutnih u zemljama pod njemačkim utjecajem u kasnome srednjemu i na početku novoga vijeka

4 Sličan motiv poznat nam je zasada jedino s grbova zagrebačkog biskupa Eberharda (biskupovao u dva navrata: 1397. – 1406. te 1410. – 1419.) sa zagrebačke katedrale. Na njima se okrunjeni lav uzdignut na stražnje noge nalazi u štiti koji je sa svih strana obrubljen trokutima (Horvat 2005). Usprkos sličnosti motiva, teško je primijetiti ikakvu dublju vezu između ovih spomenika.

3 There is one similar cross known to us that has been engraved on a gravestone: the one found on the so-called "cross-stone" (*Kreuzstein*) located at the side of the "Sour Field" (*Saures Field*) road near the village of Oberscheden, not far from Göttingen in Lower Saxony (<http://www.m-beuermann.de/kreuzsteine.htm>, 30 December 2008; <http://www.suehnekreuz.de/nieder/scheden.htm>, 30 December 2008; Riebeling 1977, no. 4524.12; Müller, Baumann 1988, no. 4524.12). It was named after a cross shallowly engraved in a rectangular stone block. The alternative name for this type of monument is "death stone" or "murder stone" (*Mordsteine*). The exact purpose of these monuments cannot be determined with absolute accuracy because they were mostly erected between the 13th and 16th centuries, but it is generally believed that "cross-stones" were a sign of penitence, erected for the benefit of the souls of those who died a sudden and violent death, as protection from blood feud and as a reminder of that particular act or event. They were usually erected by the killers themselves at the site of the crime. Even though we are here also dealing with "murder as motive" and in spite of the mentioned cross being very similar to our cross, we are not trying to say that grave 202 was covered by one such "death stone" in its secondary purpose. It is even more likely that the primary role of some Lower-Saxony "cross-stones" – the ones whose shape is reminiscent of gravestones – was, indeed, that of gravestones. We merely wanted to draw your attention to this type of stone monuments that can be found in countries which, in Late Middle Ages and Early Modern Age, were under Germanic influence.

4 The only similar motif known to us so far can be found on the coats of arms of Bishop Eberhard of Zagreb (served as bishop twice: 1397-1406 and 1410-1419) in Zagreb Cathedral: a crowned lion rampant inside a shield, bordered by triangles on all sides (Horvat 2005). In spite of the similarity of motifs, it is, however, difficult to establish a deep connection between the two monuments.

i motiva. Ne samo da na ploči nije prikazan ljudski lik ili grb – pa makar samo štit<sup>5</sup> – koji se postupno javljaju već od 13. stoljeća (Demo 2007: 52; Horvat 1988), već nije uklesan ni ikakav natpis. Nešto što također od 13. stoljeća – ili, barem u Mađarskoj, čak od kraja 12. stoljeća<sup>6</sup> – postaje sve teže zamislivo, bilo je sredinom 11. stoljeća sasvim uobičajeno čak i na tako posebnoj nadgrobnoj ploči kakva je ona kralja Andrije I. (1046. –1060.). Na toj nadgrobnoj ploči, položenoj nad njegovim grobom u kriпти benediktinske opatije u Tihany na Balatonu, naime, nema nikakvoga natpisa, već je ukrašena samo križem, premda vrlo lijepo izvedenim, u reljefu, na dugačkome tordiranom štapu. Sličan našem, no ipak nešto razvijeniji koncept, prisutan je kod nadgrobne ploče pronađene sekundarno uporabljene u crkvi sv. Martina na Prozorju (Belaj 2007: 98–99, sl. 38). Iako se i na toj ploči, datiranoj na prijelaz iz 13. u 14. stoljeće, ne javljaju navedeni detalji, ipak je uz mač, koji je zamijenio križ, uklesan i štit (premda to još nije grb), a uz rubove ploče teče bordura (no još uvijek bez natpisa).

Iz svega navedenoga može se zaključiti da je pokojnik u grob 202 sahranjen te poklopljen ovom nadgrobnom pločom najvjerojatnije u drugoj polovici 13. stoljeća, malo nakon što je sagrađena gotička crkva sv. Ivana Krstitelja.

Prema pisanju Ágnes Ritoók, pozicija ove ploče u to vrijeme na groblju izvan crkve u skladu je s odredbama kanonskoga prava koje su u razdoblju od 11. do 13. stoljeća samo rijetkima dopuštale pokop unutar crkve (Ritoók 1997)<sup>7</sup>. Na grobljima iz 10. st. takvih ploča nema ni u Slovačkoj, Češkoj i Ukrajini (Hanuliak 1979). Ranije nadgrobne ploče, osobito one nastale tijekom 11. stoljeća, bile su znatno lošije obrađene (v. Ritoók 1997: 207, sl. 2). Od druge ih se polovice 14. st. pak prestalo polagati na grobove oko crkava, no zato je učestalo njihovo polaganje unutar crkava i kapela (Ritoók 1997). Sve ih se rjeđe nalazi na grobovima izvan crkava, vjerojatno i zato što su si ih mogli priuštiti jedino bogatiji pojedinci, a oni su bili pokapani unutar crkava (Demo 2007: 52). Možda su poneke s vremenom odnesene kao građevinski materijal ili ih je zatrpala zemlja. Bilo kako bilo, gotovo su potpuno nepoznate u stručnoj literaturi gdje se mahom spominju samo bogatije ukrašene nadgrobne ploče, i to uglavnom iz kasnijih stoljeća (usp., primjerice, Brunšmid 1912 i Valentić, Prister 2002).

deration its decorations which, both in terms of execution and motifs, are extremely modest. Not only does the stone not display a human form or a coat-of-arms, or at least a shield<sup>5</sup> – which had gradually started appearing from the 13<sup>th</sup> century onwards (Demo 2007: 52; Horvat 1988), but there is no engraved inscription either. What was becoming increasingly difficult to imagine by the end of the 13<sup>th</sup> century or, in Hungary at least, already at the end of the 12<sup>th</sup> century<sup>6</sup>, was perfectly ordinary practice in mid-11<sup>th</sup> century, even on special headstones, such as that of King Andrew I (1046 – 1060). The headstone, placed over his grave in the crypt of the Benedictine Abbey in Tihany on Lake Balaton, bears no inscription but is decorated with a single cross, very finely executed, in relief, on a long, spiral-shaped staff. A concept similar to ours, albeit more developed, can be found on the gravestone that was found, in its secondary use, in the church of Sv. Martin in Prozorje (Belaj 2007: 98–99, Fig. 38). Even though this gravestone, dated at the turn of the 13<sup>th</sup> and 14<sup>th</sup> centuries, does not display the above details either, a sword, which had replaced the cross, is, however, accompanied by an engraved shield (although not yet a coat of arms) and a border running along the edges of the stone (although not yet with an inscription).

According to the above, it can be concluded that Grave 202 was used for a burial, and covered by this gravestone, in, most probably, the second half of the 13<sup>th</sup> century, shortly after the Gothic church of St. John the Baptist was constructed.

According to Ágnes Ritoók, the position of this stone in the graveyard outside the church conformed at the time with the provisions of the Canon Law which, in the period between the 11<sup>th</sup> and 13<sup>th</sup> centuries, only rarely allowed people to be buried inside the church (Ritoók 1997).<sup>7</sup> Such gravestones cannot be found on 10<sup>th</sup>-century graves in Slovakia, the Czech Republic or Ukraine (Hanuliak 1979) either. The dressing of older gravestones, in particular those from the 11<sup>th</sup> century, was of much poorer quality (see Ritoók 1997: 207, fig. 2). From the second half of the 14<sup>th</sup> century onwards, however, they were no longer laid on the graves around the churches, but with increasing frequency, inside churches and chapels (Ritoók 1997). They became less frequent on graves outside of churches, probably also because they could only be afforded by more affluent individuals who were buried inside the churches (Demo 2007: 52). Some may have been removed with time as construction material or covered by ground. Be that as it may, they are practically unheard-of in professional literature which predominantly speaks of more luxuriously decorated gravestones, mostly from later centuries (e.g. compare with Brunšmid 1912 and Valentić, Prister 2002).

5 U Hrvatskoj se tijekom 13. st. grbovi sastoje samo od štita, dok se od 14. st. uz njih javljaju i potpuni grbovi koji osim štita sadrže i kacigu, nakit kacige te plašt (Horvat 1988: 41).

6 Ploče trapezoidnih presjeka s natpisima u katedrali u Esztergomu čine vjerojatnim da je taj oblik bio u modi koncem 12. i početkom 13. stoljeća (Ritoók 1997).

7 Doista, i u svetištu ivanečke romaničke crkve bile su ukopane samo tri osobe, u vrlo urednom rasporedu; tamo nije bilo naknadnih ukopa, presijecanja starijih grobova i općenito "gužve" kakva je primijećena u svetištu gotičke crkve (Belaj, Sirovica 2010).

5 Coats of arms in 13th-century Croatia contained only shields; in the 14th century full coats of arms appeared alongside them, containing, in addition to the shield, a helmet, helmet decorations and mantling (Horvat 1988: 41).

6 Plaques of trapezoidal section with inscriptions from the Esztergom Cathedral indicate that this form was probably in fashion in the late 12th and early 13th centuries (Ritoók 1997).

7 Indeed, only three persons were buried, very neatly, in the sanctuary of the Ivanec Romanesque church; there were no subsequent burials or bisections of older graves; in general, it was not as "crowded" as the sanctuary of the Gothic church (Belaj, Sirovica 2010).



## LITERATURA / BIBLIOGRAPHY

- Aufderheide, A.C., Rodriguez-Martin, C. 1998, *The Cambridge encyclopedia of human paleopathology*, Cambridge University Press.
- Alvrus, A. 1999, Fracture Patterns Among the Nubians of Semna South, Sudanese Nubia, *International Journal of Osteoarchaeology*, 9, 417–429.
- Bass, W.M. 1995, *Human Osteology. A Laboratory and Field Manual of the Human Skeleton* (četvrto izdanje), Columbia, MO, Missouri Archaeological Society.
- Belaj, J. 2007, *Templari i ivanovci na zemlji svetog Martina*, Pučko otvoreno učilište Dugo Selo, Dugo Selo.
- Belaj, J. 2008, *Ivanec kroz slojeve prošlosti. Deset godina arheoloških istraživanja u Ivancu*, Grad Ivanec & Mini-print-logo, Ivanec.
- Belaj, J. 2009, Arheološka istraživanja crkve Sv. Ivana Krstitelja u Ivancu 2008. g., *Annales Instituti Archeologici*, V, 90–94.
- Belaj, J., Sirovica, F. 2010, Arheološka istraživanja na lokalitetu *Stari grad* u Ivancu godine 2009., *Annales Instituti Archeologici*, VI, 59–63.
- Brooks, S., Suchey, J.M. 1990, Skeletal age determination based on the os pubis: A comparison of the Acsjdi-Nemeskéri and Suchey-Brooks methods. *Human Evolution*, 5, 227–238.
- Brunšmid, J. 1912, Kameni spomenici Hrvatskog narodnog muzeja u Zagrebu. Dio II. Spomenici srednjega i novoga vijeka. *Vjesnik Hrvatskoga arheološkoga društva, nova serija*, XII, Zagreb.
- Dawson, L., Levy, T.E., Smith, P. 2003, Evidence of Interpersonal Violence at the Chalcolithic Village of Shiqmim (Israel), *International Journal of Osteoarchaeology*, 13, 115–119.
- Demo, Ž. 2007, *Opatovina. Tragovi povijesti izgubljeni u sadašnjosti*, Arheološki muzej u Zagrebu, Zagreb.
- Fazekas, I.G., Kósa, F. 1978, *Forensic Fetal Osteology*, Budapest, Akadémiai Kiadó.
- Gilbert, B.M., McKern, T.W. 1973, A method for aging the female os pubis, *American Journal of Physical Anthropology*, 38, 31–38.
- Goodman, A.H., Rose, J.C. 1991, Dental enamel hypoplasias as indicators of nutritional status, in: *Advances in dental anthropology*, Kelley, M., Larsen, C.S. (eds.), New York, 279–294.
- Hanuliak, M. 1979, Hroby pod náhrobnými kameňmi v 11. – 14. storočí, *Slovenská archeológia*, XXVII/1, 167–186.
- Hassan, F.A. 1981, *Demographic Archaeology*, Academic Press, New York.
- Horvat, Z. 1998, O nekim osobinama gotičkih nadgrobnih ploča s grbovima u kontinentalnom dijelu SR Hrvatske, u: *Bulletin Razreda za likovne umjetnosti Jugoslavenske akademije znanosti i umjetnosti*, br. 1(59), 41–68.
- Horvat, Z. 2005, Grbovi biskupa Eberharda (1397–1406; 1410–1419) na zagrebačkoj katedrali. *Naša katedrala*, 9, 9–13.
- Hough, A.J., Sokoloff, L. 1989, Pathology of Osteoarthritis, in: *Arthritis and Allied Conditions: A textbook of Rheumatology*, Mc Carthy, D.J. (ed.), Philadelphia, 1571–1591.
- Iscan, M.Y., Loth, S.R., Wright, R.K. 1984, Age estimation from the rib by phase analysis: White males, *Journal of Forensic Sciences*, 29, 1094–1104.
- Iscan, M.Y., Loth, S.R., Wright, R.K. 1985, Age estimation from the rib by phase analysis: White females, *Journal of Forensic Sciences*, 30, 853–863.
- Keeley, L.H. 1996, *War Before Civilization – the Myth of the Peaceful Savage*, Oxford.
- Kilgore, L., Jurmain, R.D., Van Gerven, D.P. 1997, Palaeoepidemiological Patterns of trauma in a Medieval Nubian Skeletal Population, *International Journal of Osteoarchaeology*, 7, 103–114.
- Krogman, W.M., Iscan, M.Y. 1986, *The Human Skeleton in Forensic Medicine*, 2nd ed. Springfield, IL: C.C. Thomas.
- Lovejoy, C.O. 1985, Dental wear in the Libben population: Its functional pattern and role in the determination of adult skeletal age at death, *American Journal of Physical Anthropology*, 68, 47–56.
- Lovejoy, C.O., Meindl, R.S., Pryzbeck, T.R., Mensforth, R.P. 1985, Chronological metamorphosis of the auricular surface of the ilium: A new method for the determination of age at death, *American Journal of Physical Anthropology*, 68, 15–28.
- Mann, R.W., Murphy, S.P. 1990, *Regional Atlas of Bone Disease: A Guide to Pathologic and Normal Variation in the Human Skeleton*, Springfield: C. C. Thomas.
- Meindl, R.S., Lovejoy, C.O. 1985, Ectocranial suture closure: A revised method of the determination of skeletal age at death based on the lateral-anterior sutures, *American Journal of Physical Anthropology*, 68, 57–66.
- McKern, T.W., Stewart, T.D. 1957, Skeletal age changes in young American males. Analyzed from the standpoint of age identification. Environmental protection research division (Quarter-master research and development center, U.S. Army, Natick, Massachusetts), Technical report EP-45
- Moorrees, C.F.A., Fanning, E.A., Hunt, E.E. 1963, Age variation of formation stages for ten permanent teeth, *Journal of Dental Research*, 42, 1490–1502.
- Müller, W., Baumann, G. E. 1988, Kreuzsteine und Steinkreuze in Niedersachsen, Bremen und Hamburg. *Forschungen der Denkmalpflege in Niedersachsen*, 5, Hannover.
- Novak, M., Krznar, S., Pasarić, M. 2005, Antropološka analiza ljudskog osteološkog materijala s nalazišta Ivanec – Stari grad, *Ivanečka škrinjica*, 1, 27–38.
- Novak, S. 2007, Battle-related trauma, in: *Blood Red Roses: The Archaeology of a Mass Grave from the Battle of Towton AD 1461*, Fiorato, V., Boylston, A., Knüsel, Ch. (eds.), Oxford, 90–103.
- Ortner, D.J., Putschar, W.G. 1985, *Identification of pathological conditions in human skeletal remains*, Smithsonian Institution Press, Washington DC.
- Ortner, D.J. 2003, *Identification of Pathological Conditions in Human Skeletal Remains*, New York, Academic Press.
- Pfeiffer, S. 1991, Estimation of age at death, in: *An investigation of a military cemetery from the war of 1812*, Pfeiffer, S., Williamson, S.R. (eds.), Toronto.
- Phenice, T.W. 1969, A newly developed visual method of sexing the os pubis, *American Journal of Physical Anthropology*, 30, 297–301.
- Pindborg, J.J. 1970, *Pathology of the dental hard tissues*, Philadelphia.
- Riebeling, H. 1977, *Steinkreuze und Kreuzsteine in Hessen: ein topographisches Handbuch zur rechtlichen Volkskunde*, Dossenheim.
- Ritoók, Á. 1997, Templom körüli temetők Árpád-kori sírjelei Magyarországon, *Communications Archaeologicae Hungariae*, Budapest, 205–213.
- Scheuer L., Black S. 2000, *Developmental Juvenile Osteology*, San Diego, San Francisco, New York, Boston, London, Sydney, Tokio, Academic Press.
- Schmorl G., Junghanns H. 1971, *The Human Spine in Health and Disease*, (drugo izdanje), New York, Grune and Stratton.
- Standen V.G., Ariaazza B.T. 2000, Trauma in the Preceramic Coastal Populations of Northern Chile: Violence or Occupational Hazards?, *American Journal of Physical Anthropology*, 112, 239–249.
- Steinbock, R.T. 1976, *Paleopathological Diagnosis and Interpretation: Bone Diseases in Ancient Human Populations*, Springfield, IL, C.C. Thomas.
- Šlaus, M. 1994, Osteological Evidence for Peri-Mortem Trauma and Occupational Stress in Two Medieval Skeletons from Croatia, *Collegium Antropologicum*, Vol. 18/1, 165–175.
- Šlaus, M. 2006, *Bioarheologija. Demografija, zdravlje, traume i prehrana starohrvatskih populacija*, Zagreb.
- Šlaus, M., Novak, M. 2006, Analiza trauma u srednjovjekovnim uzorcima iz Kliškovca i Crkvara / An analysis of traumas in medieval samples from Kliškovac and Crkvara, *Prilozi Instituta za arheologiju u Zagrebu*, Vol.23, 213–228.
- Šlaus, M., Novak, M., Vyroubal, V., Bedić, Ž. 2010, The Harsh Life on the 15th Century Croatia – Ottoman Empire Military Border: Analyzing and Identifying the Reasons for the Massacre in Čepin, *American Journal of Physical Anthropology*, 141, 358–372.
- Trotter, M., Gleser, G.C. 1952, Estimation of stature from long bones of American whites and Negroes, *American Journal of Physical Anthropology*, 10, 463–514.
- Ubelaker, D. 1978, *Human Skeletal Remains: Excavation, Analysis, Interpretation*. Smithsonian Institution Press: Washington.
- Ubelaker, D., Adams, B. 1994, Differentiation of perimortem and post-mortem trauma using taphonomic indicators, *Journal of Forensic Sciences*, 40, 509–512.
- Valentić, M., Prister, L. 2002, *Zbirka kamenih spomenika* (II., dopunjeno izdanje), Zagreb.
- Vyroubal, V. 2007, Forenzično antropološka analiza perimortalnih trauma na kasnosrednjovjekovnom nalazištu Udbina – Sveti Jakov, neobjavljeni diplomski rad
- Walker, P. L. 1989, Cranial injuries as evidence of violence in prehistoric southern California, *American Journal of Physical Anthropology*, 80, 313–323.
- Walker, P.L. 1997, Wife beating, boxing and broken noses: Skeletal evidence for the cultural patterning of violence, in: *Troubled times: Violence and Warfare in the Past (War and Society)*, Martin D., Frayer D. (eds.), Amsterdam, Gordon and Breach, 145–180.
- Wenham, S. 1989, Anatomical interpretations of Anglo-Saxon weapon injuries, in: *Weapons and Warfare in Anglo-Saxon England, Monograph 21*, Hawkes S. (ed.), Oxford, Oxford University Committee for Archaeology, 123–139.
- <http://www.m-beuermann.de/kreuzsteine.htm> (30. 12. 2008.).
- <http://www.suehnekreuz.de/> (30. 12. 2008.).