

Kasnosrednjovjekovna i ranonovovjekovna populacija iz Ivankova, istočna Hrvatska: rezultati (bio)arheološke analize

Krznar, Siniša; Hajdu, Tamás

Source / Izvornik: **Prilozi Instituta za arheologiju u Zagrebu, 2020, 37, 165 - 194**

Journal article, Published version

Rad u časopisu, Objavljena verzija rada (izdavačev PDF)

<https://doi.org/10.33254/piaz.37.6>

Permanent link / Trajna poveznica: <https://um.nsk.hr/um:nbn:hr:291:720411>

Rights / Prava: [Attribution 3.0 Unported](#)/[Imenovanje 3.0](#)

Download date / Datum preuzimanja: **2025-03-04**



INSTITUT ZA
ARHEOLOGIJU

Repository / Repozitorij:

[RIARH - Repository of the Institute of archaeology](#)



UDK 902
ISSN 1330-0644
VOL 37/2020.
ZAGREB, 2020.

Prilozi

Instituta za arheologiju u Zagrebu

Pril. Inst. arheol. Zagrebu, 37/2020
Str./Pages 1–234, Zagreb, 2020.

Izdavač/*Publisher*
INSTITUT ZA ARHEOLOGIJU
INSTITUTE OF ARCHAEOLOGY

Adresa uredništva/*Address of the editor's office*
Institut za arheologiju/*Institute of archaeology*
HR–10000 Zagreb, Ulica Ljudevita Gaja 32
Hrvatska/*Croatia*
Telefon/Phone ++385/(0)1 61 50 250
Fax ++385(0)1 60 55 806
e-mail: urednistvo.prilozi@iarh.hr
<http://www.iarh.hr>

Glavni i odgovorni urednik/*Editor in chief*
Marko DIZDAR

Tehnički urednici/*Technical editors*
Marko DIZDAR
Katarina BOTIĆ

Uredništvo/*Editorial board*
Marko DIZDAR, Snježana VRDOLJAK, Viktória KISS (Budapest, HUN) (prapovijest/*Prehistory*), Goranka LIPOVAC VRKLJAN, Ivan RADMAN-LIVAJA (antika/*Antiquities*), Tajana SEKELJ IVANČAN, Katarina Katja PREDOVNIK (Ljubljana, SLO), Natascha MEHLER (Wien, AUT), Juraj BELAJ, Tatjana TKALČEC (srednji vijek i novi vijek/*Middle Ages and Modern era*), Predrag NOVAKOVIĆ (Ljubljana, SLO) (metodologija/*Methodology*)

Izdavački savjet/*Editorial advisory board*
Dunja GLOGOVIĆ (Zagreb), Ivor KARAVANIĆ (Zagreb), Laszlo KÓVACS (Budapest, HUN), Kornelija MINICHREITER (Zagreb), Aleksandar RUTTKAY (Nitra, SK), Ivančica SCHRUNK (Minneapolis, USA), Željko TOMIČIĆ (Zagreb), Ante UGLEŠIĆ (Zadar)

Prijevod na engleski/*English translation*
Domagoj BUŽANIĆ, Kristina DESKAR, Dario HRUŠEVAR, Ana KONESTRA, Tamara LEVAK POTREBICA, Marko MARAS, Rory MACLEOD, Šime VRKIĆ, Mirna VUKOV

Lektura/*Language editor*
Ivana MAJER, Marko DIZDAR (hrvatski jezik/*Croatian*)
Marko MARAS (engleski jezik/*English*)

Korektura/*Proofreads*
Katarina BOTIĆ

Grafičko oblikovanje/*Graphic design*
Roko BOLANČA

Računalni slog/*Layout*
Hrvoje JAMBREK

Tisak/*Printed by*
Tiskara Zelina d.d., Sv. I. Zelina

Naklada/*Issued*
400 primjeraka/400 copies

Prilozi Instituta za arheologiju u Zagrebu uključeni su u sljedeće indekse/
Prilozi Instituta za arheologiju u Zagrebu are included in following indices:
DYABOLA – Sachkatalog der Bibliothek – Römisch-Germanische Kommission des Deutschen Archaeologischen Instituts, Frankfurt a. Main
Clarivate Analytics services – Web of Science Core Collection
CNRS/INIST – Centre National de la Recherche Scientifique/L'Institut de l'Information Scientifique et Technique, Vandoeuvre-lès-Nancy
EBSCO – Information services, Ipswich
ERIH – European Reference Index for the Humanities, European Science Foundation, Strasbourg
SciVerse Scopus – Elsevier, Amsterdam

E-izdanja. Publikacija je dostupna u digitalnom obliku i otvorenom pristupu na
<https://hrcak.srce.hr/prilozi-iaz>
E-edition. The publication is available in digital and open access form at
<https://hrcak.srce.hr/prilozi-iaz?lang=en>

Ovaj rad licenciran je pod Creative Commons Attribution By 4.0 međunarodnom licencom /
This work is licenced under a Creative Commons Attribution By 4.0 International Licence



Sadržaj

Contents

Izvorni znanstveni radovi

Original scientific papers

- 5 DOMAGOJ PERKIĆ
MARIO NOVAK
Tragovi prapovijesnih pokapanja ljudi u špiljama dubrovačkoga područja
- 37 ŠIME VRKIĆ
NEDA KULENOVIĆ OČELIĆ
Prilog poznavanju prapovijesnih gradina na donjem toku rijeke Zrmanje
- 73 ANA KONESTRA
GORANKA LIPOVAC VRKLJAN
BARTUL ŠILJEG
The assortment of ceramic building materials from the pottery workshop of *Sextus Me(u)tillius Maximus* at Crikvenica (Croatia)
- 99 MIRJANA SANADER
MIRNA VUKOV
DOMAGOJ BUŽANIĆ
Promjena perspektive o ranim rimskim migracijama na Sredozemlju. Slučaj istočnoga Jadrana
- 117 DARIO HRUŠEVAR
KORALJKA BAKRAČ
SLOBODAN MIKO
NIKOLINA ILIJANIĆ
OZREN HASAN
MIRNA MAMIĆ
TATJANA PULJAK
ANITA VUC IĆ
KATARINA HUSNJAK MALOVEC
MARTINA WEBER
BOŽENA MITIĆ
Environmental history in Central Croatia for the last two millennia – vegetation, fire and hydrological changes under climate and human impact
- DOMAGOJ PERKIĆ
MARIO NOVAK
Traces of prehistoric human burials in the caves of the Dubrovnik area
- ŠIME VRKIĆ
NEDA KULENOVIĆ OČELIĆ
A contribution to the study of the prehistoric hillforts in the lower course of the River Zrmanja
- ANA KONESTRA
GORANKA LIPOVAC VRKLJAN
BARTUL ŠILJEG
Asortiman građevinske keramike iz keramičarske radionice Sexta Me(u)tillia Maxima u Crikvenici (Hrvatska)
- MIRJANA SANADER
MIRNA VUKOV
DOMAGOJ BUŽANIĆ
A change of perspective on early Roman migrations in the Mediterranean. The case of the eastern Adriatic
- DARIO HRUŠEVAR
KORALJKA BAKRAČ
SLOBODAN MIKO
NIKOLINA ILIJANIĆ
OZREN HASAN
MIRNA MAMIĆ
TATJANA PULJAK
ANITA VUC IĆ
KATARINA HUSNJAK MALOVEC
MARTINA WEBER
BOŽENA MITIĆ
Dvije tisuće godina okolišnih promjena na području središnje Hrvatske – vegetacija, požari i hidrologija utjecani klimatskim prilikama i ljudskim pritiskom

165 SINIŠA KRZNAR
TAMÁS HAJDU
Kasnosrednjovjekovna i ranonovovjekovna
populacija iz Ivankova, istočna Hrvatska: rezultati
(bio)arheološke analize

SINIŠA KRZNAR
TAMÁS HAJDU
*Late medieval/early modern population from
Ivankovo, eastern Croatia: the results of the
(bio)archaeological analysis*

Prethodno priopćenje

Preliminary report

195 RENATA ŠOŠTARIĆ
HRVOJE POTREBICA
RENATA BONIĆ BABIĆ
MARIJA MARTINOVIĆ
TAMARA NOVAK
Grobnice halštatskih kneževa na lokalitetu Kaptol –
Čemernica: Arheobotanički nalazi iz tumula III i XI

RENATA ŠOŠTARIĆ
HRVOJE POTREBICA
RENATA BONIĆ BABIĆ
MARIJA MARTINOVIĆ
TAMARA NOVAK
*Graves of Hallstatt Princes at Kaptol – Čemernica:
Archaeobotanical Material from Tumuli III and XI*

211 IVANA OŽANIĆ ROGULJIĆ
JERE DRPIĆ
Clavi coctiles iz Cibala (Vinkovci)

IVANA OŽANIĆ ROGULJIĆ
JERE DRPIĆ
Clavi coctiles from Cibalae (Vinkovci)

227 UPUTE AUTORIMA

GUIDELINES FOR CONTRIBUTORS

Kasnosrednjovjekovna i ranonovovjekovna populacija iz Ivankova, istočna Hrvatska: rezultati (bio)arheološke analize

Late medieval/early modern population from Ivankovo, eastern Croatia: the results of the (bio)archaeological analysis

Izvorni znanstveni rad
Srednjovjekovna arheologija

Original scientific paper
Medieval archaeology

UDK/UDC 904:572[(497.5 Ivankovo)“12/17”

Primljeno/Received: 21. 01. 2020.
Prihvaćeno/Accepted: 18. 06. 2020.

SINIŠA KRZMAR
Institut za arheologiju
Ulica Ljudevita Gaja 32
HR-10000 Zagreb
sinisa.krznar@iarh.hr

TAMÁS HAJDU
Odsjek za biološku antropologiju
Sveučilište Eötvös Loránd
Pázmány Péter sétány 1/c
H-1117 Budimpešta
hajdut@caesar.elte.hu

U radu su predstavljene rezultati zaštitnih arheoloških iskopavanja provedenih uz crkvu Rođenja sv. Ivana Krstitelja u Ivankovu pored Vinkovca prilikom čega je istraženo 55 grobova. Riječ je o rimokatoličkome župnom groblju koje se, na osnovi stratigrafskih odnosa i pronađenih nalaza materijalne kulture, može datirati od kraja 13. sve do 18. stoljeća, tj. u kasni srednji i rani novi vijek. Arheološki nalazi su u skladu s vremenskim periodom skromni i uglavnom se radi o dijelovima nošnje te nakitu (prstenje, pojas, pojasna kopča, kopčice s kukom i ušicom, igle, nož). Pored arheoloških nalaza, funkcioniranje župe, a samim time i groblja, u vrijeme osmanlijske vladavine Ivankovom potvrđuju i povijesni izvori. Pokojnici su položeni u jednostavne zemljane rake i uglavnom orijentirani zapad – istok. Većina grobova oštećena je naknadnim ukopima tako da su i sami kosturi relativno loše (parcijalno) sačuvani. Detaljnu bioarheološku analizu koštanih ostataka iz Ivankova bilo je moguće provesti na 53 osobe (10 djece, 13 žena i 30 muškaraca). Analiza dento-alveolarnih oboljenja pokazuje visoke učestalosti karijesa i zaživotnoga gubitka zuba, što ukazuje na loše oralno zdravlje, ali i prehranu temeljenu na ugljikohidratima, tj. žitaricama. Visoke stope učestalosti pokazatelja fiziološkoga stresa (cribra orbitalia i linearna hipoplazija zubne cakline) kao i periostitisa te prisutnost zaraznih bolesti, kao što je tuberkuloza, svjedoči o generalno lošem zdravstvenom stanju za većinu stanovništva ovoga mjesta. Distribucija i morfologija koštanih ozljeda u uzorku iz Ivankova ukazuju da su nastale kao posljedica nesretnih slučajeva, najvjerojatnije povezanih sa svakodnevnim aktivnostima unutar zajednice kao što su rad u polju ili sa stokom te rad u kući.

Ključne riječi: Slavonija, rimokatoličko župno groblje, materijalna kultura, koštani ostaci, paleopatologija

This paper presents the results of rescue archaeological excavations conducted around the church of the Birth of St. John the Baptist in Ivankovo near Vinkovci during which 55 graves were excavated. Based on the stratigraphic relationships between the graves and archaeological finds of material culture, this Roman Catholic parish cemetery can be dated to the period from the end of the 13th to the 18th century, i.e. to the late Middle Ages and the early modern period. The archaeological finds are scarce and usually include parts of costumes and jewelry (rings, belts, belt buckles, hook-and-eye fasteners, pins, knives), which is common for this period. Aside from the archaeological finds, historical sources also attest to the existence of the parish and the cemetery during the Ottoman rule. The deceased were laid in grave pits, which were usually oriented in the west-east direction. Most graves were damaged by later burials and the skeletons themselves are also relatively poorly (partially) preserved. A detailed bioarchaeological analysis of skeletal remains from Ivankovo could be conducted on 53 people (10 children, 13 women, and 30 men). Dentoalveolar disease analysis showed a high frequency of caries and ante mortem tooth loss, which suggest poor oral health, but also a diet based on carbohydrates, i.e. grains. High rate of physiological stress indicators (cribra orbitalia and linear enamel hypoplasia), periostitis, and the presence of infectious diseases such as tuberculosis indicate that most residents were in poor health condition. The distribution and morphology of skeletal injuries from Ivankovo assemblage suggest that they were caused by accidents that probably occurred during everyday activities within the community, such as working in the field, with cattle, or in the house.

Keywords: Slavonia, Roman Catholic parish cemetery, material culture, skeletal remains, paleopathology

UVOD

Selo Ivankovo smješteno je u ravnici zapadno od Vinkovaca. Zahvaljujući svome povoljnom zemljopisnom položaju kao i topografskim, klimatskim i hidrografskim osobinama, Ivankovo je prostor kontinuiranoga naseljavanja od prapovijesti do danas, što potvrđuju brojni arheološki nalazi (Krznić Škrivanko 2003).

Najstariji poznati izvori o Ivankovu vezani su uz crkvu sv. Jurja. Radi se o računima izvanredne papinske desetine koju su između 1332. i 1337. godine u Ugarskoj skupljali francuski svećenici Jakob Berengarii i Raimund de Bonofato, odnosno od 1334. Jakob de Lengres. U njima se Ivankovo spominje šest puta između 1333. i 1335. godine, a visina ukupne uplate iznosila je nešto više od tri marke (Andrić 2003: 31–32), odnosno 930 banskih denara (Petković 2006: 39). To je bio veoma visok iznos koji nam govori o Ivankovu kao važnome župnom središtu i naselju znatne ekonomske snage. Izgradnja spomenute crkve može se staviti u kraj 13. ili početak 14. stoljeća. Izgrađena je od opeke, a u donjim dijelovima primjetno je i znatno prisustvo rimskih opeka. Dimenzije gotičke faze crkve, dakle bez novovjekovnih prigradnji, iznose 22 x 10 m. Unutarnje dimenzije broda bile su 14,5 x 8 m, a svetišta 5 x 6 m. Ukupna površina je u srednjem vijeku iznosila 142 m², od čega je 116 m² otpadalo na prostor predviđen za vjernike. Na osnovi tih podataka, primjenjujući Kralovánszkyjevu metodu koja povezuje broj i veličinu crkava u mjestu s brojnošću populacije, D. Petković procjenjuje da je tijekom 14. stoljeća u Ivankovu živjelo 640 osoba (Petković 2006: 39–41). Tim više začuđuje nedostatak drugih izvora sve do pred kraj 14. stoljeća. Tada zbog sukoba oko ugarsko-hrvatskoga prijestolja, između pristalica Karla II. Dračkog i Žigmunda Luksemburškog, Ivankovo u kratkome periodu nekoliko puta mijenja vlasnike. Nakon poraza Karla II., Ivankovo 1389. godine nakratko prelazi u vlasništvo obitelji Gorjanski. Međutim, oni ga već iduće godine vraćaju kralju Žigmundu u zamjenu za tvrđavu Apácasomló (Somló) u Vesprenskoj županiji (Andrić 2003: 33). Iz druge polovice 15. stoljeća očuvano je više izvora koji ponovo svjedoče o čestim promjenama gospodara posjeda. Tako cijeli posjed 1453. godine dolazi u vlasništvo bana Ivana Korodškog (Andrić 2003: 35). Nakon njegove smrti udovica Elizabeta poklanja u svoje ime i ime svoga sina Gašpara svoje posjede, među kojima se nalazilo i Ivankovo, braći Ivanu i Rajnaldu te Ivanovu sinu Ivanu Rozgonyi. Ta darovnica je ubrzo opozvana, najvjerojatnije zbog nekanonskoga sklapanja braka Gašpara i Apolonije, kćeri Ivana Rozgonyija (Andrić 2003: 38; Petković 2006: 46). Tijekom druge polovice 15. stoljeća vlasnici Ivankova su i Nikola Čupor Moslavački te Petar Ištija od Dabasa i njegova braća. Vlastelinstvo i kaštel Ivankovo 1488. godine dolaze u posjed trojice plemića iz roda Geréb: hrvatskoga bana Matije, erdeljskoga biskupa Ladislava i palatina Petra. U vrijeme njihova vlasništva nad posjedom 1490. godine Ivankovo je stradalo u pljački i paležu koje su proveli pristaše Maksimilijana Habsburgovca. O tome nam svjedoči

INTRODUCTION

The village of Ivankovo lies in the plain west of Vinkovci. Due to its favourable geographic location, as well as topographic, climatic, and hydrographic features, Ivankovo has been continually inhabited since the prehistoric period until today, which can be confirmed by numerous archaeological finds (Krznić Škrivanko 2003).

The earliest known sources about Ivankovo have to do with St. George's church. The documents in question are the receipts for a special tithe which was collected by French priests Jakob Berengarii and Raimund de Bonofato between 1332 and 1337, and by Jakob de Lengres in 1334. Ivankovo was mentioned six times between 1333 and 1335, and the amount to be paid was slightly more than three marks (Andrić 2003: 31–32), or 930 *denarii banales* (Petković 2006: 39). It was a large amount, which suggests that Ivankovo was an important parish centre and a village of significant economic power. The construction of the aforementioned church can be situated in the late 13th or early 14th century. It was built of bricks, and a considerable number of Roman bricks can be detected in the lower layers. The dimensions of the Gothic phase of the church, without the additions made in the early modern period, are 22 x 10 m. The inner dimensions of the nave were 14.5 x 8 m, while the sanctuary was 5 x 6 m. The total surface of the church in the Middle Ages was 142 m², of which 116 m² were designated for worshippers. Based on that data and using Kralovánszky's method which puts the number and size of churches in a settlement in correlation with population numbers, D. Petković estimated that 640 people lived in Ivankovo during the 14th century (Petković 2006: 39–41). That makes the lack of sources up until the late 14th century even more unusual. It was then that Ivankovo changed hands multiple times due to the conflict over the throne of the Croato-Hungarian Kingdom between the supporters of Charles II of Durazzo and Sigismund of Luxembourg. After the defeat of Charles II, Ivankovo briefly became the property of the Garai family in 1389. But it was returned to King Sigismund the following year when it was exchanged for fort Apácasomló (Somló) in Veszprem County (Andrić 2003: 33). Multiple preserved sources from the second half of the 15th century attest to frequent changes of the owners of the estate. Johannes Kórógy became the owner of the whole estate in 1453 (Andrić 2003: 35). After his death, his widow Elisabeth, on her behalf and the behalf of her son Gaspar, gave her estates, Ivankovo included, to brothers John and Rainald, and John's son John Rozgonyi. That deed of donation was soon revoked, probably because of the uncanonical marriage between Gaspar and Apolonia, the daughter of John Rozgonyi (Andrić 2003: 38; Petković 2006: 46). During the second half of the 15th century, Nikola Čupor Moslavački and Petar Ištija of Dabas and his brothers were also owners of Ivankovo. The feudal possession and Ivankovo Castle were acquired by three noblemen from the Geréb family in 1488; ban of Croatia Matthias, Ladislaus, Bishop of Transilvania, and palatine Peter. While they were owners of the estate, in 1490, Ivankovo was plundered and burned down by supporters of Maximilian Habsburg. The

istraga provedena 1493. godine protiv Ivana Kishorvátha od Hlapčića, Lovre Bánfyja Gorjanskog, Franje i Ivana Berislavića te ljudi vranskoga priora Bartola Berislavića. Njih su Ladislav i Petar Geréb optužili da se tijekom 1490. godine napali njihova trgovišta Ivankovo, Szombathely, Šarengrad i Osijek. Opis provedenoga nasilja u Ivankovu donosi Andrić (2003: 39–40): ... *naoružanim i nasilnim rukama, rabeći bojna pomagala i sprave, na neprijateljski način došli u trgovište istih podnositelja tužbe zvano Ivankovo (IwankazenthGiergh) u vukovskoj županiji, i pred kaštel što se također ondje nalazi, te su opsadom zauzeli isti kaštel i u njemu nekima od ljudi i familijara istih [Geréba] zadali strašne batine i rane, a mnoge druge poubijali žaljenja vrijednim umorstvima; u samom su pak trgovištu opljačkali i oveli svekolike stvari i dobra, štoviše – neke su od jobagiona istih [Geréba] zarobili pa ih sporazumno pustili za velike novce; k tome su u istom trgovištu mnoge kuće ognjem zažgali i spalili – nanijevši svime rečenim, nasilnim putem, istim podnositeljima tužbe štetu od tri tisuće zlatnih florena ...*¹ Nakon smrti posljednjega od braće – palatina Petra, Ivankovo je stekao hrvatski herceg Ivaniš Korvin, no posjed ubrzo prelazi u ruke Ladislava iz roda Szentpétri, a nakon 1507. godine preuzimaju ga pripadnici dviju srodnih plemićkih obitelji – Nagypói i Zay. Posljednji predturski gospodar Ivankova bio je Franjo Zay čije posjede u Pobosuću, pa tako i Ivankovo, Osmanlije osvajaju 1536. godine (Andrić 2003: 40).

Na osvojenome području brzo se organizirala nova uprava, pa je u Nijemcima organizirano sjedište kadiluka kojem su pripadale četiri nahije u Ivankovu, Podgorju, Posavju i Rači. U prvim desetljećima turske vladavine nestaju brojne katoličke župe, no ona u Ivankovu se održala. Iako je u periodu turske vladavine Ivankovo jedno od najznačajnijih naselja na ovome području s brojnom muslimanskom populacijom, preživjelo je i dosta katoličkoga stanovništva. Prema izvješću apostolskoga vizitatora Petra Maserechija 1624. godine župi Ivankovo pripada devet naselja s oko 3000 katolika, ali također ima i mnogo kalvinista i pravoslavnih Vlaha koje su Turci doveli u ove relativno nenaseljene krajeve. O relativno brojnoj katoličkoj populaciji govori i činjenica da je dva puta, 1626. i 1630. godine, Ivankovo posjetio i skradinski biskup Tomo Ivković i tom prilikom krizmao 223 vjernika. Oko 1690. godine u Ivankovu i dalje živi 300 katoličkih obitelji (Landeka 2003: 45–46). Između 1690. i 1700. godine u ratovima za oslobođenje Slavonije Ivankovo je razoreno, a stanovništvo je izbjeglo. Međutim, do 1700. godine situacija se smiruje, razaranja prestaju i mjesto se ponovo uređuje i razvija. U njega se doseljava novo stanovništvo iz zapadne Hrvatske, Bačke i Bosne te se od tada nadalje broj stanovnika kontinuirano povećava (Landeka 2003: 46–48).

U izvorima spominjana srednjovjekovna crkva sv. Jurja identična je današnjoj župnoj crkvi Rođenja sv. Ivana Krsti-

investigation into John Kishorvát of Hlapčić, Lovro Bánffy Gorai, Francis and John Berislavić, and men employed by Bartol Berislavić, prior of Vrana, in 1493 testifies to that. They were accused of attacking market towns of Ivankovo, Szombathely, Šarengrad, and Osijek in 1490 by their owners, Ladislaus and Peter Geréb. Andrić provides a description of the violence (2003: 39–40): ... *armed and violent, using numerous tools and aids, they came in a hostile manner to the market town called Ivankovo (IwankazenthGiergh) in Vukovar County, owned by the plaintiffs, and in front of the Castle as well, and sieged the aforementioned Castle and beat severely some of their [Gerébs'] men and family members, while many others were killed in regrettable murders; they robbed the market town of numerous things and assets, moreover – they captured some of their [Gerébs'] castle warriors and released them for a great amount of money; they also set on fire and burned down many houses in the same market town – by which they caused the same aforementioned plaintiffs, violently, damage worth three thousand golden florens...*¹ After the death of the last of the brothers – palatine Petar, Ivankovo was acquired by Croatian duke John Corvinus, but the estate soon fell into the hands of Ladislaus from Szentpétri family, and after 1507 it was taken over by two related noble families – Nagypói and Zay. The last owner of Ivankovo before the Ottoman invasion was Francis Zay, whose estates around the Bosut river, including Ivankovo, were conquered by the Ottomans in 1536 (Andrić 2003: 40).

A new administration was quickly formed on the conquered territory: the centre of kaza was in Nijemci, which commanded over four nahiyahs, in Ivankovo, Podgorje, Posavje, and Rača. In the first decades of Ottoman rule, many Catholic parishes perished, but the parish in Ivankovo survived. Although during Ottoman rule Ivankovo was one of the most important settlements in the area, with many Muslim inhabitants, a significant number of Catholics persisted. According to the report by apostolic visitor Peter Maserechi, in 1624 the parish of Ivankovo encompassed nine settlements with around 3000 Catholics, but also many Calvinists and Orthodox Vlachs, who were brought to this relatively sparsely inhabited area by the Ottomans. The fact that Bishop of Skradin Tomo Ivković visited Ivankovo two times, in 1626 and 1630, and administered the sacrament of Confirmation to 223 believers also attests to the relatively numerous Catholics population. Around 1690 there were still 300 Catholic families living in Ivankovo (Landeka 2003: 45–46). Between 1690 and 1700, during wars for Slavonia, Ivankovo was destroyed and its population fled. By 1700 the situation normalized, the war destructions ceased, and the village entered a phase of reconstruction and development. New population arrived from the western Croatia, Bačka, and Bosnia. From then on the population number constantly increased (Landeka 2003: 45–48).

The medieval church of St. George, mentioned in the sources, was identical to the present parish church of the Birth of St. John the Baptist. It was a single-nave Gothic church that was restored in the Baroque and Gothic Revival

1 Upravo ovakve epizode nasilja mogući su uzrok traumama koje su ustanovljene na skeletnim ostacima pokojnika pronađenima prilikom arheoloških istraživanja.

1 These violent episodes might be causes of traumas found on skeletal remains of the deceased discovered during archaeological excavations.

telja. Radi se o jednobrodnoj gotičkoj crkvi, obnavljanoj u baroknom i neogotičkom stilu s užim i nižim poligonalno zaključenim svetištem s potpornjacima. Obje sakristije i toranj iznad pročelja recentnije su građevine, budući da se u vizitacijama s početka 18. stoljeća još ne spominju (Vukičević Samaržija 1986: 109). Kanonske vizitacije iz 1729. godine, kada je Ivankovo posjetio Gabrijel Bačić, prepošt kaptola u Pečuhu, opisuju crkvu kao staru, građenu od pečene cigle, koja je u novije doba popravljena i pokriva daščicama te je dobila pod (u svetištu) i tarac (u ostalome dijelu), a ograđena je kolcima. U crkvi su se tada nalazila tri kamena oltara, a na glavnom se nalazi slika sv. Ivana Krstitelja. Osim crkve, u vizitaciji se spominje i veliko groblje koje se nalazi unutar crkvene cinkture, tj. unutar ograde koja okružuje crkvu (Horvat 2000: 104; Landeka 2003: 47).

ARHEOLOŠKO ISTRAŽIVANJE UZ CRKVU ROĐENJA SV. IVANA KRSTITELJA

Obilaskom lokaliteta u jesen 2006. godine djelatnici Gradskoga muzeja Vinkovci ustanovili su da je sa sjeverne i istočne strane crkve Rođenja sv. Ivana Krstitelja u Ivankovu iskopan teren radi drenaže crkve. U iskopu je uočen veći broj uništenih grobova. Kako su humusni sloj i dio predzdravičnoga sloja uklonjeni strojno, bez prisustva arheologa, tom je prilikom uništen nepoznat broj grobova (Krznić Škrivanko 2007: 48). U travnju 2008. godine arheolozi Gradskoga muzeja Vinkovci obavili su zaštitno arheološko istraživanje uz sjeverni zid te oko apside crkve.² Istražene su dvije sonde: sonda I dimenzija 22,4 x 4,15 m smještena je uz sjeverni zid crkve, a na istoku je omeđena kapelom sv. Ante; sonda II smještena je uz sjeverni zid kapele sv. Ante te u produžetku istočne strane crkve, tj. apside, u prosječnoj širini od 1,5 do 2 m. Obje sonde presječene su brojnim recentnim ukopima: gromobranom, spremnikom za naftu, plinskom instalacijom i šahtom (Krznić Škrivanko 2009: 84).

U iskopu je istraženo nekoliko slojeva štete nastalih tijekom raznih faza obnove crkve, ostaci starije arhitekture te nekoliko jama, a također je istraženo i 55 grobova. Većina grobova nalazi se u zapadnoj polovici sonde I. Za prostor istočno od zida (SJ 9) M. Krznić Škrivanko (2009: 84) pretpostavlja da se tamo nalazio sjeverni transept gotičke faze crkve. U sondi I djelomično su istražene i tri jame okrugloga presjeka čije zapune su se sastojale od zemlje, gara, ulomaka srednjovjekovne i novovjekovne keramike, novca te u najvećoj mjeri kostiju iz razorenih grobnih cjelina. Vjerojatno se radi o ukopima bunara. Ispražnjene su i dvije pliče zapune manjih rupa za stupove. Od ostataka starije arhitekture ustanovljen je zid rađen od rimskih opeka (SJ 9) koji se pruža okomito na sjeverni zid lađe crkve (u smjeru sjever – jug) i njen je integralni dio. Paralelno sa sjevernim zidom crkve u dužini od 6 m istražen je temelj za vanjsko stepenište ambona. Stepenište je izgrađeno u neogotici, a uklonjeno je tijekom adaptacije crkve 60-ih godina 20. stoljeća. Također, pronađeni su i temelji kontrafora smještenih na spoju lađe

styles, with narrower and lower polygonal termination to the sanctuary with buttresses. Both sacristies and the tower above the front wall are more recent, considering they were not mentioned in the visitations from the early 18th century (Vukičević Samaržija 1986: 109). Canonical visitations from the year 1729, when Ivankovo was visited by Gabrijel Bačić, provost of the Pecs chapter, described the church as old, made of fired bricks, recently repaired and covered with wooden shingles, mentioned that it had acquired a new floor (in the sanctuary) and pavement (in the rest of the building) and that it was surrounded by stakes. There were three stone altars in the church at the time, and the main one had a picture of St. John the Baptist. Besides the church, the visitation mentioned a larger cemetery inside the church walls, i.e. inside the fence enclosing the church (Horvat 2000: 104; Landeka 2003: 47).

ARCHAEOLOGICAL EXCAVATION NEXT TO THE CHURCH OF THE BIRTH OF ST. JOHN THE BAPTIST

During the visit of the site in autumn 2006, the Vinkovci Municipal Museum staff ascertained that a drainage trench was dug out to the north and east of the church of the Birth of St. John the Baptist. There were numerous destroyed graves noticed in the trench. Since no archaeologists were present when the humus and a part of the pre-sterile soil layer were removed by an excavating machine, the number of graves destroyed on that occasion is unknown (Krznić Škrivanko 2007: 48). In April 2008, a team from Vinkovci Municipal Museum conducted a rescue archaeological excavation by the northern wall and the apse of the church.² Two trenches were excavated: trench I, with dimensions 22.4 x 4.15 m, next to the northern wall of the church, with the chapel of St. Anthony to the east; trench II was placed next to the northern wall of the chapel of St. Anthony, and by the eastern side of the church, i.e. the apse, with an average width of 1.5 to 2 m. Both trenches were cut by numerous more recent digs: for a lightning rod, oil container, gas piping, and a manhole (Krznić Škrivanko 2009: 84).

The excavation revealed a few layers of rubble which were created during various phases of church restoration, remains of an earlier building, and a few pits. Besides that, 55 graves were excavated. Most graves were situated in the western half of the trench I. M. Krznić Škrivanko (2009: 84) assumes that the area east of the wall (SU 9) was where the northern transept of the Gothic phase of the church was. Three circular cross-section pits were also excavated in trench I, which were filled with dirt, soot, fragments of medieval and early modern period ceramics, coins, and mostly bones from destroyed graves. Those most probably were digs for wells. Two shallower fills of smaller post holes were also excavated. As a remnant of earlier architecture, a wall made of Roman bricks (SU 9) was discovered, which is situated vertically in relation to the nave of the church (aligned north – south) and it is its integral part. The foundation for the external staircase of the ambo was excavated.

2 Voditeljica istraživanja bila je Maja Krznić Škrivanko, muzejska savjetnica.

2 The excavation was led by Maja Krznić Škrivanko, the museum advisor.

i apside crkve te ispod istočnoga zida kapele sv. Ante. Uz istočni zid sakristije nalazi se još jedan temelj koji je vjerojatno izgrađen kao pojačanje temelja prilikom podizanja kata sakristije (Krznić Škrivanko 2009: 84–85). Kako je glavna tema ovoga rada (bio)arheološka analiza koštanih ostataka kasnosrednjovjekovnih i ranonovovjekovnih stanovnika Ivankova pokopanih na ovome groblju, posvetit ćemo se samo analizi pronađenih grobova, dok se ostali nalazi ovdje neće obrađivati.

OPĆE KARAKTERISTIKE GROBLJA I ANALIZA NALAZA

Kao što smo već naveli, u obje istražene sonde pronađeno je ukupno 55 grobova (sl. 1). Kako su humus i dio slojeva skinuti bagerom bez prisustva arheologa, nije sigurno koliko je grobova u tim slojevima uništeno. U sondi I uz sjeverni zid crkve istraženo je 49 grobova, od kojih je većina (46) pronađena između zapadnoga ruba sonde I i zida SJ 9. Samo 3 groba smještena su u istočnome dijelu sonde između zida SJ 9 i zapadnoga zida kapele sv. Ante. Jedan od njih je i grob 47. Radi se o recentnijem ukopu, najvjerojatnije svećenika, koji je ukopan na gotovo dva metra relativne dubine.³ Drugi ovdje istraženi grob pronađen je uz temelj za stepenište ambona. Pokojnik je bio položen na desni bok između temelja crkve i temelja stepeništa. U sondi II pronađeno je još 6 grobova koji su se nalazili ispred sjevernoga zida kapele sv. Ante. Grobovi u preostalom dijelu sonde II nisu pronađeni (Krznić Škrivanko 2009: 85).

Budući da se ukopi i zapune raka pojedinih grobova uglavnom nisu mogli ustanoviti, međusobni odnosi grobova, ukoliko nije došlo do samoga presijecanja kostiju, također se u većini slučajeva ne mogu pouzdano utvrditi. Kao što je uobičajeno na kasnosrednjovjekovnim i ranonovovjekovnim župnim grobljima smještenima oko crkvi, prilikom ukopa mlađih grobova ni ovdje se nije vodila pažnja o položaju starijih grobova, pa su oni često presijecani i devastirani, a kosti dislocirane. Svi pronađeni pokojnici položeni su u zemljane rake bez ikakve arhitekture. Pokojnici su uglavnom pokopavani omotani u mrtvački pokrov, no pojedini, vjerojatno nešto imućniji članovi zajednice, ukopani su u lijesu.⁴ Na taj je način pokopano samo sedam osoba: tri muškarca (grobovi 17, 25 i 26), dvije žene (grobovi 19 i 33) i dva djeteta (grobovi 27 i 29). U samo tri slučaja (grobovi 2, 26 i 27) pronađeni su ostaci drva (sl. 2), a prisustvo lijesa u ostalim navedenim grobovima može se pretpostaviti na osnovi pronađenih željeznih čavala. Većina grobova orijentirana je u smjeru zapad – istok. Orijentaciju sjeverozapad – jugoistok imaju samo dva groba (grobovi 9 i 11). Oba groba pripadaju među mlađe pronađene na lokalitetu i datiraju se u rani novi vijek, dakle u period kada se orijentacija zapad – istok više ne poštuje tako strogo kao ranije (Predovnik et al. 2008: 92).

It was parallel with the northern wall of the church and 6 m long. The staircase was built during the Gothic Revival and it was removed during the restoration of the church in the 1960s. There was also the foundation of a buttress found, situated at the joint of the nave and the apse of the church and below the eastern wall of the chapel of St. Anthony. There is another foundation next to the eastern wall of the sacristy, which was probably constructed to enhance the original foundations when the top floor of the sacristy was built (Krznić Škrivanko 2009: 84–85). Since the topic of this paper is (bio)archaeological analysis of skeletal remains of the late medieval and early modern population of Ivankovo buried at this cemetery, we will analyse only the graves, while other finds will not be interpreted.

GENERAL CHARACTERISTICS OF THE CEMETERY AND THE ANALYSIS OF THE FINDS

As previously stated, 55 graves were found in both excavated trenches (Fig. 1). Since no archaeologists were present when the humus and a part of the layers were removed by an excavating machine, the number of destroyed graves is unknown. There were 49 graves excavated in the trench next to the northern wall of the church, most of which (46) were found between the northern edge of trench I and wall SU 9. Only 3 graves were situated in the eastern part of the trench, between wall SU 9 and the western wall of the chapel of St. Anthony. One of them is grave 47. It is a more recent burial, probably of a priest, who was buried at almost two meters of relative depth.³ The second excavated grave was found next to the foundation of the staircase of the ambo. The individual in the grave was placed on its right side, between the foundation of the church and the foundation of the staircase. There were six more graves found in trench II, which were situated in front of the northern wall of the chapel of St. Anthony. There were no graves found in the rest of the trench (Krznić Škrivanko 2009: 85).

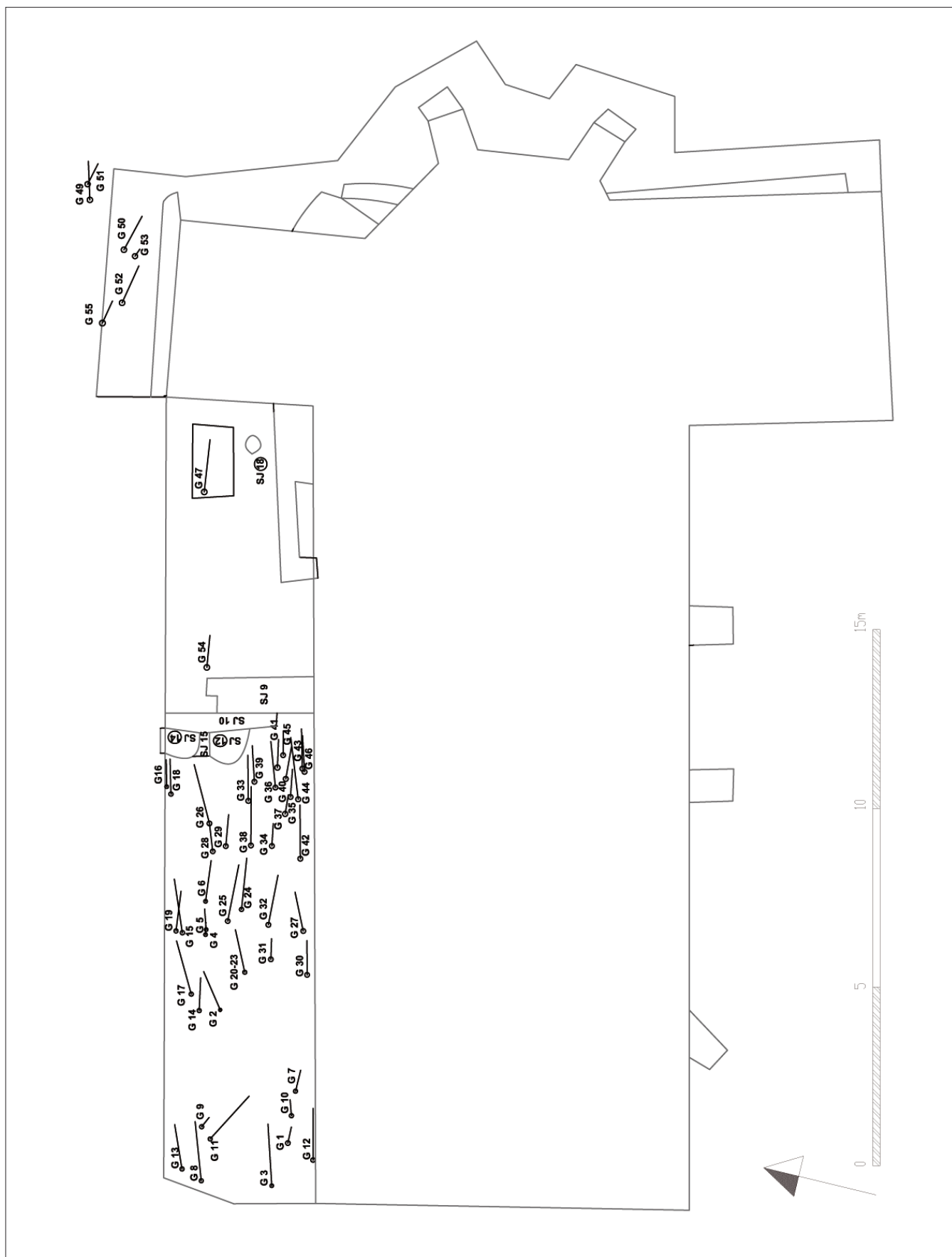
Since grave pits and fills of certain graves could not be determined, the relationships between graves in most cases could not be ascertained either, unless the bones were cut. As it was a custom at medieval and early modern parish cemeteries around churches, nobody was considering the positions of earlier graves during later burials, so the earlier graves were often truncated and destructed, while the bones were dislocated. All the individuals were put into grave pits with no grave architecture. The deceased were usually buried wrapped in a shroud, but some, probably more affluent members of the community, were buried in coffins.⁴ Only seven people were buried that way: three men (graves 17, 25, and 26), two women (graves 19 and 33), and two children (graves 27 and 29). Wood residues (Fig. 2)

3 Ovaj grob je prilikom arheološkoga istraživanja samo fotografiran i ponovo zatrpan, odnosno kosti nisu uzimane za antropološku analizu.

4 Lijes je često korišten samo za prijenos pokojnika do groba gdje bi se tijelo vadilo iz njega i polagalo u grob samo umotano u tkaninu. Ako je pokojnik bio imućniji, lijes je mogao biti izrađen samo za njega i pokopan s njim u grob (Daniell 2005: 40).

3 The grave was just photographed and filled again after the archaeological excavation, i.e. the bones were not included in the anthropological analysis.

4 The coffin was often used for transporting the deceased to the grave, where the body was taken out of it and placed in the grave wrapped in fabric. If the deceased was more affluent, the coffin could be made only for them and buried with them (Daniell 2005: 40).



Sl. 1 Shematski tlocrt crkve i istraženih grobova (izradio: H. Vulić; prilagodila: K. Turkalj)
 Fig. 1 Schematic ground plan of the church and excavated graves (made by: H. Vulić; adapted by: K. Turkalj)



Sl. 2 Ostaci lijesa u grobu 26 (arhiva Gradskoga muzeja Vinkovci)
Fig. 2 Coffin remains in grave 26 (Vinkovci Municipal Museum archives)

Zbog čestoga oštećenja kostiju pokojnika, položaj barem jedne podlaktice mogao se ustanoviti kod samo 24 ukopa. Podlaktice su najčešće smještene na zdjelici (sedam pokojnika ili 29,2 %), odnosno na trbuhu (šest pokojnika ili 25 %). Po četiri pokojnika imaju ruke ispružene uz tijelo, odnosno jednu podlakticu na trbuhu, a drugu na zdjelici (16,7 %). U po jednome slučaju prisutni su sljedeći položaji: jedna podlaktica na trbuhu, a druga na prsima; jedna podlaktica uz tijelo, a druga na zdjelici; jedna podlaktica na trbuhu, a druga savinuta u laktu i položena na nadlakticu. Kao što je vidljivo, prisutne su različite varijacije položaja podlaktica, no prevladavaju dva položaja: s podlakticama na zdjelici i trbuhu, a to su najčešći položaji i na brojnim drugim kasnosrednjovjekovnim i ranonovovjekovnim grobljima u sjevernoj Hrvatskoj (Krznar, u tisku).

Nalazi su otkriveni u samo 10 grobova, od kojih su u njih šest ukopane muške osobe, a u preostala četiri žene. U gro-

were found in only three cases (graves 2, 26, and 27), while the presence of a coffin in other mentioned graves can be assumed based on iron nails found in them. Most graves are aligned west-east. Only two graves (graves 9 and 11) are aligned northwest-southeast. Both of them belong to the group of later graves found at the site and are dated to the early modern period, therefore, in the period when the orientation west-east was not adhered to as it was in the earlier periods (Predovnik et al. 2008: 92).

Since the bones of the deceased are often damaged, the position of at least one forearm could be determined in only 24 burials. Forearms were most frequently placed on the pelvis (seven people or 29.2%), i.e. on the stomach (six people or 25%). Four people have their arms extended by the sides of their bodies, four have one forearm on their stomach, and the other on their pelvis (16.7%). There is one instance of each of the following: one forearm on the stomach, the other on the chest, one forearm by the side, the other on the pelvis, and one forearm on the stomach, the other bent in the elbow and placed on the upper arm. As indicated, there are different variations in forearm placement, but two positions prevail: with forearms on the pelvis and the stomach, which are the most common positions at many other late medieval and early modern cemeteries in the north of Croatia (Krznar, in press).

Only 10 graves contained finds; men were buried in six and women in four of them. There were no finds in children's graves. Aside from one knife, the finds were mostly jewelry (rings) and costume fragments (belts, belt buckles, hook-and-eye fasteners, and pins). More than one find was excavated from only two graves (2 and 33), while grave 33 particularly stands out, with fragments of a veil, four rings, and a belt decorated with appliqué. Women were buried in both of those graves.

Knife (Pl. 1: 7)

It was found in the grave of an adult woman (G 19), on the outside of her left knee. Since knives were not a common part of women's costumes, we can assume that the knife was put in the grave as part of folklore and tradition. Objects such as knives, sickles, scissors, keys, and padlocks are usually connected with superstitions and should have the apotropaic function of protecting the deceased from the devil or they should protect the living members of the community from the negative activities of the dead. In Central Europe knives can often be found in the graves of women who died at childbirth or soon after it, and Unger (2006: 60) thinks that they probably had a symbolic purpose of cutting or severing the ties between the children who were born alive and the deceased mother. The find is a straight-backed tanged knife with a wooden handle and shoulder plate and leaf-shaped end of the handle (butt) made of thin sheet metal. The blade is narrow and straight and slightly pointed at the top. The tang of the handle is narrower than the blade and widens toward the end, and the wooden handle is fastened by rivets. Knives of this type found in Magdalensberg in Carinthia, were classified by H. T. Dolenz (1992: 129–131, Pl. 9: 64–66) as group B/II b and dated to the second half of the 15th and 16th century. Similar knives with

bovima djece nalazi nisu pronađeni. Osim jednoga noža, uglavnom se radi o nakitu (prstenje) te dijelovima nošnje (pojas, pojasna kopča, kopčice s kukom i ušicom te igle). U samo dva groba (2 i 33) nađeno je više od jednoga nalaza, a njihovom količinom posebice se ističe grob 33 u kojem su pronađeni dijelovi vela, četiri prstena i pojas ukrašen aplikama. U oba slučaja radi se o grobovima ženskih osoba.

Nož (T. 1: 7)

Nož je pronađen u grobu odrasle žene (G 19) s vanjske strane lijevoga koljena. Kako noževi nisu uobičajeni inventar ženske nošnje, možemo pretpostaviti da je nož stavljen u grob kao dio narodnih vjerovanja i tradicija. Predmeti kao što su noževi, srpovi, škare, ključevi, lokoti uglavnom se povezuju s praznovjermem, a trebali su imati apotropejsku ulogu zaštite pokojnika od vruga ili su pak trebali štiti živu članove zajednice od negativnoga djelovanja mrtvih. Na području srednje Europe noževi se često nalaze u grobovima žena umrlih na porodu ili ubrzo nakon njega, a Unger (2006: 60) smatra da su najvjerojatnije imali simboličku svrhu rezanja, odnosno prekidanja veza između živorođene djece i preminule majke. Pronađeni nož je ravnoga hrpta sječiva s trnom obloženim drvom te ramenom pločicom i završetkom drške (petom) u obliku listića od tankoga lima. Sječivo je usko i ravno te na vrhu lagano zakošeno u šiljak. Trn drške je uži od oštrice i širi se prema kraju, a drvena oplata je pričvršćena zakovicama. Ovakve noževe pronađene u Magdalensbergu u Koruškoj H. T. Dolenz (1992: 129–131, T. 9: 64–66) svrstao je u svoju B/II b skupinu i datira ih u drugu polovicu 15. i u 16. stoljeće. Slične noževe s drvenom oplatom ručke pričvršćene zakovicama te petom ručke u obliku listića izrađene od slitine bakra pronađene u Mađarskoj Holl (1995: 174, Abb. 11: 5; 177, Abb. 14) datira u 15. i 16. stoljeće. Noževi sličnoga oblika pronađeni su i na burgu Vrbovec u Klenovcu Humskom. Tamo su na osnovi stratigrafije također datirani u 15. ili 16. stoljeće (Tkalčec 2010: 90–91, 186, T. 28: 439–440). Noževi istoga tipa pronađeni u rijeci Ljubljanici kod Ljubljane datiraju se u prvu polovicu 16. stoljeća (Veršnik 2009: 362–363, sl. 118a), odnosno u drugu polovicu 15. i u 16. stoljeće (Veršnik 2009: 380–381, sl. 134). Na osnovi ovih analogija, i nož pronađen u grobu 19 u Ivankovu možemo datirati u 15./16. stoljeće.

Prstenje

Prstenje sa šest pronađenih primjeraka čini najbrojniji pojedinačni tip nalaza. Pronađeni su kod jednoga muškarca (grob 16) te dvije ženske osobe (grobovi 2 i 33). U grobu 33 pronađena su čak četiri prstena (T. 1: 11–13, 16). Iako se uglavnom nosio po jedan prsten, ovakav običaj nošenja većega broja prstenja zabilježen je i na drugim kasnosrednjovjekovnim i novovjekovnim grobljima (Jelovina, Vrsalović 1981: 74, 76–77; Petrinec 1996: 34–35, 40; Perkić 2010: 240; 2017: 201). Prstenje u obliku jednostavne karike najčešći je tip zastupljen s četiri primjerka. Dva prstena su bez ukrasa (T. 1: 5, 13), a kod dva je karika trakasta presjeka ukrašena s dva paralelna žlijeba (T. 1: 11–12). Na groblju u Begovači kod Biljana Donjih ovakvo prstenje pronađeno je u 25 grobova starohrvatskoga horizonta (Jelovina, Vrsalović 1981: 120) te

wooden handles attached by rivets, with handle butts in the shape of a thin leaf made of copper alloy found in Hungary were dated by Holl to the 15th and 16th centuries (Holl 1995: 174, Abb. 11: 5; 177, Abb. 14). Similar knives were found at Vrbovec Castle in Klenovec Humski. They were also dated to the 15th or 16th century based on stratigraphy (Tkalčec 2010: 90–91, 186, Pl. 28: 439–440). Knives of the same type found in the Ljubljanica river near Ljubljana were dated to the first half of the 16th century (Veršnik 2009: 362–363, Fig. 118a), i.e. to the second half of the 15th and to the 16th century (Veršnik 2009: 380–381, Fig. 134). Based on these analogies, the knife from grave 19 in Ivankovo, too, can be dated to the 15th/16th century.

Rings

With six of them, rings are the most numerous types of finds. They were found next to one man (grave 16) and two women (graves 2 and 33). As much as four rings were discovered in grave 33 (Pl. 1: 11–13, 16). Although it was common to wear one ring, the custom of wearing multiple rings was noticed at other late medieval and early modern cemeteries as well (Jelovina, Vrsalović 1981: 74, 76–77; Petrinec 1996: 34–35, 40; Perkić 2010: 240; 2017: 201). With four of them, rings in the shape of a simple hoop are the most common type of fingerings. Two rings have no decorations (Pl. 1: 5, 13), while two of them have a banded sectioned hoop decorated with two parallel grooves (Pl. 1: 11–12). At the cemetery in Begovača near Biljani Donji, rings of this type were found in 25 graves of the early Croatian horizon (Jelovina, Vrsalović 1981: 120), and in five graves of the late medieval horizon (Jelovina, Vrsalović 1981: 131). Numerous rings of this type were found at the late medieval cemetery next to the church of the Holy Saviour (Sveti Spas) in Vrh Rika (Petrinec 1996: 21, 27, 29, 32, 34, 37, 41). A ring with banded section, decorated with two grooved horizontal lines, was found in a woman's grave 126 at Opatovina in Zagreb and it was dated to the last third of the 14th century, based on the burial horizon (Demo 2007: 70). This type of rings and all subtypes which were found at Novo Brdo were dated by E. Zečević (2006: 290–291) to the period from the 15th to 19th century. The rings were used during a long period of time and cannot be dated unless they were discovered within a precise context. Rings in the shape of a hoop are often considered to be wedding rings, but finding more identical rings in one grave, as it is the case here, brings that interpretation into question.

A ring with a slightly raised crown and thickened shoulders was found in grave 33 (Pl. 1: 16). The closest analogy for this ring is kept in the National Museum in Belgrade and is dated to the 14th or 15th century (Milošević 1990: 77, no. 73). Although we cannot disregard the fact that this type of ring was produced in the early modern period as well, it is more probable that this is an older ring used for a longer period of time which a dead woman from grave 33 inherited. A massive cast ring (Pl. 1: 1) was also found in a woman's grave (grave 2). No identical analogy for this ring was found, but cast bronze rings partly similar to this one in shape, but with a slight circular bulge on the bottom of the hoop, were

u pet grobova kasnosrednjovjekovnog horizonta ukopavanja (Jelovina, Vrsalović 1981: 131). Brojni primjerci ovoga tipa prstenja pronađeni su i na kasnosrednjovjekovnome groblju uz crkvu sv. Spasa u Vrh Rici (Petrinec 1996: 21, 27, 29, 32, 34, 37, 41). Prsten trakastoga presjeka, ukrašen dvjema uzdužnim užlijebljenim linijama, pronađen je i u ženskoj grobu 126 na Opatovini u Zagrebu gdje je, na osnovi horizonta ukopavanja, datiran u posljednju trećinu 14. stoljeća (Demo 2007: 70). Ovaj tip prstena i sve njegove podtipove pronađene na Novom Brdu E. Zečević (2006: 290–291) datira od 15. do 19. stoljeća. Ovakvo prstenje koristi se, dakle, kroz veoma dugi vremenski period i nisu databilni ukoliko se ne nalaze unutar sigurnoga konteksta. Prstenje u obliku karike često se smatra vjenčanim prstenjem, no prilikom takve interpretacije postavlja se pitanje značenja pronalaska više identičnih prstenova u jednome grobu kao što je to ovdje slučaj.

Prsten s lagano izdignutom glavom i naglašenim rame-nim pronađen je u grobu 33 (T. 1: 16). Najbliža analogija za ovaj prsten čuva se u Narodnome muzeju u Beogradu i datiran je u 14.–15. stoljeće (Milošević 1990: 77, br. 73). Iako ne možemo isključiti činjenicu da je ovakav tip prstena rađen i u ranome novom vijeku, vjerojatnija je pretpostavka da se radi o starijem prstenu koji je bio u upotrebi duži vremenski period i kojega je pokojnica iz groba 33 dobila u nasljedstvo. Masivni lijevani prsten (T. 1: 1) također je pronađen u grobu žene (grob 2). Posve identične analogije ovoga prstena nisu pronađene, no lijevano brončano prstenje koje donekle oblikom sliči ovome prstenu, ali za razliku od njega ima i blago kružno ispupčenje na dnu karike, pronađeno je na groblju u Novom Brdu i na Vodočkoj nekropoli kod Strumice. U oba slučaja prstenje je datirano u kraj 15. te u 16. stoljeće (Zečević 2006: 190, 291; Maneva 2011: 346, 350, sl. 10).

Dijelovi nošnje

Metalni dijelovi odjeće su najuobičajeniji nalaz na župnim grobljima. Uglavnom se radi o pojasnim kopčama te dvodijelnim kopčicama s kukom i ušicom. Jednodijelne kopče D okvira, kakva je pronađena u grobu 17 (T. 1: 6), prevladavaju od 13. do 15. stoljeća. Iako se u upotrebi nalaze i kasnije, tada su znatno rjeđe (Whitehead 1996: 16). Na osnovi stratigrafskih odnosa, kopča iz Ivankova može se datirati u 15. i 16. stoljeće. Takvu dataciju podupire i pronalazak kopče s D okvirom na burgu Vrbovcu gdje se također datira u prijelaz 15. na 16. stoljeće (Tkalcic 2010: 89, 185, T. 27: 418) te onih s groblja na Opatovini gdje su datirane u posljednje dvije trećine 15. stoljeća (Demo 2007: 83).

Dvodijelne kopče s kukom i ušicom (T. 1: 4, 9) pripadaju nošnji kasnoga srednjeg vijeka i u Hrvatskoj se rijetko pojavljuju prije druge trećine 15. stoljeća. Od sredine 15. stoljeća pa nadalje se relativno često pojavljuju na prostoru Hrvatske ali i srednje Europe, kako u kasnosrednjovjekovnim, tako i u novovjekovnim grobovima (Dorn 1978; Jelovina, Vrsalović 1981: 94; Sándor 1985: 188; Kerman 1997: 52, 352; Burić 2001: 276, 278; Sekelj Ivančan, Tkalcic 2003: 14–15, 31; Belaj 2006: 284–285, 293, sl. 42; 294, sl. 43–46; Demo 2007: 73). Nalaze se u grobovima žena, djece, ali i muškaraca, a

found at the cemetery in Novo Brdo and Vodoča necropolis near Strumica. In both cases, the rings were dated to the late 15th and 16th century (Zečević 2006: 190, 291; Maneva 2011: 346, 350, Fig. 10).

Costume parts

Metal clothes fragments are the most common finds at parish cemeteries. They are mostly belt buckles and two-part hook-and-eye fasteners. Single looped buckles with D-shaped frames, one of which was found in grave 17 (Pl. 1: 6), prevail from the 13th to the 15th century. Although they continued to be used after that, they became much less common (Whitehead 1996: 16). Based on stratigraphic relationships, the buckle from Ivankovo can be dated to the 15th or 16th century. This dating is supported by the discovery of the buckle with a D-shaped frame in Vrbovec Castle, which is also dated to the end of the 15th and beginning of the 16th century (Tkalcic 2010: 89, 185, Pl. 27: 418), and the buckles from the cemetery at Opatovina, which were dated in the latter two-thirds of the 15th century (Demo 2007: 83).

Two-part hook-and-eye fasteners (Pl. 1: 4, 9) belong to the costume from the late Middle Ages and appear rarely before the second third of the 15th century in Croatia. From the mid-15th century onwards, they are relatively common in Croatia, but also in Central Europe, both in late medieval and early modern period graves (Dorn 1978; Jelovina, Vrsalović 1981: 94; Sándor 1985: 188; Kerman 1997: 52, 352; Burić 2001: 276, 278; Sekelj Ivančan, Tkalcic 2003: 14–15, 31; Belaj 2006: 284–285, 293, Fig. 42, 294, Fig. 43–46; Demo 2007: 73). They were found in women's, children's, but also men's graves, and were placed in different positions next to the skeletons in those graves – next to calcanei, tibiae, femora, waist, neck, or collar bones, which indicates that they were used to fasten different parts of clothing. They were usually made of wire and copper alloy, or sometimes iron. The hook-and-eye fasteners cannot be precisely chronologically dated only based on their typology, but an example of later, or early modern, bigger and more elaborately decorated fasteners are the ones found at Martinbreg (Belaj 2006: 285, 294, Fig. 47).

Although belt buckles are relatively common finds, belts decorated with metal appliqué are very rarely found during archaeological excavations. A buckle with a plate, decorated with plant (floral) motifs and a sequence of bulging circles, from grave 33 was made from copper alloy. The belt was also decorated by a square perforated appliqué, which stylistically matches the buckle, and 26 bronze calotte-shaped appliqué attached all along the belt. There are no known analogies for this belt. It can be dated to the early modern period only based on the stratigraphic position of the grave (Pl. 1: 14–15 17).

Two pins (Pl. 1: 2–3) can also be classified as parts of the costume. They were both found in older women's graves. Their position indicates that they were used for securing veils, headgear, or some soft fabric to the head. Larger pins appear on the territory of the Kingdom of Hungary and Croatia as early as the 12th century (Nyáradi, Gáll 2015). In the 14th and 15th century, when fashion changed, they became small-

unutar grobova pronađene su u različitim položajima uz kostur – kod petnih kostiju, kod potkoljenica, kod bedrene kosti, u visini pojasa, kod vrata ili kod ključnih kostiju te se može zaključiti kako su služile pričvršćivanju različitih dijelova odjeće. Uglavnom su izrađene od žice iz slitine bakra ili ponekad željeza. Uže kronološko određenje jednostavnih kopči s kukom i ušicom samo na osnovi tipologije nije moguće, no kao mlade, odnosno ranonovovjekovne mogle bi se izdvojiti veće i bogatije ukrašene kopče kakve su pronađene na Martinbregu (Belaj 2006: 285, 294, sl. 47).

Iako su pojasne kopče relativno čest nalaz, pojasi ukrašeni metalnim aplikama veoma se rijetko nalaze tijekom arheoloških istraživanja. Vegetabilnim (cvijetnim) motivima te nizom ispupčenih krugova ukrašena kopča s pločicom iz groba 33 izrađena je od slitine bakra. Pojas je još ukrašavala pravokutna perforirana aplikacija koja stilski odgovara izgledu kopče te 26 brončanih kalotastih aplikacija koje su bile pričvršćene po cijeloj dužini pojasa. Analogije ovome pojasu nisu poznate te se on, samo na osnovi stratigrafskoga položaja groba u kojem je pronađen, može datirati u rani novi vijek (T. 1: 14–15, 17).

Pod dijelove nošnje možemo svrstati i dvije igle (T. 1: 2–3). Obje su pronađene u grobovima starijih žena. Prema položaju u grobu možemo pretpostaviti kako su služile za učvršćivanje vela, oglavlja ili neke lagane tkanine uz glavu. Igle nešto većih dimenzija javljaju se na prostoru Ugarsko-hrvatskoga kraljevstva već tijekom 12. stoljeća (Nyáradi, Gáll 2015). U 14. i 15. stoljeću promjenom mode postaju manje i tanje (Egan, Pritchard 2002: 297). Obično su izrađene od bronce ili drugih slitina bakra, a najčešće su smještene u blizini lubanje. Brojni nalazi datiraju se u 15./16. stoljeće (Juraga 1981: 69–70; Szóke 1996: 272; Demo 2007: 69; Tomičić, Mahović 2011: 138), no u upotrebi su i tijekom novoga vijeka (Simonyi 2004: 183–184, sl. 8). Pravokutna aplikacija (T. 1: 8) vjerojatno je služila ukrašavanju odjeće, a oblikom slična aplikaciji s pojasa koji je pronađen u grobu 2 u mjestu Rakacsaszend u Mađarskoj, a koji je datiran u drugu polovicu 15. stoljeća (Pálóczi-Horváth 1984: 125, sl. 15: 1–3, 145).

Iznad čela pokojnice iz groba 33 iz Ivankova pronađeni su dijelovi oglavlja ili vela – metalnom trakom obložena vlakna lana. Pronađeno je samo 6 fragmenta ukupne dužine 43,4 mm, a težine manje od 0,09 g (T. 1: 10).

STRATIGRAFSKI ODNOSI I KRONOLOGIJA GROBLJA

Na osnovi međusobnih stratigrafskih odnosa te odnosa prema crkvi i pronađenim nalazima možemo približe datirati pojedine grobove. Kao najstarije grobove, iz druge polovice 13. ili početka 14. stoljeća, na osnovi njihovoga odnosa s arhitekturom, možemo izdvojiti grobove 7, 27, 30, 39, 42 i 46. Nalazi u tim grobovima nisu pronađeni. Najmlađi grobovi pronađeni na lokalitetu su 47 i 48 koji pripadaju novovjekovnome periodu. Ranome novom vijeku, na osnovi ukopa u sloj građevinske štete nastale prilikom obnova i dogradnji crkve, može se pripisati ženski grob 33. Grob 19 se, zahvaljujući pronađenoj noži, može datirati u 15./16. stoljeće. Iako je u grobu 17 pronađena jednostavna željezna pojasna kopča s D okvirom, koje su češće u ranijem periodu, i on se zbog

er and thinner (Egan, Pritchard 2002: 297). They were usually made from bronze or other copper alloys and were often found near the skull. Numerous finds are dated to the 15th or 16th century (Juraga 1981: 69–70; Szóke 1996: 272; Demo 2007: 69; Tomičić, Mahović 2011: 138), but were also used during the early modern period (Simonyi 2004: 183, 184, Fig. 8). The square appliqué (Pl. 1: 8) which was probably used for decorating clothes is similar in shape to the appliqué on the belt found in the grave 2 in the village of Rakacsaszend in Hungary, which was dated to the latter half of the 15th century (Pálóczi-Horváth 1984: 125, Fig. 15: 1–3, 145).

Parts of headgear or veil – flax fibres enveloped in a metal band – were discovered above the forehead of the deceased woman from grave 33 in Ivankovo. Only 6 fragments were found, 43.4 mm in length, and weighing less than 0.09 g (Pl. 1: 10).

STRATIGRAPHIC RELATIONSHIPS AND CEMETERY CHRONOLOGY

We can determine the dates of burials of certain graves more closely based on their stratigraphic relationships, their positions in relation to the church, and the finds discovered within the graves. Based on their relations to the architecture, we can say that graves 7, 27, 30, 29, 42, and 46 are the earliest, dating from the second half of the 13th or beginning of the 14th century. There were no finds discovered in those graves. The latest graves found at this site were graves 47 and 48, belonging to the early modern period. Woman's grave 33 can also be dated to the early modern period, based on the burial in a layer of building rubble which was formed during renovations and extensions to the church. Owing to the discovery of the knife, grave 19 can be dated to the 15th or 16th century. An iron belt buckle with a D-shaped frame, which was common in the earlier period, was found in grave 17, but the grave can also be dated to the early modern period due to its relationship with grave 19, which was truncated by the aforementioned grave in its western part. Graves 2 and 14 can be dated to the 16th or 17th century based on their superposition over grave 17 and a massive cast ring found in grave 2. We can only say that grave 49, with a hook-and-eye fastener, does not pre-date the 15th century. The rest of the discovered graves did not have any finds in them and were buried in pre-sterile or sterile ground. Since the relationships between those graves, architecture, and the graves which were dated by finds cannot be ascertained, they can only be dated vaguely to the late medieval or early modern period, from the late 13th and the beginning of the 14th, all the way to the 18th century, when Joseph II introduced burial regulations which resulted in cemeteries being relocated away from churches and settlements (Podpečan 2006: 20, 22).

ANTHROPOLOGICAL ANALYSIS OF SKELETAL REMAINS

Methods

Human skeletal remains were analysed in detail using standard bioarchaeological methods. The analysis encompassed cataloging present bones and teeth, determining

svoga odnosa s grobom 19, kojem je presjekao zapadni dio, može okvirno datirati u to vrijeme. Grobove 2 i 14, na osnovi njihove superpozicije nad grobom 17 te nalaza masivnoga lijevanog prstena u grobu 2, možemo datirati u 16./17. stoljeće. Za grob 49, u kojem je pronađena kopča s kukom i ušicom, možemo samo reći da nije stariji od 15. stoljeća. Ostali pronađeni grobovi su bez nalaza i ukopani su u predzdravični sloj ili zdravicu. Kako se odnosi između tih grobova i arhitekture, odnosno grobova poblizje datiranih nalazima ne mogu ustanoviti, oni se za sada mogu samo široko datirati u kasnosrednjovjekovni/ranonovovjekovni period, odnosno od kraja 13. i početka 14. pa sve do 18. stoljeća kada su stupanjem na snagu higijenskih odredbi cara Josipa II. groblja odijeljena od crkve te preseljena izvan naselja (Podpečan 2006: 20, 22).

ANTROPOLOŠKA ANALIZA KOŠTANIH OSTATAKA

Metode

Ljudski kosturni ostaci detaljno su analizirani standardnim bioarheološkim metodama. Analiza je obuhvatila popisivanje prisutnih kostiju i zubi, određivanje dobi i spola osobe te evidentiranje patoloških promjena nastalih za života.

Dob djece određena je na osnovi promjena koje nastaju tijekom razvoja i nicanja mliječnih i trajnih zubi (Moorrees et al. 1963a; 1963b; Gustafson, Koch 1974; AlQahtani et al. 2009), kronologije spajanja epifiza s dijafizama te dužine dijafiza dugih kostiju (Maresh 1970; Scheuer, Black 2000; Schaefer et al. 2009). Dob odraslih osoba određena je na osnovi morfologije pubične simfize (Brooks, Suchey 1990) i aurikularne plohe (Lovejoy et al. 1985; Buckberry, Chamberlain 2002), stupnja srastanja ektokranijalnih šavova (Meindl, Lovejoy 1985), morfoloških promjena na sternalnom kraju rebara (Işcan et al. 1984; 1985) te stupnja istrošenosti grizne površine zuba (Brothwell 1981; Lovejoy 1985). Djeca su podijeljena u tri dobne skupine: 'mlađa djeca' (0 do 5 godina), 'starija djeca' (6 do 11 godina) i 'adolescenti' (12 do 17 godina). Spol odraslih osoba određen je na osnovi makroskopskoga pregleda usredotočenoga na razlike u morfologiji zdjelice i lubanje između odraslih muškaraca i žena (Krogman, Işcan 1986; Buikstra, Ubelaker 1994; Bass 1995). Odrasle individue, čiji spol nije mogao biti ustanovljen sa sigurnošću, označene su sa 'vjerojatno muškarci' i 'vjerojatno žene'. Odrasle individue označene kao 'vjerojatno muškarci' i 'vjerojatno žene' pridružene su svojim spolnim grupama, odnosno 'vjerojatno muškarci' s muškarcima i 'vjerojatno žene' sa ženama.

Svi kosturni ostaci i zubi analizirani su kako bi se uočile moguće patološke promjene. Uočene promjene detaljno su dokumentirane prema kriterijima koje su opisali Ortner (2003) te Aufderheide i Rodríguez-Martín (1998). U analiziranome uzorku uočeni su karijes, alveolarne bolesti, linearna hipoplazija zubne cakline, *cribra orbitalia*, periostitis, Schmorlovi defekti, koštane ozljede i tuberkuloza. Većina patoloških promjena izračunata je i prezentirana po elementu (npr. zub, alveola, kralježak), a ne po kosturu zbog različitoga stupnja očuvanosti koštanih ostataka. No, neke patologije poput linearne hipoplazije zubne cakline, perio-

sex and age at death, as well as recording pathological changes which occurred antemortem.

The age of children was determined based on changes which occur at growth and the ratio between deciduous and permanent teeth (Moorrees et al. 1963a; 1963b; Gustafson, Koch 1974; AlQahtani et al. 2009), the chronology of epiphyseal fusions with diaphyses, and the length of long bones diaphyses (Maresh 1970; Scheuer, Black 2000; Schaefer et al. 2009). The age of adults was determined based on pubic symphysis (Brooks, Suchey 1990) and articular surface morphology (Lovejoy et al. 1985; Buckberry, Chamberlain 2002), degree of ectocranial suture closure (Meindl, Lovejoy 1985), morphologic changes on the sternal end of the body of the ribs (Işcan et al. 1984; 1985), and the wear of the occlusal surface of the teeth (Brothwell 1981; Lovejoy 1985). Children were divided into three age groups: 'younger children' (0 to 5 years old), 'older children' (6 to 11 years old), and 'adolescents' (12 to 17 years old). The sex of the adults was determined based on the macroscopic examination focusing on the differences in pelvic and cranial morphology between adult men and women (Krogman, Işcan 1986; Buikstra, Ubelaker 1994; Bass 1995). Adult individuals whose sex could not be determined with certainty were labelled as 'probably men' and 'probably women'. The adult individuals labelled as 'probably men' and 'probably women' were joined with their respective sex groups, i.e. 'probably men' with men and 'probably women' with women.

All skeletal and dental remains were analysed for possible pathologic changes. Noticed changes were documented in detail according to the criteria described by Ortner (2003) and Aufderheide and Rodríguez-Martín (1998). The analysed assemblage revealed caries, alveolar diseases, linear enamel hypoplasia, *cribra orbitalia*, periostitis, Schmorl's nodes, bone injuries, and tuberculosis. Most pathologic changes were calculated and presented by the element (e.g., tooth, tooth socket, vertebra), and not by a specific skeleton due to the different degree of preservation of skeletal remains. However, some pathologies, such as linear enamel hypoplasia, periostitis, tuberculosis, and/or bone injuries, were calculated and presented by the person/skeleton.

Caries is a disease that is most recognizable by a hole in a tooth, which is the result of the progressive decalcification of enamel and dentine (White, Folkens 2005) caused by bacteria and solutes of the oral fluids (Aufderheide, Rodríguez-Martín 1998). The presence of caries was diagnosed macroscopically, under strong illumination, with the help of a dental probe. Caries was classified into four categories according to parameters proposed by Metress and Conway (1975).

Alveolar diseases include antemortem tooth loss and abscess. Antemortem tooth loss is one of the indicators of health in archaeological populations. Various factors contribute to it: caries and periodontal disease, but also purposeful teeth extraction for therapeutic or cosmetic, i.e. ritual purposes (Freeth 2000; Roberts, Manchester 2005). Teeth loss can be noticed by the healing of dental alveolar ridges and/or new bone formation in the alveolus (Roberts,

stitisa, tuberkuloze i/ ili koštanih ozljeda su izračunate i prezentirane po osobi/kosturu.

Karijes je bolest koja se najlakše prepoznaje kao otvor u zubu koji je rezultat progresivne dekalifikacije cakline i dentina (White, Folkens 2005) prouzročene bakterijama i otopinama iz oralnih tekućina (Aufderheide, Rodríguez-Martín 1998). Prisustvo karijesa dijagnosticirano je makroskopski, pod snažnim osvjetljenjem, s pomoću dentalne sonde. Karijes je klasificiran u četiri kategorije prema parametrima koje su predložili Metress i Conway (1975).

Alveolarne bolesti uključuju zaživotni gubitak zubi te apsces. Zaživotni gubitak zubi jedan je od pokazatelja zdravlja u arheološkim populacijama. Na njega utječu različiti čimbenici: karijes i periodontalne bolesti, ali i namjerno vađenje iz terapijskih ili pak kozmetičkih, odnosno ritualnih razloga (Freeth 2000; Roberts, Manchester 2005). Na čeljusti se gubitak zubi prepoznaje kao zarastanje rubova zubne alveole i/ili stvaranje nove kosti i zarašćivanje unutar same alveole (Roberts, Manchester 2005). Apsces je jedna vrsta periapikalnih lezija. Nastaje kao posljedica upale koja se razvija kada se zubna pulpa izloži patogenima zbog karijesa, istrošenosti ili pucanja zuba (Hillson 1996; Freeth 2000). Širenjem upale nastaje šupljina u alveolarnoj kosti u kojoj se nakuplja gnoj te, s vremenom, i otvor kroz koji se prazni.

Linearna hipoplazija zubne cakline javlja se u obliku vodoravnih linija na površini krune zuba. Takve deformacije predstavljaju defekte u dentalnome razvoju (Goodman, Rose 1990; White, Folkens 2005) i kao takve dobri su pokazatelji subadultnoga stresa (metabolički stres tijekom dužeg vremena i/ili stresan događaj koji ih je uzrokovao) (Aufderheide, Rodríguez-Martín 1998). Prisutnost hipoplazije zubne cakline analizirana je na sjekutićima i očnjacima objiju čeljusti.

Cribr orbitalia je još jedan pokazatelj subadultnoga stresa. Očituje se kao poroznost na gornjem rubu orbita (Lewis 2007). Ove promjene, osobito u njihovim aktivnim i najizraženijim oblicima, češće se susreću kod djece nego kod odraslih osoba (Ortner 2003; Lewis 2007). Budući da najizraženiji oblik lezije u pravilu nastaje tijekom ranoga djetinjstva, najčešće se veže uz različite vrste anemija i pothranjenost u tom razdoblju (Mensforth et al. 1978; Walker et al. 2009). Kao moguću uzročnicu također se navode rahitis i skorbut te zarazne i parazitske bolesti (Lewis 2007). Periostitis je nespecifična promjena u kosti koja je vidljiva na *periosteumu* – membrani koja prekriva vanjsku površinu kostiju, osim na zglobovima (White, Folkens 2005). Bilo kakva iritacija periosteuma može rezultirati stvaranjem novoga sloja kosti nad postojećim slojem, a to može biti uzrokovano ne samo infekcijom ili upalom, već i drugim faktorima poput trauma; stanje može biti akutno ili kronično (White, Folkens 2005). Prema Wheeleru (2012), učestalost ove patološke promjene može biti vezana uz čimbenike kao što su traume prilikom rođenja, metabolički poremećaji, hipervitaminoza A, leukemija i infantilna kortikalna hiperostoza. Prisutnost periostitisa može se koristiti kao pokazatelj razine zdravlja zajednice, no slika koju pruža je općenita i nepotpuna (Larsen 1997).

Manchester 2005). Abscess is one type of periapical lesions. It appears as a result of an infection when tooth pulp is exposed to pathogens caused by caries, wear, or tooth breaking (Hillson 1996; Freeth 2000). As the infection spreads, a cavity in the alveolar bone appears. It fills with puss, and in time a hole is created for the puss to discharge.

Linear enamel hypoplasia appears in a form of horizontal lines on the surface of a tooth crown. Such deformities are defects in dental development (Goodman, Rose 1990; White, Folkens 2005) and are good indicators of subadult stress (long-term metabolic stress, and/or a stressful event which caused it) (Aufderheide, Rodríguez-Martín 1998). Linear enamel hypoplasia was analysed on incisors and canines on both jaws.

Cribr orbitalia is another indicator of subadult stress. It manifests as porosity in the orbital roof (Lewis 2007). These changes, especially in their active and most acute form, are more common in children than in adults (Ortner 2003; Lewis 2007). Since the most acute lesions, as a rule, appear in early childhood, they are most commonly associated with anemia and malnutrition during that stage of life (Mensforth et al. 1978; Walker et al. 2009). Other possible causes are rickets, scurvy, and infectious and parasitic diseases (Lewis 2007). Periostitis is a non-specific change in the bone which is visible on the *periosteum* – a membrane that covers the outer surface of bones except in the joint area (White, Folkens 2005). Any irritation of the periosteum may result in new bone layer formation on the underlying bone, and this may be caused not only by infection or inflammation but also by other factors such as trauma; it can be acute or chronic (White, Folkens 2005). According to Wheeler (2012), the occurrence of this pathological change can be also associated with conditions like birth trauma, metabolic disorders, hypervitaminosis A, leukemia, and infantile cortical hyperostosis. The presence of periostitis can be used as an indicator of the health of a community, but it provides a general and incomplete picture (Larsen 1997).

Tuberculosis is an infectious disease caused by *Mycobacterium tuberculosis*. There are two possible ways of getting infected. One of them is via small droplets, i.e. via an infected person coughing and sneezing. People can also get infected through contact with an infected animal or through the consumption of food of animal origin (Robert 2012). Tuberculosis can be noticed on human skeletal remains from archaeological sites only if it affected the skeleton, which happens in less than 2% of all cases (Waldron 2009). In most cases, the disease occurs on the first lumbar vertebra, and as it progresses, it leads to the complete destruction of the vertebral body and the creation of angular kyphotic deformity, the so-called Pott's disease (Waldron 2009).

Schmorl's node is one type of herniation of the intervertebral disc. It appears when the pulpous part of the disc penetrates the cartilage and spreads up or down in the body of the vertebra, resulting in a shallow lesion, round or elongated in shape (Mann, Hunt 2005). Schmorl's nodes are relatively common. They tend to appear in the lower thoracic and lumbar vertebrae (Waldron 2009). They are linked to various causes. In older people, they are connected to

Tuberkuloza je zarazna bolest, a uzrokuje ju bakterija *Mycobacterium tuberculosis*. Moguća su dva načina zaraze. Jedan je prijenos kapljičnim putem, tj. kašljanjem i kihanjem, putem zaražene osobe. Drugi je oblik prijenosa kapljičnim putem preko zaražene životinje ili putem konzumacije zaraženih prehrambenih proizvoda životinjskoga podrijetla (Roberts 2012). Na ljudskome kosturnom materijalu s arheoloških nalazišta tuberkuloza se može uočiti samo u slučaju kada zahvati koštani sustav, što se događa u manje od 2 % slučajeva (Waldron 2009). U većini slučajeva bolest se javlja na prvome slabinskom kralješku, a napredovanjem bolesti dolazi do potpunoga uništenja tijela kralješka, što dovodi do stvaranja oštrokutne kifotične deformacije, tzv. Pottove grbe (Waldron 2009).

Schmorlov defekt je jedna od vrsta hernijacije intervertebralnoga diska. Nastaje kada pulpozni dio diska probije hrskavicu te se proširi gore ili dolje u tijelo kralješka, a rezultat je plitka lezija okrugloga ili izduženoga oblika (Mann, Hunt 2005). Učestalost Schmorlovih defekata je relativno velika, a najčešće se nalaze na donjim prsnim i slabinskim kralješcima (Waldron 2009). Njihov nastanak povezuje se s različitim uzročnicima. Kod starijih osoba povezuju se s degenerativnim promjenama intervertebralnoga diska. Kod mlađih osoba smatra se da na njihov nastanak mogu utjecati traume i zahtjevne fizičke aktivnosti, posebno u doba adolescencije (Mann, Hunt 2005).

Prijelom ili fraktura kosti nastaje kao rezultat utjecaja vanjske sile na kost koja dovodi do njezinoga potpunog ili djelomičnog loma. Tri glavna uzročnika lomova su akutna ozljeda, bolest i ponavljajući stres (Roberts, Manchester 2005). Nedugo nakon prijeloma kost počinje zarastati, no brzina zarastanja ovisi, između ostaloga, o vrsti frakture, njezinoj poziciji te dobi osobe (Aufderheide, Rodríguez-Martín 2003). U analiziranome uzorku prisustvo prijeloma ustanovljeno je makroskopskom analizom koja je uključivala prisustvo bilateralne asimetrije, kutnih deformiteta, koštanih kalusa te zacijeljenih depresijskih fraktura kao i trauma uzrokovanih tupim predmetima, tragova posjekotina i/ili ozljeda projektilom.

Demografija

Na nalazištu je istraženo ukupno 55 grobova, a svi ukopi su jednostruki. S obzirom da kosturni materijal iz dva groba (42 i 47) nije bio dostupan, za antropološku analizu su bili uzeti ostaci ukupno 53 osobe (tab. 1). Analizom je utvrđeno da je u uzorku prisutno 10 djece (18,9 %) te 43 odrasle osobe, od toga 13 žena (24,5 %) i 30 muškaraca (56,6 %) (sl. 3). Kod odraslih osoba odnos muškaraca i žena iznosi čak 2,3 : 1. Najveći broj djece, njih ukupno šest, nalazi se u srednjoj dobnoj skupini od 6 do 10 godina, dok se u najmlađoj dobnoj skupini nalazi samo jedno dijete (sl. 4). Gotovo polovica odraslih osoba (21) nalazi se u srednjoj dobnoj skupini, zatim slijede mlađe odrasle osobe (18), dok je najmanje odraslih osoba prisutno u najstarijoj dobnoj skupini (4). Prosječna doživljena starost svih odraslih osoba u analiziranome uzorku iznosi 38 godina: muškarci u prosjeku žive neznatno duže odnosu na žene (38,5 napram

degenerative changes to the spinal disc. In younger people, it is considered that they can be caused by traumas and strenuous physical activity, especially during adolescence (Mann, Hunt 2005).

Bone injury or fracture is the result of the external force influencing the bone, which leads to the complete or partial fracture of the bone. The three main causes of fractures are acute injury, disease, and recurrent stress (Roberts, Manchester 2005). Shortly after the fracture, the bone starts to heal, but the healing rate depends on the type of fracture, its position, and the age of the person, among other things (Aufderheide, Rodríguez-Martín 2003). In the analysed assemblage, the existence of fractures was established by macroscopic analysis that included bilateral asymmetry, angular deformities, the presence of bone calluses, and healed depression fractures, as well as blunt force traumas, cutting, and/or projectile injuries.

Demography

A total of 55 graves were excavated at the site, all of them single burials. Since skeletal material from two graves (42 and 47) was not available, the remains of 53 people (Tab. 1) were included in the anthropological analysis. The analysis ascertained that there are 10 children (18.9%) and 43 adult skeletons, 13 of which women (24.5%) and 30 men (56.6%) (Fig. 3). The ratio between adult men and women is 2.3 : 1. Most children, six of them, belong to the second age group, 6 to 10 years old, while there is only one child in the first age group (Fig. 4). Almost half of the adults (21) are in the middle-aged group, not as many are in the young adult group (18), while the lowest number of adults is old (4). The average age of all people in the analysed sample at the time of death is 38: men lived slightly longer than women (38.5 vs. 37.6 years).

Pathological changes

Carious lesions in Ivankovo assemblage were noticed only in adults and their prevalence is 14.7% (41/279). The percentage of prevalence of caries is slightly higher in men than in women: 16.3% (35/214) versus 9.2% (6/65). Alveolar diseases, just as carious lesions, were noticed only in adults, with 20% (96/479) of prevalence. Unlike caries, alveolar diseases were more common in women (24.6% or 35/142) than in men (18.1% or 61/337).

Indicators of subadult stress, linear enamel hypoplasia, and *cribra orbitalia* were noticed in several people from the assemblage. The occurrence of linear enamel hypoplasia in people whose teeth necessary for the analysis were preserved is 47% (8/17); two adult women (2/3 or 66.7%) and six adult men (6/14 or 42.9%). Unfortunately, none of the children were suitable for this type of analysis. The total frequency of *cribra orbitalia* in Ivankovo is 33.3% (6/18). All cases were healed. There is just one child's frontal bone with a visible lesion in the assemblage. Five out of 17 adults with preserved frontal bone show this pathological change (29.4%): only one woman (1/8 or 12.5%), while *cribra orbitalia* is much more common in men (4/9 or 44.4%).

Periosteal lesions occur in more than half of the people

Grob/Grave	Spol/Sex	Dob (godine)/Age (years)
1	žena/female	30–45
2	žena/female	35–45
3	muškarac/male	35–40
4	muškarac/male	30–40
5	muškarac/male	35–45
6	neodrediv (dijete)/indeterminate (child)	10–12
7	žena/female	30–40
8	muškarac/male	40–50
9	žena/female	40–50
10	muškarac/male	30–40
11	muškarac/male	30–35
12	vjerojatno žena/probably female	25–40
13	žena/female	30–35
14	muškarac/male	30–35
15	žena/female	50+
16	muškarac/male	30–40
17	muškarac/male	50+
18	muškarac/male	40–45
19	žena/female	30–45
20	neodrediv (dijete)/indeterminate (child)	5–7
21	vjerojatno muškarac/probably male	30–45
22	neodrediv (dijete)/indeterminate (child)	5–7
23	vjerojatno muškarac/probably male	30–45
24	muškarac/male	40–45
25	muškarac/male	50+
26	muškarac/male	20–30
27	neodrediv (dijete)/indeterminate (child)	6–7
28	muškarac/male	30–35
29	neodrediv (dijete)/indeterminate (child)	6–8
30	žena/female	30–35
31	vjerojatno muškarac/probably male	30–40
32	muškarac/male	35–40
33	žena/female	20–25
34	neodrediv (dijete)/indeterminate (child)	7–10
35	žena/female	30–40
36	muškarac/male	25–30
37	muškarac/male	35–40
38	muškarac/male	40–50
39	muškarac/male	25–35
40	neodrediv (dijete)/indeterminate (child)	8–10
41	muškarac/male	35–45
43	neodrediv (dijete)/indeterminate (child)	10–12
44	muškarac/male	30–35
45	neodrediv (dijete)/indeterminate (child)	4,5–5,5
46	muškarac/male	40–50
48	žena/female	30–40
49	muškarac/male	18–19
50	muškarac/male	45–50
51	muškarac/male	50+
52	muškarac/male	35–45
53	žena/female	30–40
54	muškarac/male	30–35
55	neodrediv (dijete)/indeterminate (child)	10–15

Tab. 1 Spolna i dobna distribucija analiziranih osoba po grobovima (izradio: T. Hajdu)

Tab. 1 Sex and age distribution of the analysed individuals divided by graves (made by: T. Hajdu)

37,6 godina).

Patološke promjene

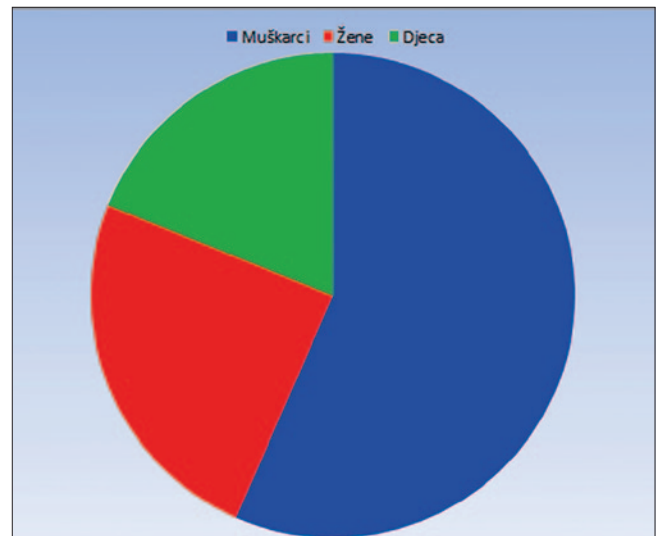
Kariozne lezije u uzorku iz Ivankova uočene su samo kod odraslih osoba i njihova učestalost iznosi 14,7 % (41/279). Postotak karijesa nešto je viši kod muškaraca nego žena te iznosi 16,3 % (35/214) u odnosu na 9,2 % (6/65). Kao i kariozne lezije, alveolarne bolesti uočene su samo kod odraslih osoba te njihova učestalost iznosi 20 % (96/479). Suprotno karijesu, alveolarne bolesti su češće kod žena (24,6 % ili 35/142) nego muškaraca (18,1 % ili 61/337).

Pokazatelji subadultnoga stresa, linearna hipoplazija zubne cakline i *cribra orbitalia* zabilježeni su kod više osoba iz analiziranoga uzorka. Učestalost hipoplazije zubne cakline kod osoba koje su imale sačuvane zube potrebne za analizu iznosi 47 % (8/17). Riječ je od dvije odrasle žene (2/3 ili 66,7 %) i šest odraslih muškaraca (6/14 ili 42,9 %). Na žalost, niti jedno dijete nije bilo pogodno za ovu vrstu analize. Ukupna učestalost *cribra orbitalia* u Ivankovu iznosi 33,3 % (6/18). Svi uočeni slučajevi prisutni su u zarasloj obliku. U uzorku se nalazi samo jedna dječja čeonna kost te je na njoj vidljiva lezija. Kod odraslih osoba pet od 17 individua sačuvanom čeonnom kosti pokazuje ovu patološku promjenu (29,4 %). Kod žena je prisutan samo jedan slučaj (1/8 ili 12,5 %), dok se *cribra orbitalia* kod muškaraca javlja mnogo češće (4/9 ili 44,4 %).

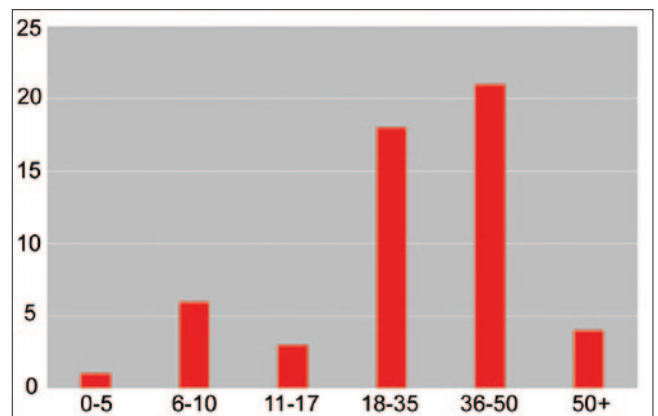
Periostealne lezije prisutne su kod više od polovice osoba čiji su kosturi bili dovoljno sačuvani za ovu vrstu analize (20/37 ili 54 %). Periostitis je zabilježen na ostacima djece i odraslih osoba oba spola. Kod djece prisutan je na jednoj četvrtini analiziranih kostura (2/8) i u oba slučaja je u zarasloj stanju. Učestalost kod odraslih osoba je visoka i iznosi 62 % (18/29). Viša učestalost zabilježena je kod muškaraca u odnosu na žene (68,2 % ili 15/22 naprama 42,9 % ili 3/7). Kod dva muškarca i jedne žene periostitis je prisutan u aktivnom stanju.

Schmorlovi defekti su uočeni su samo kod odraslih osoba: 18 od 25 (72 %) kostura sa sačuvanom kralježnicom pokazuje prisutnost ove patološke promjene. Kada se analizira sam broj zahvaćenih kralježaka, na 92 od ukupno analiziranih 297 (30,1 %) prisutni su Schmorlovi defekti; muškarci iskazuju puno veću učestalost u odnosu na žene (37,6 % ili 91/242) naprama (1,8 % ili 1/55).

Tuberkuloza je prisutna na kosturu muškarca starosti između 30 i 35 godina iz groba 14. Znakovi tuberkuloze najizraženiji su na području prsnih i slabinskih kralježaka. Na anteriornoj strani tijela 5. i 6. prsnog kralješka prisutan je zarasli upalni proces (porozitet i pojava novog sloja kosti). Na području od 7. prsnog do 3. slabinskog kralješka javlja se koštana ankiloza (srastanje) i destruktivne litičke lezije na tijelima kralježaka koje su rezultirale potpunim uništenjem tijela 10., 11. i 12. prsnog te 1. slabinskog kralješka što je dovelo do stvaranja oštrokutne kifotične deformacije (Pottova grba) (sl. 5). Lukovi kralježaka (od 7. prsnog do 3. slabinskog), uključujući zglobne plohe i spinozne nastavke, također su srasli (sekundarna ankiloza). Promjene konzistentne s tuberkulozom prisutne su i na rebrima: povećanje (proširenje) tijela rebra zabilježeno je na 7., 8. i 9. lijevom rebro, a prisutne su i destruktivne litičke lezije (apscesi) na sternalnom



Sl. 3 Distribucija pokojnika po spolu (izradio: T. Hajdu)
Fig. 3 Sex distribution of the deceased (made by: T. Hajdu)



Sl. 4 Distribucija pokojnika po dobnim skupinama (izradio: T. Hajdu)
Fig. 4 Age groups distribution of the deceased (made by: T. Hajdu)

whose skeletons were preserved well enough for this type of analysis (20/37 or 54%). Periostitis was noticed on the remains of children and adults of both sexes. It was found in one quarter of the children's skeletons (2/8) and in both cases it was healed. The frequency in adults was high: 62% (18/29). Higher frequency was noticed in men than in women (68.2% or 15/22 vs. 42.2% or 3/7). Periostitis was found in the active stage in one man and one woman.

Schmorl's nodes were noticed only in adults: 18 out of 25 (72%) of skeletons with preserved spine showed this type of pathologic change. When we consider the number of affected vertebrae, 92 out of 297 (30.1%) analysed vertebrae in total had Schmorl's nodes; they were much more frequent in men than in women (37.6% or 91/242) versus (1.8% or 1/55).

Tuberculosis was present on the skeleton of a man aged between 30 and 35 years from grave 14. Signs of tuberculo-



Sl. 5 Pottova grba nastala kao posljedica tuberkuloze (snimila: V. Vyroubal)

Fig. 5 Pott's disease as the consequence of tuberculosis (photo by: V. Vyroubal)

kraju 8. lijevog rebra. Slične promjene (aktivni periostitis i osteoplastične lezije) prisutne su na pleuralnim stranama od 1. do 11. lijevog rebra mlađeg muškarca pokopanog u grobu 49 – moguće da je ovdje riječ o još jednom slučaju tuberkuloze ili neke druge bolesti koja ostavlja slične tragove kao što je pleuritis ili jaka upala pluća.

U analiziranom uzorku koštane ozljede su prisutne kod šest odraslih osoba. U svim slučajevima riječ je o frakturama koje su nastale tijekom života osobe te su zarasle do trenutka smrti: 1) kod žene starosti 30 do 40 godina (grob 7) prisutna je loše zarasla fraktura lijeve palčane kosti koja se očituje po posteriornom pomaku, koštanom trnu, blagom zaraslom periostitisu i skraćenju kosti za 30 mm; 2) kod žene starosti iznad 50 godina (grob 15) prisutna je fraktura desne palčane kosti s koštanim trnom i blagim zaraslim periostitisom; 3) muškarac starosti 35 do 45 godina (grob 32) ima frakturu lijeve ključne kosti koja se očituje po posteriornom pomaku i preklapu kosti; 4) na kosturu muškarca starosti 40 do 50 godina (grob 38) prisutna je dobro zarasla fraktura desne bedrene kosti koja se očituje po blagom lateralnom pomaku; 5) na lijevoj strani čeonu kosti muškarca starosti 28 do 35 godina (grob 44) uočena je depresijska fraktura ovalnog oblika i dimenzija 12 x 10 mm; 6) na tjemenju kosti mlađeg muškarca (grob 49) prisutna je depresijska fraktura ovalnog oblika dimenzija je 17 x 12 mm.

Rasprava

Analiza spolne i dobne distribucije osoba pokopanih na groblju u Ivankovu pokazala je kako su na njemu pokopane osobe oba spola i svih dobnih skupina. Ipak, kod populacije iz Ivankova uočljiva su dva aspekta: 1) gotovo potpuno odsustvo djece iz najmlađe dobne skupine; 2) mnogo veći broj muškaraca u odnosu na žene. Što se tiče odsustva najmlađe djece, moguće objašnjenje možda se može potražiti u crkvenim pravilima prema kojima se nekrštena djeca ne mogu pokopavati na posvećenome mjestu, tj. groblju (za više detalja vidi: Tkalčec 2016). Naime, „prema srednjove-

sis were most pronounced around thoracic and lumbar vertebrae. On the anterior side of the body of the fifth and sixth thoracic vertebrae, there is a healed inflammation (porosity and the emergence of a new layer of bone). In the area from the seventh thoracic vertebra to the third lumbar vertebra there are bone ankylosis (fusion) and destructive lytic lesions on vertebrae bodies, which resulted in the complete destruction of the body of the tenth, eleventh and twelfth thoracic vertebrae and the first lumbar vertebra, which led to the creation of angular kyphotic deformity (Pott's disease) (Fig. 5). Vertebral arches (from the seventh thoracic to the third lumbar vertebrae), including the articular surfaces and spinous processes, have also fused (secondary ankylosis). Changes consistent with tuberculosis are also present on the ribs: augmentation (expansion) of the bodies of the ribs was documented on the seventh, eighth, and ninth left ribs, and there are also destructive lytic lesions (abscesses) on the sternal end of the eighth left rib. Similar changes (active periostitis and osteoblastic lesions) were present on pleural sides from the first to the eleventh left rib of a young man buried in grave 49 – it is possible that this was another case of tuberculosis or some other disease with similar consequences, such as pleuritis or a serious case of pneumonia.

Bone injuries were present in six adults from this assemblage. All of them were fractures which occurred during their lifetime and healed before their death: 1) a woman between 30 and 40 years of age (grave 7) exhibited an improperly healed fracture of the left radius, which manifested in posterior shift, exostosis, a slightly healed periostitis and a bone shortened by 30 mm; 2) a woman older than 50 years of age (grave 15) exhibited a fracture of the right radius with exostosis and slightly healed periostitis; 3) a man between 35 and 45 years of age (grave 32) exhibited a fracture of the left clavicle, which was manifested in posterior shift and bone flap; 4) a skeleton of a man between 40 and 50 years of age (grave 38) exhibited a properly healed fracture of the right femur which was manifested in a slight lateral shift; 5) on the left side of the frontal bone of a man between 28 and 35 years of age (grave 44), an oval shaped depression fracture with the dimension 12 x 10 mm was noticed; 6) a parietal bone of a younger man (grave 49) exhibited an oval shaped depression with the dimensions 17 x 12 mm.

Discussion

The analysis of the sex and age distribution of the people buried at the Ivankovo cemetery showed that people of both sexes and all age groups were buried there. Nevertheless, two aspects are evident in the population from Ivankovo: 1) almost complete absence of children from the youngest age group; 2) significantly higher number of men than women. A possible answer to the absence of the youngest children can be found in Church rules according to which unbaptized children cannot be buried at a sacred site, i.e. cemetery (for more see Tkalčec 2016). "The medieval texts and Cristian beliefs considered the identity of unbaptized children very problematic – in the theological sense they were outcasts" (Tkalčec 2016: 172). Accordingly, it is possible that the youngest, unbaptized children from Ivankovo were

kovnim tekstovima i kršćanskome vjerovanju identitet nekrštene djece je vrlo problematičan – u teološkome smislu ona su bila izopćeničnici“ (Tkalčec 2016: 172). U skladu s tim tumačenjem moguće je da su najmlađa, još nekrštena djeca iz Ivankova pokopavana van samoga groblja ili na posebnome prostoru unutar groblja koje još nije arheološki istraženo te stoga njihovi ostaci nisu prisutni u analiziranome uzorku. Kako su grobovi tako male djece često ukopavani vrlo plitko uz zid crkve, druga mogućnost je da su uništeni prigodom iskopa zemlje bagerom, bez prisustva arheologa. Naravno, ovo su samo dva od većega broja mogućih objašnjenja, ali za slučaj iz Ivankova ona zvuče dosta uvjerljivo. S druge strane, nesrazmjer u zastupljenosti muškaraca i žena u određenome koštanom uzorku često se objašnjava utjecajem faktora kao što su posebnosti u praksi ukopavanja u odnosu na spol i dob pokojnika i/ili diferencijalni stupanj sačuvanosti kostiju između spolova, ali i upotrebe različitih metoda određivanja spola i starosti u trenutku smrti u različitim koštanim uzorcima (Pinhasi, Bourbou 2007). Na žalost, za sada nije moguće sa sigurnošću utvrditi koji uzroci (ili kombinacija više njih) su odgovorni za spolni nesrazmjer u Ivankovu i jesu li (i u kojoj mjeri) neki od tih faktora ovdje odigrali ključnu ulogu.

Analiza dento-alveolarnih oboljenja pokazala je visoke učestalosti karijesa i alveolarnih bolesti u Ivankovu što sugerira loše oralno zdravlje lokalnoga stanovništva. No, slična situacija prisutna je na čitavome nizu srednjovjekovnih i ranonovovjekovnih nalazišta u kontinentalnoj Hrvatskoj, ali i široj regiji (za više detalja vidi: Novak et al. 2010). Osim lošega oralnog zdravlja, ove vrijednosti također ukazuju i na određenu vrstu prehrane. Naime, brojna paleodontološka istraživanja ukazuju na korelaciju visoke učestalosti karijesa (i drugih dento-alveolarnih patologija) i tipa prehrane koju odlikuje pojačana konzumacija ugljikohidrata, tj. način života temeljen na poljoprivredi i uzgoju žitarica (Šlaus et al. 2011). Sukladno tome, moguće je pretpostaviti da je većina stanovnika Ivankova svoju prehranu bazirala na žitaricama uz tek povremenu konzumaciju proteina životinjskoga porijekla. O važnosti žitarica za prehranu ruralnoga stanovništva kontinentalne Hrvatske tijekom kasnoga srednjeg vijeka najbolje svjedoče tzv. urbari (pravni dokumenti koji su određivali odnos između feudalaca i kmetova). Vjerojatno najvažniji takav dokument je urbar pavlinskoga samostana u Strezi, datiran u 15. stoljeće, koji opisuje količinu i strukturu godišnjih davanja koja su seljaci bili obvezni davati svojim feudalnim gospodarima (Kolar Dimitrijević 2003). Navedeni urbar detaljno opisuje vrste hrane koja je bila konzumirana od pripadnika nižih društvenih slojeva tijekom kasnoga srednjeg vijeka na području kontinentalne Hrvatske. Proso je bila glavna kultura koja je činila osnovu svakodnevne prehrane jer se lako uzgaja, ima kratko razdoblje vegetacije i može se sijati u suhom i pjeskovitom tlu. Pšenica se smatrala najvažnijom žitaricom za pečenje kruha, a heljda i sirak također su imali vrlo važnu ulogu u svakodnevnoj prehrani. Pored ovih usjeva, raž i ječam su se također uzgajali u velikim količinama. S druge strane, svinjetina, perad i riba bili su najčešći izvor proteina za hrvatskih seljake tijekom ovoga

buried outside of the cemetery or in a special area within the cemetery that still has not been excavated, and because of that their remains are not in the analysed assemblage. Since the graves of such small children were dug very shallowly next to the wall of the church, the other possibility is that they were destroyed by an excavating machine, with no archaeologists around. Of course, these are only two out of multiple possible explanations, but they sound quite convincing for Ivankovo. On the other hand, the disparity between the number of men and women in a certain bone assemblage is usually explained by other factors, such as specificities in burials of people of different sex and age and various degree of bone preservation between the sexes, but also by the use of different methods of determining sex and age in the time of death in different bone samples (Pinhasi, Bourbou 2007). Unfortunately, it is not possible to say which causes (or a combination of several causes) were responsible for the sex disparity and whether (and to what degree) some of the factors played a crucial role.

The analysis of dentoalveolar diseases showed a high frequency of caries and alveolar diseases in Ivankovo, which suggests poor oral health of the local population. However, a similar situation is present in a whole array of medieval and early modern sites in continental Croatia, but also in the region (for more see Novak et al. 2010). Besides the poor oral health, this data is also indicative of a certain type of diet. Numerous researches in paleodontology suggest that there is a correlation between high frequency of caries (and other dentoalveolar pathologies) and the type of diet with frequent consummation of carbohydrates, i.e. the way of life based on agriculture and growing crops (Šlaus et al. 2011). Accordingly, it is safe to assume that the diet of most inhabitants of Ivankovo was based on grain, with the occasional consummation of animal protein. The importance of grains for the diet of the rural population of continental Croatia during the late Middle Ages is described in the so-called *urbaria* (legal documents which specified the relationship between feudal lords and serfs). Probably the most important of them is *urbarium* from the Pauline monastery in Streza, dated to the 15th century, which describes the amount and structure of levies peasants had to provide for their feudal lords (Kolar Dimitrijević 2003). The *urbarium* lists in detail the types of food consumed by those belonging to the lower social classes during the late Middle Ages in continental Croatia. Millet was the most important crop and was the base of everyday diet because it is easy to grow, it has a short vegetation period, and can be sown in dry and sandy ground. Wheat was considered the most important grain for making bread, and buckwheat and sorghum were also very important in everyday diet. Besides those crops, rye and barley were also cultivated in large amounts. On the other hand, pork, poultry, and fish were the most common sources of protein for Croatian peasants in this period (Adamček 1980).

The analysis of indicators of subadult stress and infectious diseases point to the high rates of occurrences of physiologic stress indicators, such as *cribra orbitalia* and linear enamel hypoplasia, but also periostitis, which testifies to

razdoblja (Adamček 1980).

Analiza pokazatelja subadultnoga stresa i zaraznih bolesti ukazuje na visoke stope učestalosti pokazatelja fiziološkoga stresa kao što su *cribra orbitalia* i linearna hipoplazija zubne cakline, ali i periostitisa, što svjedoči o generalno lošem zdravstvenom stanju za većinu stanovništva ovoga mjesta. Slični rezultati zabilježeni su i na drugim istovremenim nalazištima s ovoga područja (za više detalja vidi: Novak et al. 2009). Epizode fiziološkoga stresa kod djece, ali i odraslih osoba koje su rezultirale lošim zdravljem vjerojatno su rezultat sinergističkoga djelovanja različitih bioloških i sociokulturnih faktora kao što su neadekvatna ishrana, razne bolesti, anemija, parazitske infekcije i sl. Kada je riječ o lošem zdravstvenom stanju i zaraznim bolestima, u uzorku iz Ivankova zabilježen je i jedan slučaj tuberkuloze kojega su detaljnije obradili Krznar i Novak (2013). Na osnovi arheoloških nalaza i stratigrafskoga odnosa s drugim grobovima, ovaj slučaj okvirno se može datirati u 16. stoljeće (Krznar, Novak 2013). Prisutnost tuberkuloze u Ivankovu tijekom toga razdoblja uklapa se u geografski i kronološki okvir nastanka i širenja ove bolesti na području Karpatske kotline. S obzirom na gospodarski i društveni karakter Ivankova u tome razdoblju, moguće je da je neposredni uzročnik zaraze tuberkulozom kod analizirane osobe podvrsta *Mycobacterium bovis* koja se prenosi sa životinje na čovjeka konzumacijom termički neobrađenoga mesa i mlijeka (Krznar, Novak 2013).

Pojava velikoga broja Schmorlovih defekata u Ivankovu može se povezati uz kronična mehanička opterećenja kralježnice kao što je dugotrajni teški fizički rad (za više detalja vidi: Novak, Šlaus 2011). Takva slika sugerira da su stanovnici ovoga područja morali ulagati mnogo fizičkoga napora u obavljanju svakodnevnih aktivnosti što je rezultiralo fizičkim stresom i brojnim ozljedama kralježnice.

Koštane ozljede u Ivankovu zabilježene su kod šest odraslih osoba, no s obzirom na djelomičnu sačuvanost većine kostura, broj ozljeda zacijelo je bio nešto veći. Sve uočene frakture u Ivankovu nastale su tijekom života, tj. zarasle su, što ukazuje da nisu imale neposrednu vezu s načinom smrti analiziranih osoba. Raspored na tijelu i morfologija samih ozljeda sugeriraju da su nastale kao posljedica nesretnih slučajeva, najvjerojatnije povezanih sa svakodnevnim aktivnostima unutar zajednice kao što su rad u polju ili sa stokom, rad u kući, i sl. Na primjer, ozljede distalnoga dijela palčane kosti najčešće se povezuju s padom na ispruženu ruku (Lovell 1997). Nadalje, frakture ključnih kostiju, kakva je zabilježena kod jedne osobe iz Ivankova, najčešće su uzrokovane padom na rame, no također mogu nastati i kao rezultat pada na ispruženu ruku (Lovell 1997). Uz to, Judd i Roberts (1999) sugeriraju da su padovi s konja (kao i ozljede nastale uslijed bliskoga rada s velikim domaćim životinjama) važni faktori nastanka takvih fraktura u arheološkome kontekstu. Frakture dijafiza bedrenih kostiju najčešće su posljedica jake direktne i indirektna traume, a u ruralnim populacijama povezuju se s padom s visine (Judd, Roberts 1999), ali također i jahanjem, tj. padom s konja (Anđelinović et al. 2015). Jedini potencijalni koštani indikator nasilja u ovoj zajednici su depresijske frakture zabilježene na čeonoj i tjemennoj kosti dva odrasla muškarca. No, potpuno odsustvo perimor-

the generally poor health conditions for most people in this village. Similar results were noticed in other contemporary sites from this area (for more see Novak et al. 2009). Episodes of physiological stress in children, but also adults, which resulted in poor health were probably the consequence of the synergistic effect of different biological and sociocultural factors, such as inadequate diet, various diseases, anemia, parasitic infections, and other. Therefore, when poor health conditions and infectious diseases are concerned, one case of tuberculosis was found in Ivankovo assemblage, which was analysed in more detail by Krznar and Novak (2013). Based on archaeological finds and stratigraphic relationships with other graves, this case can roughly be dated to the 16th century (Krznar, Novak 2013). The presence of tuberculosis in Ivankovo in this period fits in with the geographical and chronological framework of the outbreak and spread of this disease in the Carpathian Basin. Considering the economic and social importance of Ivankovo in this period, it is possible that the direct cause of the infection in the analysed individual was subspecies *Mycobacterium bovis*, which is transferred from animals to humans if they consume uncooked meat and milk (Krznar, Novak 2013).

High number of Schmorl's nodes in Ivankovo can be connected to chronic mechanical stress to the spine, such as permanent physical labour (for more see Novak, Šlaus 2011). That suggests that inhabitants of this village had to invest a lot of physical effort in carrying out their everyday activities, which resulted in physical stress and numerous injuries to the spine.

Bone injuries in Ivankovo were noticed in six adults, but since most skeletons were only partially preserved, the number of injuries was probably higher. All detected fractures from Ivankovo occurred antemortem, i.e. they healed, which indicates that they were not directly linked to the manner of deaths of the analysed individuals. The layout on the body and the morphology of injuries suggest that they were consequences of accidents, most likely linked to everyday activities in the community, such as working in the field or with cattle, in the house, or other. For instance, injuries of the distal part of the radius are usually connected to falling on an extended arm (Lovell 1997). Furthermore, fractures of clavicles, such as the one detected in an individual from Ivankovo, are most commonly caused by falling on one's shoulder, but can also be the result of falling on an extended arm (Lovell 1997); besides that, Judd and Roberts (1999) suggest that falling off a horse (as well as injuries which occur while working closely with large domestic animals) are important factors in such fracturing of bones in the archaeological context. Diaphyseal femur fractures are most frequently consequences of hard direct and indirect traumas, and in rural populations, they are linked to falling from high places (Judd, Roberts 1999), but also with horse-riding, i.e. falling off a horse (Anđelinović et al. 2015). The only possible bone indicators of violence in this community were depression fractures detected on the frontal and parietal bones of two adult men. But the complete absence of perimortem injuries, as well as injuries inflicted with weapons, such as cuts and/or stabs, suggests to the possibility

talnih ozljeda kao i ozljeda prouzročenih oružjem kao što su posjekotine i/ili ubodi ukazuje na mogućnost da su žitelji ove zajednice tijekom kasnoga srednjeg i ranoga novog vijeka bili izloženi niskoj stopi nasilja.

ZAKLJUČAK

Tijekom zaštitnih arheoloških iskopavanja provedenih uz sjeverni zid te apsidu crkve Rođenja sv. Ivana Krstitelja u Ivankovu pored Vinkovaca istraženo je ukupno 55 grobova. Riječ je o rimokatoličkome župnom groblju čija se uporaba, na osnovi stratigrafskih odnosa između grobova i crkve te pronađenih nalaza materijalne kulture, može datirati od kraja 13. pa sve do 18. stoljeća, tj. u kasni srednji i rani novi vijek. Većina grobova oštećena je naknadnim ukopima tako da su i sami kosturi relativno loše (parcijalno) sačuvani. Nalazi unutar grobova veoma su rijetki, a pronađeni su kod samo deset pokojnika (šest muškaraca i četiri žene). Uglavnom se radi o dijelovima nošnje (pojasna kopča, kopčice s kukom i ušicom, igle) te prstenju. Zanimljiv je nalaz noža koji nije uobičajen repertoar ženske nošnje te je u grob položen zbog svoje simbolične uloge. Bogatstvom nalaza (pojas od organskoga materijala ukrašen s 26 kalotastih aplika i s kvalitetno izrađenom i ukrašenom kopčom s pločicom, četiri prstena te ostacima vela) ističe se samo grob 33. Nešto viši socijalni status te pokojnice unutar ruralne zajednice ranonovovjekovnoga Ivankova potvrđuje i njen ukop u drvenome lijesu što je relativno rijedak običaj na ovome groblju. Međutim, antropološka analiza pokazala je da njen zdravstveni status nije bio bolji od ostatka populacije. Bioarheološka analiza koštanih ostataka pokazala je da se uzorak iz Ivankova sastoji od ukupno 53 osobe (10 djece, 13 žena i 30 muškaraca). Visoke učestalosti karijesa i zaživotnoga gubitka zuba sugeriraju loše oralno zdravlje, ali i prehranu temeljenu na ugljikohidratima, tj. žitaricama, što je sukladno i dostupnim pisanim izvorima. Visoke stope učestalosti pokazatelja fiziološkoga stresa (*cribra orbitalia* i linearna hipoplazija zubne cakline) i periostitisa te prisutnost zaraznih bolesti kao što je tuberkuloza svjedoči o generalno lošem zdravstvenom stanju za većinu stanovništva ovoga mjesta. Distribucija i morfologija koštanih ozljeda u uzorku iz Ivankova sugeriraju da su nastale kao posljedica nesretnih slučajeva, a ne kao posljedica namjernoga nasilja. Ovo je jedan od rijetkih radova u hrvatskoj (bio)arheologiji u kojem se izravno kompariraju arheološki i antropološki podaci s istoga lokaliteta. Ovakav pristup omogućio je rekonstrukciju egzaktnih podataka o različitim aspektima života i smrti ljudi koji su tijekom kasnoga srednjeg i ranoga novog vijeka nastavali prostor Slavonije i istočne Hrvatske. U tom kontekstu, nadamo se kako će ovaj rad dati poticaj za provedbu sličnih istraživanja u bliskoj budućnosti.

KATALOG GROBOVA I NALAZA

Grob 1 – Ukop i zapunu groba nije moguće ustanoviti. Veći dio oštećen je ukopom mlađega groba 3, a svojim ukopom grob 1 presjekao je grob 10. Kostu su položene na zdravicu. Od kostiju su ostale očuvane samo kosti potkoljenice i stopala, u dužini od 0,43 m.

Grob 2 – Ukop je djelomično očuvan. Kostur je ispružen na

that the inhabitants of this community during the late medieval and early modern period were exposed to a low rate of violence.

CONCLUSION

During salvage archaeological excavations conducted next to the northern wall and the apse of the church of the Birth of St. John the Baptist in Ivankovo near Vinkovci, 55 graves were excavated. It is a Roman Catholic parish cemetery, the use of which can be dated, based on stratigraphic relationships between graves and the church and material culture finds discovered, to the period from the end of the 13th all the way to the 18th century, i.e. to the late Middle Ages and the early modern period. Most graves were damaged by later burials and the skeletons themselves were also poorly (partially) preserved. The finds within graves were very rare; they were found with only ten individuals (six men and four women). The finds were mostly parts of costumes (belt buckles, hook-and-eye fasteners, pins) and rings. An interesting find is a knife which is not a common part of a woman's costume and was placed in the grave for its symbolic role. The only grave that stands out with an abundance of finds (a belt made of organic material decorated with 26 calotte-shaped appliques and with a decorated high-quality buckle with a plate, four rings, and the remains of a veil) is grave 33. A somewhat higher social status of that deceased woman within the rural community of the early modern Ivankovo is confirmed by her burial in a wooden coffin, which was a relatively rare custom at this cemetery. However, the anthropological analysis showed that she was not healthier than the rest of the population. Bioarchaeological analysis of skeletal remains showed that there were 53 people in total in Ivankovo assemblage (10 children, 13 women, and 30 men). High frequency of caries and antemortem loss of teeth suggest poor oral health, but also a diet based on carbohydrates, i.e. grains, which corresponds with available written sources. High rates of prevalence of physiological stress (*cribra orbitalia* and linear enamel hypoplasia) and periostitis, as well as the presence of infectious diseases such as tuberculosis, testifies to the poor health conditions for most inhabitants of this village. Distribution and morphology of bone injuries in Ivankovo assemblage suggest they were results of accidents and not deliberate violence. This is one of the rare papers in Croatian (bio)archaeology in which archaeological and anthropological data from the same site were directly compared. This approach enabled the reconstruction of exact data about different aspects of life and death of people who inhabited Slavonia and eastern Croatia during the late Middle Ages and early modern period. In that context, we hope that this paper will give incentives for conducting similar research in the near future.

CATALOGUE OF GRAVE AND FINDS

Grave 1 – Grave pit and grave fill cannot be determined. Most of the grave pit was damaged by a later grave 3 grave pit, while grave 1 cut the grave pit of grave 10. Bones were put in sterile soil. Only tibia and foot bones were preserved, and 0.43 m long.

Grave 2 – Grave pit is partly preserved. Skeleton is in a supine, extended position, and was put on a plank which is preserved in traces; the face and tibiae are missing.

leđima i položen na dasku koja je očuvana u tragovima; nedostaju kosti potkoljenica i kosti lica. Desna podlaktica je na trbuhu, a lijeva na prsima. Dužina očuvanoga dijela iznosi 1,16 m. Ukop je djelomično položen na stariji grob 14.

Nalazi: na prstu lijeve ruke pronađen je brončani prsten pečatnjak, a ispod vrata brončana igla.

1. Prsten pečatnjak (T. 1: 1) – slitina bakra, lijevan, jednodijelni, obruč je s unutarnje strane ravan, a vanjska strana je lagano zaobljena, širi se prema pločici; na vanjskoj strani glave nalazi se ukras u obliku loše izvedene cik-cak linije; pločica elipsoidnoga oblika ukrašena je stiliziranim vegetabilnim motivom; visina: 22,3 mm, širina: 20,6 mm; obruč – širina: 6,5 mm, debljina: 1,8 mm; pločica: 15,7 x 11,6 mm, težina: 8,9 g;
2. Iгла (T. 1: 2) – slitina bakra, okrugloga presjeka, slomljena, nedostaju vrh i glava igle; na igli su pronađeni mineralizirani tragovi kože; dužina: 39,99 mm, promjer žice: 1,2 mm, težina: 0,2 g.

Grob 3 – Ukop groba je pravokutnoga oblika sa zaobljenim uglovima. Sa sjeverne strane presječen je ukopom za gromobran. Svojim ukopom presjekao je grob 1. Kostu su dobro očuvane. Kostur je ispružen na leđima, a dužina *in situ* mu iznosi 1,67 m. Desna podlaktica je ispružena uz tijelo, a lijeva položena na zdjelicu.

Grob 4 – Ukop groba je pravokutnoga oblika sa zaobljenim uglovima, djelomično očuvan na zapadnoj strani. Veoma loše očuvan kostur ispružen je na leđima. Očuvane su zdjelica, križna kost, donja čeljust, lijeva lakatna kost te nekoliko kralježaka. Položen je na grob 5.

Grob 5 – Ukop groba je pravokutnoga oblika sa zaobljenim uglovima. Nalazi se ispod groba 4, a u njegovome produžetku nalazi se grob 6 koji mu je presjekao istočni dio. Grob je najstariji u ovoj skupini grobova. Kostur je ispružen na leđima, a očuvan je samo gornji dio tijela.

Grob 6 – Ukop groba je pravokutnoga oblika sa zaobljenim uglovima. Presjekao je grob 5. Kostur je ispružen na leđima i relativno loše očuvan. Nedostaju mu lubanja i kosti stopala. Dužina očuvanoga dijela kostura iznosi 1,07 m.

Grob 7 – Ukop i zapunu groba nije moguće ustanoviti. Djelomično očuvan grob od sredine na niže presječen kontraforom i šahtom te plinskom instalacijom. Ukopan je u zdravicu. Loše očuvan kostur ispružen je na leđima. Obje podlaktice su na trbuhu. Dužina očuvanoga dijela kostura iznosi 0,60 m.

Grob 8 – Ukop groba je pravokutnoga oblika sa zaobljenim uglovima. Presjekao je grob 11, a jugoistočni ugao presječen mu je grobom 9. Kostur je ispružen na leđima, loše očuvan. Desna podlaktica je na trbuhu, a lijeva na zdjelici. Dužina očuvanoga dijela kostura iznosi 1,63 m.

Grob 9 – Ukop i zapunu groba nije moguće ustanoviti. Kostur je vrlo loše očuvan, samo dio lubanje i donja čeljust.

Nalazi: između lubanje i donje čeljusti pronađena je igla (T. 1: 3) – bakrena slitina, okrugloga presjeka, s ovalnom glavom naknadno pričvršćenom na iglu; po sredini glave nalazi se plitak vodoravni urez; na igli su otkriveni

Right forearm is placed on the stomach, left on the chest. The length of the preserved part of the skeleton is 1.16 m. Burial pit is partly placed on an earlier grave, grave 14.

Finds: a bronze signet ring was found on a finger on the left hand and a bronze pin beneath the neck.

1. Signet ring (Pl. 1: 1) – copper alloy, cast, in one-piece, hoop is straight on the inside and slightly rounded on the outside, widens towards the plate, on the outside of the head it has a decoration in the shape of a poorly done zigzag line, ellipsoid formed plate is decorated with stylized plant motif; height: 22.3 mm, width: 20.6 mm; hoop – width: 6.5 mm, thickness: 1.8 mm; plate: 15.7 x 11.6 mm, weight: 8.9 g;
2. Pin (Pl. 1: 2) – copper alloy, circular cross-section, broken, top and head of the pin missing, traces of mineralized leather found on the pin; length: 39.99 mm, wire diameter: 1.2 mm, weight: 0.2 g.

Grave 3 – Grave pit is rectangular in shape with rounded edges. A lightning rod dig cut its northern side. Grave pit truncated grave 1. Bones are well preserved. Skeleton is in a supine position, and *in situ* length is 1.67 m. Right forearm is extended next to the body, left is on the pelvis.

Grave 4 – Grave pit is rectangular in shape with rounded edges, partly preserved on the western side. Very poorly preserved skeleton is in a supine, extended position. Pelvis, sacrum, mandible, left elbow bone, and a couple of vertebrae were preserved. It was placed on grave 5.

Grave 5 – Grave pit is rectangular in shape with rounded edges. It was placed below grave 4, and in its extension there is grave 6 which intersected its eastern part. This is the earliest grave in this group. Skeleton is in a supine, extended position, only upper section of the body is preserved.

Grave 6 – Grave pit is rectangular in shape with rounded edges. It truncated grave 5. Skeleton is in a supine, extended position and relatively poorly preserved. Skull and feet bones are missing. Length of the preserved section of the skeleton is 1.07 m.

Grave 7 – Grave pit and grave fill cannot be determined. Partly preserved grave which is cut from the middle to the east by a buttress, manhole, and gas piping. Buried in sterile soil. Poorly preserved skeleton is in a supine, extended position. Both forearms are on the stomach. Length of preserved section of the skeleton is 0.60 m.

Grave 8 – Grave pit is rectangular in shape with rounded edges. It truncated grave 11, while its south-eastern corner is truncated by grave 9. Skeleton is in a supine, extended position, poorly preserved. Right forearm is on the stomach, left on the pelvis. Length of the preserved section of the skeleton is 1.63 m.

Grave 9 – Grave pit and grave fill cannot be determined. Skeleton is very poorly preserved, only part of the skull and mandible remain.

Finds: a pin (Pl. 1: 3) was found between the skull and mandible – copper alloy, circular cross-section, with oval head which was subsequently attached to the pin, there is a shallow horizontal cut in the middle of the head,

ostaci lanenih vlakana; dužina: 64,5 mm, promjer žice: 1,3 mm, promjer glave: 4 mm, visina glave: 3,3 mm, težina: 0,7 g.

Grob 10 – Ukop i zapunu groba nije moguće ustanoviti. Kostri potkoljenica položene su na zdravicu. Ostatak groba je presječen ukopom groba 1. Dužina očuvanoga dijela kostura iznosi 0,46 m.

Grob 11 – Ukop groba je pravokutnoga oblika sa zaobljenim uglovima, orijentacije sjeverozapad – jugoistok. Ukopan je u zdravicu. Kostur je vrlo dobro očuvan. Nedostaje samo lubanja koja je presječena grobom 8. Ispružen je na leđima. Desna podlaktica je na trbuhu, a lijeva na zdjelici. Dužina očuvanoga dijela kostura iznosi 1,6 m.

Grob 12 – Očuvan je samo sjeveroistočni dio ukopa. Ostatak groba uništen je prilikom nadogradnje crkve. Pronađene su samo kosti lijevoga stopala.

Grob 13 – Ukop groba je pravokutnoga oblika sa zaobljenim uglovima. Sjeveroistočni dio groba nalazi se izvan sjevernoga ruba sonde. Kostur je ispružen na leđima i relativno loše očuvan. Desna podlaktica je na zdjelici, a lijeva na trbuhu. Dužina očuvanoga dijela kostura iznosi 1,32 m.

Grob 14 – Ukop i zapunu groba nije moguće ustanoviti. Kostur je ispružen na leđima. Lubanja je presječena instalacijom za naftu, a desna donja strana tijela ukopom groba 2. Lijeva podlaktica je na zdjelici. Dužina očuvanoga dijela kostura iznosi 0,92 m.

Nalazi: na lijevoj strani trupa pronađena je dvopetljava kopča s kukom i ušicom (T. 1: 4) – bakrena slitina, udvojena i presavinuta žica u obliku kukice te ušica od žice savinute u obliku omega, kuka – dužina: 11,8 mm, širina: 9,2 mm; ušica – dužina: 11,2 mm, širina: 8,7 mm, težina para: 0,4 g.

Grob 15 – Ukop i zapunu groba nije moguće ustanoviti. Leži na starijem grobu 19. Kostur je ispružen na leđa. Kostri su relativno loše očuvane; nedostaje dio lubanje te stopala. Podlaktice su položene na zdjelici. Dužina očuvanoga dijela kostura iznosi 1,57 m.

Grob 16 – Ukop i zapunu groba nije moguće ustanoviti. Leži na starijem grobu 18. Jako oštećen kostur ispružen je na leđima. Nedostaju kosti glave, ramenoga obruča te potkoljenica i stopala. Podlaktice su položene na zdjelicu. Dužina očuvanoga dijela kostura iznosi 0,7 m.

Nalazi: na prstu lijeve ruke pronađen je prsten u obliku jednostavne karike (T. 1: 5) – jednostavan lijevani zatvoren prsten, bakrena slitina, trakastoga presjeka; promjer: 20,1 mm, širina: 4,6 mm, debljina: 1 mm, težina: 1,5 g.

Grob 17 – Ukop groba je pravokutnoga oblika sa zaobljenim uglovima. Dužina rake iznosi 2,25 m. Na grob je u sjeverozapadnome dijelu sjeo šaht za naftu, a svojim ukopom on je presjekao grob 19. Dosta oštećen kostur ispružen je na leđima. Desna podlaktica nalazi se na zdjelici. Dužina očuvanoga dijela kostura iznosi 1,51 m.

Nalazi: s unutarnje strane lijevoga koljena nađen je željezni čavao, a na pojasu željezna pojasna kopča (T. 1: 6) – jednodijelna kopča s D okvirom i pomičnim trnom, nepravilnoga oblika; okvir je četvrtastoga presjeka,

traces of flax fibres were discovered on the pin; length: 64.5 mm, wire diameter: 1.3 mm, head diameter: 4 mm, head height: 3.3 mm, weight: 0.7 g.

Grave 10 – Grave pit and grave fill cannot be determined. Tibiae were placed in sterile ground. The rest of the grave was truncated by grave 1. Length of the preserved section of the skeleton is 0.46 m.

Grave 11 – Grave pit is rectangular in shape with rounded edges aligned NW - SE. Burial was in sterile soil. Skeleton is very well preserved. Only the skull, which was truncated by grave 8, is missing. It is in a supine, extended position. Right forearm is on the stomach, left on the pelvis. Length of preserved skeleton is 1.6 m.

Grave 12 – Only north-eastern section of the pit is preserved. The rest of the grave was destroyed by an addition to the church. Only bones of the left foot were found.

Grave 13 – Grave pit is rectangular in shape with rounded edges. North-eastern part of the grave is outside of the northern section of the trench. Skeleton is in a supine, extended position, and relatively poorly preserved. Right forearm is on the pelvis and left on the stomach. Length of the preserved section is 1.32 m.

Grave 14 – Grave pit and grave fill cannot be determined. Skeleton is in a supine, extended position. Skull is truncated by oil piping and right underside of the body by grave 2. Left forearm is on the pelvis. Length of the preserved section of the skeleton is 0.92 m.

Finds: a two-part hook-and-eye fastener was discovered on the left side of the torso (Pl. 1: 4) – copper alloy, double-looped clasp in the shape of a hook and an eye bent into omega; hook – length: 11.8 mm, width: 9.2 mm; eye – length: 11.2 mm, width: 8.7 mm, weight of the pair: 0.4 g.

Grave 15 – Grave pit and grave fill cannot be determined. Placed on earlier grave 19. Skeleton is in a supine, extended position. Bones are relatively poorly preserved; a part of the skull and feet are missing. Forearms are placed on the pelvis. Length of the preserved section of the skeleton is 1.57 m.

Grave 16 – Grave pit and grave fill cannot be determined. Placed on earlier grave 18. Badly damaged skeleton is in a supine, extended position. Bones of the head, shoulders, tibiae, and feet are missing. Forearms are placed on the pelvis. Length of the preserved section of the skeleton is 0.7 m.

Finds: ring in the shape of a simple hoop was discovered on a finger of the left hand (Pl. 1: 5) – simple, cast, closed-hoop ring, copper alloy, with banded section; diameter: 20.1 mm, width: 4.6 mm, thickness: 1 mm, weight: 1.5 g.

Grave 17 – Grave pit is rectangular in shape with rounded edges. The pit is 2.25 m long. In the northwestern part of the grave an oil shaft was placed intersecting a grave 19. Severely damaged skeleton is in a supine, extended position. Right forearm is placed on the pelvis. Length of the preserved section of the skeleton is 1.51 m.

Finds: iron nail was discovered on the inside of the left knee, while an iron belt buckle was found on the waist (Pl. 1: 6) – single looped buckle with D-shaped frame and a tongue, irregularly shaped, the frame has rectangular cross-section, tongue base is in the shape of a band,

baza trna trakasto raskucana, trn prelazi preko okvira, vrh trna je šiljat; željezo, okvir – dužina: 24,7 mm, visina: 30,6 mm; trn – dužina: 31,6 mm, širina baze: 5,46 mm, težina: 6,9 g.

Grob 18 – Ukop groba je pravokutnoga oblika sa zaobljenim uglovima, očuvanih dimenzija 1,32 x 0,45 m. Grob je ukopan u zdravicu, a leži ispod groba 16. Lijevom stranom ulazi u sjeverni profil iskopa, a ispod zdjelice presječen je recentnijim ukopom. Dosta loše očuvani kostur ispružen je na leđima. Desna podlaktica je na zdjelici, a lijeva na trbuhu. Dužina očuvanoga dijela kostura iznosi 0,94 m.

Grob 19 – Ukop i zapunu groba nije moguće ustanoviti. Kostur je ispružen na leđima i položen na zdravicu. Sa zapadne strane, od zdjelice na više, presjekao ga je grob 17. Dužina očuvanoga dijela kostura iznosi 1,26 m.

Nalazi: s vanjske strane lijevoga koljena pronađen je željezni nož (T. 1: 7), a ispod njega željezni čavao. Nož ravnoga hrpta s trnom obloženim drvom s ramenom pločicom i završetkom drške (petom) s listićem od tankoga lima; sječivo usko i ravno te na vrhu lagano zakošeno u šiljak; trn uži od oštrice i širi se prema kraju; obloga uglavnom nedostaje, na dršci su tri rupice za zakovice, zakovica očuvana u zadnjoj rupi, cjevaste zakovice na dršci su željezne, dok su ramena pločica i peta drške izrađene od slitine bakra (vjerojatno mjedi); dužina: 210 mm; sječivo – dužina: 110 mm, širina kod drške: 14,1 mm, debljina: 3,98 mm; drška – dužina: 100 mm, širina: 11,5/19,3 mm, težina: 24,6 g.

Grob 20 – Ukop i zapunu groba nije moguće ustanoviti. Kostur je položen na zdravicu. Vrlo je loše očuvan te je pronađen samo dio desne bedrene kosti i kosti potkoljenica.

Grob 21 – Ukop i zapunu groba nije moguće ustanoviti. Kostur je položen na zdravicu. Očuvane su samo kosti potkoljenica i stopala.

Grob 22 – Ukop i zapunu groba nije moguće ustanoviti. Kostur je položen na zdravicu. Pronađene su samo kosti nogu.

Grob 23 – Ukop i zapunu groba nije moguće ustanoviti. Pronađene su samo kosti jedne potkoljenice položene na zdravicu.

Grob 24 – Ukop i zapunu groba nije moguće ustanoviti. S lijeve strane presječen je ukopom groba 25. Kostur je ispružen na leđima, a desna strana, koja nije uništena ukopom mlađega groba, vrlo je dobro očuvana. Podlaktica je smještena na trbuhu. Dužina očuvanoga dijela kostura iznosi 1,16 m.

Grob 25 – Ukop i zapunu groba nije moguće ustanoviti. Svojim ukopom grob je presjekao lijevu stranu groba 24. Kostur je ispružen na leđima, a kosti su relativno dobro očuvane. Podlaktice su na trbuhu. Leži na zdravici. Dužina kostura iznosi 1,6 m.

Nalazi: u grobu su, ispod vrata, pronađeni brončana aplikacija (T. 1: 8), željezni čavao te više komada amorfne bronce. Aplikacija – slitina bakra, pravokutnoga aplikacija od tankoga tiještenog lima sa zakovicom u sredini, sredina je ispučena, a rub je ukrašen nizom kružnih ispupčenja,

tongue goes over the frame, tip is pointed; iron, frame – length: 24.7 mm, height: 30.6 mm; tongue – length: 31.6 mm, base width: 5.46 mm, weight: 6.9 g.

Grave 18 – Grave pit is rectangular in shape with rounded edges, preserved dimensions are 1.32 x 0.45 m. Grave is placed in sterile soil, beneath grave 16. Its left side enters the northern profile of the trench. It is truncated by a later grave pit beneath the pelvis. Fairly poorly preserved skeleton is in a supine, extended position. Right forearm is on the pelvis, left on the stomach. Length of the preserved section of the skeleton is 0.94 m.

Grave 19 – Grave pit and grave fill cannot be determined. Skeleton is in a supine, extended position, and placed in sterile soil. It was truncated by grave 17 on the western side, from the pelvis up. Length of the preserved section of the skeleton is 1.26 m.

Finds: on the outside of the left knee an iron knife (Pl. 1: 7) was found and an iron nail beneath it. Straight backed tanged knife with wooden handle and shoulder plate and leaf-shaped end of the handle (butt) made of thin sheet metal, blade is narrow and straight and slightly pointed at the top, the tang of the handle is narrower than the blade and widens toward the end, and the wooden handle is fastened by rivets, sheath is mostly missing, there are three holes for rivets on the handle, a rivet is preserved in the last hole, tubular rivets on the handle are made from iron, while shoulder plate and butt are made from copper alloy (probably brass); length: 210 mm, blade – length: 110 mm, width by the handle: 14.1 mm, thickness: 3.98 mm; handle – length: 100 mm, width: 11.5/19.3 mm, weight: 24.6 g.

Grave 20 – Grave pit and grave fill cannot be determined. Skeleton was placed in the sterile soil. It is very poorly preserved and only part of the right femur and both tibiae were discovered.

Grave 21 – Grave pit and grave fill cannot be determined. Skeleton was placed in sterile soil. Only the tibiae and feet bones were preserved.

Grave 22 – Grave pit and grave fill cannot be determined. Skeleton was placed in sterile soil. Only the leg bones were discovered.

Grave 23 – Grave pit and grave fill cannot be determined. Only one tibia was discovered, placed in sterile soil.

Grave 24 – Grave pit and grave fill cannot be determined. Grave was truncated on the left side by grave 25. Skeleton is in a supine, extended position, and its right side, which was not destroyed by a later grave, is well preserved. Forearm is placed on the stomach. Length of the preserved section of the skeleton is 1.16 m.

Grave 25 – Grave pit and grave fill cannot be determined. Grave truncated the left side of grave 24. Skeleton is in a supine, extended position and bones were relatively well preserved. Forearms are on the stomach. It is placed in sterile ground. Length of the skeleton is 1.6 m.

Finds: beneath the neck, a bronze appliqué (Pl. 1: 8), iron nail, and several pieces of amorphous bronze were discovered. Appliqué – copper alloy, square appliqué made of thin sheet metal with a rivet in the middle, the middle protrudes and the rim is decorated with circular bulges, damaged, incomplete; dimensions: 10.5 x

oštećena, nepotpuna; dimenzije: 10,5 x 9,3 mm, visina: 4,7 mm, težina: 0,2 g.

Grob 26 – Ukop groba je pravokutnoga oblika sa zaobljenim uglovima. Kostur je ispružen na leđima, položen na dasku što, uz pronalazak čavala, sugerira da je pokopan u drvenome lijesu. Kostu su vrlo loše očuvane, uglavnom u tragovima. Očuvana dužina kostura iznosi 1,5 m.

Nalazi: u grobu su pronađeni čavli (četiri komada).

Grob 27 – Ukop groba je pravokutnoga oblika sa zaobljenim uglovima, očuvanih dimenzija 1,25 x 0,4 m. Raka je sa zapadne strane presječena ukopom groba 30, a s južne dijelom ulazi pod temelj crkve. Kostur je ispružen na leđima, položen na ostatke drva što, uz pronalazak čavala, sugerira da je pokopan u drvenome lijesu. Nedostaje lijeva strana trupa. Desna podlaktica ispružena je uz tijelo. Očuvana dužina kostura iznosi 1,11 m.

Nalazi: čavli.

Grob 28 – Ukop groba očuvan je samo sa sjeverne strane u dužini od 0,85 m, pa se njegov oblik ne može odrediti. Istočni dio groba, od zdjelice na niže, presječen je ukopom groba 26. Kostur je ispružen na leđima, a kosti su relativno loše očuvane. Podlaktice su položene uz tijelo. Očuvana dužina kostura iznosi 0,73 m.

Grob 29 – Ukop i zapunu groba nije moguće ustanoviti. Grob je s obje strane presječen mlađim ukopima. Kostur je ispružen na leđima. Pronađene su samo kosti lijeve strane tijela. Očuvana dužina kostura iznosi 0,85 m.

Nalazi: u grobu je pronađen jedan čavao.

Grob 30 – Ukop groba očuvan je samo u sjeveroistočnome dijelu. Zapadni dio groba presječen je ukopom SJ 005, a južni se nalazi ispod temelja crkve. Kostur je ispružen na leđima, a očuvane su samo kosti zdjelice, bedrene kosti i lijeva potkoljenica. Očuvana dužina kostura iznosi 0,94 m.

Grob 31 – Ukop i zapunu groba nije moguće ustanoviti. Grob je presječen ukopom jame SJ 005 sa zapadne strane i ukopom gromobrana sa sjeverne strane. Od kostiju je očuvana samo desna potkoljenica i dio bedrene kosti, u dužini od 0,52 m.

Grob 32 – Ukop i zapunu groba nije moguće ustanoviti. Grob je presječen ukopom gromobrana te mu nedostaje lubanja. Ukopan je u zdravicu. Kostur je ispružen na leđima s podlakticama prekrštenima na zdjelici. Očuvana dužina kostura iznosi 1,57 m.

Nalazi: novac s unutarnje strane desne noge.⁵

Grob 33 – Ukop i zapunu groba nije moguće ustanoviti. Kostur je položen na građevinsku šutu. Ispružen je na leđima, s desnom rukom savijenom u laktu te šakom položenom na lopaticu, a lijeva ruka je položena na trbuh. Očuvana dužina kostura iznosi 1,30 m.

Nalazi: iznad čela nađeni su dijelovi ogjavlja ili vela – metalnom trakom obložena vlakna lana (1). Na prstu lijeve ruke pronađena su tri brončana prstena (2–4), a na drugome prstu iste šake još jedan brončani prsten u obliku karike (5). Na pojasu je pronađena kopča s ploči-

9.3 mm, height: 4.7 mm, weight: 0.2 g.

Grave 26 – Grave pit is rectangular in shape with rounded edges. Skeleton is in a supine, extended position and was put on a plank, which, together with discovering nails, suggests that it was buried in a wooden coffin. Bones are poorly preserved, mostly in traces. Length of the preserved section of the skeleton is 1.5 m.

Finds: nails were found in grave (four nails).

Grave 27 – Grave pit is rectangular in shape with rounded corners, preserved dimensions of 1.25 x 0.4 meters. The grave pit is cut on the west side by the burial of grave 30. South part of the grave enters below the foundation of the church. Skeleton is in a supine, extended position and was laid on the remains of wood, which, together with discovering nails, suggests that it was buried in a wooden coffin. Bones are poorly preserved, and the left side of the torso is missing. The right forearm is extended along the body. The preserved length of the skeleton is 1.11 m.

Finds: nails.

Grave 28 – Grave pit is preserved only in the north. Length is 0.85 m, and its shape cannot be determined. Eastern section of the grave, from the pelvis down, is truncated by grave 26. Skeleton was in a supine, extended position and bones are relatively poorly preserved. Forearms were placed next to the body. Length of the preserved section of the skeleton is 0.73 m.

Grave 29 – Grave pit and grave fill cannot be determined. Grave was truncated by later graves on both sides. Skeleton was in a supine, extended position. Only bones of the left side of the body were discovered. Length of the preserved section of the skeleton is 0.85 m.

Finds: one nail was discovered in the grave.

Grave 30 – Grave pit is preserved only in the north-eastern part. Western section of the grave was truncated by pit SU 005 and southern section is beneath the church foundation. Skeleton was in a supine, extended position. Only pelvic bones, femurs and the left tibia were preserved. Length of the preserved section of the skeleton is 0.94 m.

Grave 31 – Grave pit and grave fill cannot be determined. Grave was truncated by pit SU 005 on the western side and lightning rod dig in the north. Only the right tibia and part of the femur were preserved, 0.52 m long.

Grave 32 – Grave pit and grave fill cannot be determined. Grave was truncated by lightning rod dig and is missing a skull. It was placed in sterile soil. Skeleton was in a supine, extended position, with forearms crossed on the pelvis. Length of the preserved section of the skeleton is 1.57 m.

Finds: coins on the inside of the right leg.⁵

Grave 33 – Grave pit and grave fill cannot be determined. Skeleton was placed on building rubble. It was in a supine, extended position with the right arm bent in the elbow and hand placed on the shoulder blade, while the left hand is on the stomach. Length of the preserved section of the skeleton is 1.30 m.

Finds: above the forehead, parts of headgear or vail were found – flax fibres enveloped in metal band (1). Three

⁵ The coins from this grave were unavailable for analysis when this paper was being written.

⁵ Novac iz ovoga groba prilikom izrade rada nije bio dostupan.

com (6) te pravokutna aplika od slitina bakra (7). Preko trbuha pružao se u dva reda pojas od brončanih aplika ušivenih na kožu (8). Na zdjelici i oko nje otkrivena su četiri željezna čavla.

1. Dijelovi oglavlja ili vela (T. 1: 10) – metalnom trakom obložena vlakna lana, slitina bakra, 6 fragmenta; ukupna dužina: $12,5 + 10,5 + 3,6 + 8,7 + 5,3 + 2,8 = 43,4$ mm, promjer niti: 0,8 mm, ukupna težina: nemjerljivo;
2. Prsten s lagano izdignutom glavom i naglašenim rame-nima (T. 1: 16) – bakrena slitina, lijevanje, obruč s unu-tarnje strane ravan, a vanjske lagano zaobljen; na ra-menima je po jedno naglašeno rebro, dio ispod rebra ukrašen nizom paralelnih okomitih linija; na niskom vratu nalazi se ovalna glava ukrašena jako stiliziranim i neprepoznatljivim motivom, oštećen; visina prstena: 26,1 mm, promjer obruča: 24 mm, širina: 3,6 mm u dnu 5,6 mm kod ramena, debljina: 1,4 mm, glava prstena 10 x 8,7 mm, težina: 5 g;
3. Prsten (T. 1: 11) – jednostavan zatvoren prsten, bakrena slitina, trakastoga presjeka; po sredini ukrašen s dvije paralelne užlijebljene linije; promjer: 22,2 mm, širina: 3,5 mm, debljina: 0,97 mm, težina: 1,6 g;
4. Prsten (T. 1: 12) – jednostavan zatvoren prsten, bakrena slitina, trakastoga presjeka; po sredini ukrašen s dvije paralelne užlijebljene linije; promjer: 22,2 mm, širina: 3,5 mm, debljina: 0,96 mm, težina: 1,5 g;
5. Prsten (T. 1: 13) – jednostavan zatvoren prsten, bakrena slitina, unutarnja strana ravna, a vanjska lagano zaobljena; promjer: 20,9 mm, širina: 1,6 mm, debljina: 0,89 mm, težina: 0,5 g;
6. Pojasna kopča s pločicom (T. 1: 14) – okvir kopče je pravokutnoga oblika, izrađen od bakrene slitine; osovina kopče je željezna, vanjska prečka je valovito izvedena, koso položena i ukrašena nizom vegetabilnih motiva; trn je slomljen i veći dio nedostaje; pločica je pričvršćena na željeznu osovinu kopče gdje je i oblo podre-zana, na prijelazu u pravokutno oblikovan dio ukra-šena nizom ispupčenih krugova; preostali dio pločice nedostaje, no u očuvanom dijelu vidljivo je da je bila perforirana, a središnje prečke imale su izgled strelica, sa stražnje strane pločice očuvana je mineralizirana ko-ža pojasa; okvir – dužina: 24,2 mm, visina: 39,8 mm; trn – dužina: 11,5 mm; pločica – očuvana dužina: 26,7 mm, visina: 33,6 mm, težina: 7,2 g;
7. Aplika (T. 1: 15) – dio pojasne garniture – perforirana pravokutna pločica od slitine bakra, središnja okomita prečka lagano polukružno izdignuta te ukrašena ni-zom ispupčenih krugova, vodoravne prečke su u obli-ku strelica, oštećena; svojim izgledom čini par s kop-čom (6); dužina: 40,5 mm, visina: 23,5 mm, težina: 1 g;
8. Aplikacije s pojasa (T. 1: 17) – aplikacije od tankoga lima (slitina bakra), kalotasto oblikovane okrugle glave s rupom za zakovicu u sredini; zakovice su željezne, ukupno pro-nađeno 26 komada; na jednoj aplici očuvani su tragovi većim dijelom mineralizirane lanene tkanine, dijelom oštećene i nepotpune; promjer: 20 mm, visina: 7 mm,

bronze rings (2–4) were discovered on a finger of the left hand, and another bronze ring in the shape of a hoop on different finger of the same hand (5). Belt buckle with a plate (6) was found on the waist, togeth-er with square appliqué made of copper alloys (7). A two-tier belt made of bronze appliqués sewn in leather was extends over the stomach (8). Four iron nails were discovered on the pelvis and around it.

1. Parts of headgear or veil (Pl. 1: 10) – flax fibres envel-oped in metal band, copper alloy, 6 fragments; total weight: $12.5 + 10.5 + 3.6 + 8.7 + 5.3 + 2.8 = 43.4$ mm, thread diameter: 0.8 mm, total weight: immeasurable;
2. Ring with slightly raised crown and thickened shoul-ders (Pl. 1: 16) – copper alloy, cast, hoop is straight on the inside and slightly rounded on the outside, one pronounced rib on each side of the shoulders, part be-neath the shoulders is decorated with a series of paral-lel vertical lines, the short neck carries a very stylized oval head with an unrecognizable motif, damaged; ring height: 26.1 mm, hoop diameter: 24 mm, width: 3.6 mm in the lower part, 5.6 mm by the shoulders, thickness: 1.4 mm, wing head 10 x 8.7 mm, weight: 5 g;
3. Ring (Pl. 1: 11) – simple closed ring, copper alloy, with banded section, decorated with two parallel grooves; diameter: 22.2 mm, width: 3.5 mm, thickness: 0.97 mm, weight: 1.6 g;
4. Ring (Pl. 1: 12) - simple closed ring, copper alloy, with banded section, decorated with two parallel grooves; diameter: 22.2 mm, width: 3.5 mm, thickness: 0.96 mm, weight: 1.5 g;
5. Ring (Pl. 1: 13) - simple closed ring, copper alloy, straight on the inside and slightly rounded on the out-side; diameter: 20.9 mm, width: 1.6 mm, thickness: 0.89, weight: 0.5 g;
6. Belt buckle with a plate (Pl. 1: 14) – frame is square, made of copper alloy, the base is made of iron, outer bar is wavy, placed diagonally and decorated by a se-quence of plant motifs, tongue is broken and most of it is missing, plate is attached to the metal base of the buckle, where it is roundly cut, it is decorated by pro-truding circles in the part where it transitions to the square section, the rest of the plate is missing, but it is visible from the preserved part that it was perforated and the central bars were looked like arrows, on the backside of the plate, mineralized leather of the belt was preserved; frame – length: 24.2 mm, height: 39.8 mm; tongue – length : 11.5 mm; plate – preserved length : 26.7 mm, height: 33.6 mm, weight: 7.2 g;
7. Appliqué (Pl. 1: 15) – part of the belt set – perforated square plate made of copper alloy, central vertical bar is slightly semi-circularly raised and decorated by se-quence of protruding circles, horizontal bars are arrow-shaped, damaged, it seems it is paired with the buckle (6); length: 40.5 mm, height: 23.5 mm, weight: 1 g;
8. Appliqués from the waist area (Pl. 1: 17) – appliqués made of thin sheet metal (copper alloy), calotte-shaped round head with a hole for the rivet in the middle, rivets are iron, 26 pieces were discovered in total, one of the appliqués contained preserved traces of mostly mineralized flax fabric, partly damaged and

težina: 0,8 g.

Grob 34 – Ukop i zapunu groba nije moguće ustanoviti. Kostur je ispružen na leđima. Kostii glave i nogu nedostaju. Očuvana dužina kostura iznosi 0,54 m.

Grob 35 – Ukop i zapunu groba nije moguće ustanoviti. Kostur je ispružen na leđima, a kosti su vrlo loše očuvane – samo potkoljenice i dijelovi bedrenih kostiju. Očuvana dužina kostura iznosi 0,68 m.

Grob 36 – Ukop i zapunu groba nije moguće ustanoviti. Kostur je ispružen na leđima, nedostaje mu lijeva strana tijela koja je presječena ukopom gromobrana. Desna podlaktica je na trbuhu. Očuvana dužina kostura iznosi 1,43 m.

Grob 37 – Ukop i zapunu groba nije moguće ustanoviti. Kostur je ispružen na leđima i položen na zdravicu. Očuvane su samo kosti trupa, nadlaktica i desna palčana kost. Očuvana dužina kostura iznosi 0,57 m.

Grob 38 – Ukop groba je pravokutnoga oblika sa zaobljenim uglovima. Grob je ukopan u zdravicu. Kostur je ispružen na leđima, položen u iznimno široku raku. Kostii su u dosta lošem stanju, dijelom očuvani u tragovima. Desna podlaktica je na zdjelici. Očuvana dužina kostura iznosi 1,76 m. U zapuni rake otkriveno je nekoliko željeznih čavala.

Grob 39 – Ukop groba je pravokutnoga oblika sa zaobljenim uglovima. Grob je ukopan u zdravicu. U visini ramena presječen ukopom groba 38, ispod desne potkoljenice presječen zidom/kontraforom, a lijeva noga presječena je ukopom mlađe jame. Kostur je ispružen na leđima. Očuvana dužina kostura iznosi 0,9 m.

Grob 40 – Ukop i zapunu groba nije moguće ustanoviti. Grob je ukopan u SJ 002. Ispod njega se nalazi grob 44. Kostur je ispružen na leđima. Nedostaje glava, a kosti torza djelomično su poremećene. Očuvana dužina kostura iznosi 0,83 m.

Grob 41 – Ukop i zapunu groba nije moguće ustanoviti. Grob je loše očuvan, oštećen ukopom groba 40. Očuvana je samo lijeva noga. Dužina kostura iznosi 0,83 m.

Grob 42 – Ukop groba je pravokutnoga oblika sa zaobljenim uglovima. Većim dijelom nalazi se ispod temelja crkve. U ukopu nije nađen kostur, nego samo nekoliko čavala.

Grob 43 – Ukop i zapunu groba nije moguće ustanoviti. Kostur je ispružen na leđima s lijevom podlakticom ispruženom uz tijelo. Leži na desnoj nozi kostura iz groba 44, pored groba 45. Nedostaju glava i lijeva strana prsnoga koša. Očuvana dužina kostura iznosi 1,15 m.

Grob 44 – Ukop groba je pravokutnoga oblika sa zaobljenim uglovima. Ne može se ustanoviti granica između ovoga i ukopa za grob 46. Leži ispod grobova 43 i 45. Kostur je ispružen na leđima, a kosti su dobro očuvane. Objee podlaktice su na zdjelici. Očuvana dužina kostura iznosi 1,67 m.

incomplete; diameter: 20 mm, height: 7 mm, weight: 0.8 g

Grave 34 – Grave pit and grave fill cannot be determined. Skeleton is in a supine, extended position. Head and leg bones are missing. Length of the preserved section of the skeleton is 0.54 m.

Grave 35 – Grave pit and grave fill cannot be determined. Skeleton is in a supine, extended position, bones are very poorly preserved – only tibiae and parts of femurs were preserved. Length of the preserved section of the skeleton is 0.68 m.

Grave 36 – Grave pit and grave fill cannot be determined. Skeleton is in a supine, extended position, it is missing the left part of the body, which was truncated by lightning rod dig. Right forearm is on the stomach. Length of the preserved section of the skeleton is 1.43 m.

Grave 37 – Grave pit and grave fill cannot be determined. Skeleton was placed in sterile soil. Only bones of the torso, the humerus and the right radius were preserved. Length of the preserved section of the skeleton is 0.57 m.

Grave 38 – Grave pit is rectangular in shape with rounded edges. Grave is put in sterile soil. Skeleton is in a supine, extended position and placed in an extraordinary wide pit. Bones are in fairly poor condition, partly preserved in traces. Right forearm is on the pelvis. Length of the preserved section of the skeleton is 1.76 m. A couple of iron nails were discovered in the grave fill.

Grave 39 – Grave pit is rectangular in shape with rounded edges. Grave is put in sterile soil. It was truncated next to the shoulders by grave 38, beneath right tibia truncated by a wall/buttress, left leg was truncated by a later pit. Skeleton is in a supine, extended position. Length of the preserved section of the skeleton is 0.9 m.

Grave 40 – Grave pit and grave fill cannot be determined. Grave was dug in SU 002. Grave 44 is beneath it. Skeleton is in a supine, extended position. The head is missing and torso bones are partially disrupted. Length of the preserved section of the skeleton is 0.83 m.

Grave 41 – Grave pit and grave fill cannot be determined. Grave is poorly preserved, damaged by grave 40. Only the left leg was preserved. Length of the preserved section of the skeleton is 0.83 m.

Grave 42 – Grave pit is rectangular in shape with rounded edges. It is mostly situated beneath the foundation of the church. No skeletons were found in it, only a couple of nails.

Grave 43 – Grave pit and grave fill cannot be determined. Skeleton is in a supine, extended position with its forearm extended new to the body. It lies on the right leg of skeleton from grave 44, next to grave 45. Head and left side of the chest is missing. Length of the preserved section of the skeleton is 1.15 m.

Grave 44 – Grave pit is rectangular in shape with rounded edges. The boundary between grave 46 and this one cannot be determined. It is placed beneath graves 43 and 45. Skeleton is in a supine, extended position and bones are well preserved. Both forearms are on the pelvis. Length of the preserved section of the skeleton is 1.67 m.

- Grob 45** – Ukop i zapunu groba nije moguće ustanoviti. Grob leži na lijevoj nozi pokojnika iz groba 44. Kostur je ispružen na leđima. Nedostaje mu glava, lijeva ruka te dijelovi potkoljenica. Desna podlaktica je ispružena uz tijelo. Očuvana dužina kostura iznosi 0,63 m.
- Grob 46** – Ukop i zapunu groba nije moguće ustanoviti. Leži ispod groba 43. Desni dio groba nalazi se ispod temelja crkve. Očuvani su lijeva noga i zdjelica. Dužina kostura iznosi 1,08 m.
- Grob 47** – Radi se o recentnijem ukopu, pa je grob samo fotografiran i nije vađen.
- Grob 48** – Ukop groba je pravokutnoga oblika sa zaobljenim uglovima. Grob južnim dijelom ulazi pod sjeverni zid crkve, a zapadni i sjeverni rub presječeni su temeljem stepenica za ambon. Ukopan je u zdravicu. Kostur je ispružen na lijevome boku. Nedostaju kosti lica, rebra te desna ruka. Očuvana dužina kostura iznosi 1,35 m.
- Grob 49** – Ukop i zapunu groba nije moguće ustanoviti. Kostur je ispružen na leđima. Lijeva ruka i noge nalaze se izvan ruba sonde, a desna ruka nedostaje. Istražena dužina kostura iznosi 1,1 m.
- Nalazi: na spoju lijeve ključne kosti i kralježnice nađena je željezna kopča s kukom i ušicom (T. 1: 9) – željezo, udvojena i presavinuta žica u obliku kukice te ušica od žice savinute u obliku omega; na krajevima kopče očuvani su ostaci lanene tkanine, dio ušice nedostaje; kuka – dužina: 15,6 mm, širina: 8,6 mm; ušica – dužina: 17,2 mm, širina: /, težina para: 0,6 g.
- Grob 50** – Ukop i zapunu groba nije moguće ustanoviti. Grob je ukopan u zdravicu. Kostur je ispružen na leđima. Oštećen je ukopom gromobrana. Nedostaju glava, lijeva nadlaktica, lijeva noga te desna potkoljenica. Obje podlaktice su na trbuhu. Očuvana dužina kostura iznosi 1 m.
- Grob 51** – Ukop i zapunu groba nije moguće ustanoviti. Grob je ukopan u zdravicu. Nalazi se ispod groba 49. Glava i noge nalaze se izvan ruba sonde. Kostur je ispružen na leđima. Lijeva podlaktica je na zdjelici. Dužina kostura unutar sonde iznosi 0,65 m.
- Grob 52** – Ukop groba je pravokutnoga oblika sa zaobljenim uglovima. Grob je ukopan u zdravicu. Istočni dio groba presjekao je ukop groba 53. Kostur je ispružen na leđima, relativno loše očuvan. Očuvana dužina kostura iznosi 1,1 m.
- Grob 53** – Očuvan je samo zapadni rub ukopa te kosti lubanje. Sve ostalo je presječeno ukopom SJ 029.
- Grob 54** – Ukop i zapunu groba nije moguće ustanoviti. Grob je ukopan u SJ 023. Kostur je ispružen na leđima. Dosta je poremećen i nedostaju mu kosti nogu. Desna podlaktica je na trbuhu. Očuvana dužina kostura iznosi 0,87 m.
- Grob 55** – Ukop i zapunu groba nije moguće ustanoviti. Veći dio groba nalazi se izvan ruba sonde te su unutar nje zabilježene samo kosti nogu. Očuvana dužina kostura

- Grave 45** – Grave pit and grave fill cannot be determined. Grave lies on the left leg of the individual from grave 44. Skeleton is in a supine, extended position. It is missing the head, left arm and parts of tibiae. Right forearm is extended next to the body. Length of the preserved section of the skeleton is 0.63 m.
- Grave 46** – Grave pit and grave fill cannot be determined. It lies beneath grave 43. Right part of the grave is situated beneath church foundation. Left leg and pelvis are preserved. Length of the preserved section of the skeleton is 1.08 m.
- Grave 47** – This is a more recent grave pit and it was only photographed without excavation.
- Grave 48** – Grave pit is rectangular in shape with rounded edges. Southern side of grave goes under northern wall of the church, and its western end northern edge were truncated by foundation for the staircase of the ambo. It was buried in sterile soil. Skeleton is on its left side, in an extended position. Facial bones, ribs and right arm are missing. Length of the preserved section of the skeleton is 1.35 m.
- Grave 49** – Grave pit and grave fill cannot be determined. Skeleton is in a supine, extended position. Left arm and legs are outside of the trench, right arm is missing. Length of the excavated section of the skeleton is 1.1 m.
- Finds: iron hook-and-eye fastener (Pl. 1: 9) was discovered at the joint of left clavicle and spine – iron, double-looped clasp in the shape of a hook and an eye bent into omega, remains of flax fabric were discovered at the ends of the fastener, part of the eye is missing; hook – length: 15.6 mm, width: 8.6 mm; eye – length: 17.2 mm, width: /, weight of the pair: 0.6 g.
- Grave 50** – Grave pit and grave fill cannot be determined. Grave is put in sterile soil. Skeleton is in a supine, extended position. It was damaged by lightning rod dig. Head, left humerus, left leg and right tibia are missing. Both forearms are on the stomach. Length of the preserved section of the skeleton is 1 m.
- Grave 51** – Grave pit and grave fill cannot be determined. Grave is put in sterile soil beneath grave 49. Head and legs are outside of the trench. Skeleton is in a supine, extended position. Left forearm is on the pelvis. Length of the skeleton within the trench is 0.65 m.
- Grave 52** – Grave pit is rectangular in shape with rounded edges. Grave is put in sterile soil. Eastern part of the grave truncated grave 53. Skeleton is in a supine, extended position, relatively poorly preserved. Length of the preserved section of the skeleton is 1.1 m.
- Grave 53** – Only the western part of the grave pit is preserved and skull bones. Everything else was truncated by SU 029.
- Grave 54** – Grave pit and grave fill cannot be determined. Grave is placed in SU 023. Skeleton is in a supine, extended position. It was disrupted and leg bones are missing. Right forearm is on the stomach. Length of the preserved section of the skeleton is 0.87 m.
- Grave 55** – Grave pit and grave fill cannot be determined. Most of the grave is outside of the trench, and only leg bones were discovered within it. Length of the preserved section of the skeleton is 0.7 m.

iznosi 0,7 m.

ZAHVALE

Autori žele zahvaliti djelatnicima Gradskoga muzeja Vinkovci, Maji Krznarić Škrivanko, Aniti Rapan Papeša i Hrvoju Vuliću na posudbi arheološkoga i antropološkoga materijala s lokaliteta Crkva Rođenja sv. Ivana Krstitelja iz Ivankova te dozvoli za njegovu objavu.

Prijevod / Translation
Kristina Deskar

Lektura / Proofreading
Marko Maras

ACKNOWLEDGMENTS

The authors would like to thank Vinkovci Municipal Museum staff: Maja Krznarić Škrivanko, Anita Rapan Papeša and Hrvoje Vulić for lending them the archaeological and anthropological material from the site of the church of the Birth of St. John the Baptist in Ivankovo and the permission to publish it.

LITERATURA / BIBLIOGRAPHY

- Adamček, J. 1980, *Agrarni odnosi u Hrvatskoj od sredine 15. do kraja 17. stoljeća*, Sveučilišna naklada Liber, Zagreb.
- AlQahtani, S. J., Hector, M. P., Liversidge, H. M. 2010, Brief communication: The London atlas of human tooth development and eruption, *American Journal of Physical Anthropology*, Vol. 142, 481–490. doi: 10.1002/ajpa.21258
- Andrić, S. 2003, Srednjovjekovno Ivankovo i njegovi gospodari, in: *Ivankovo*, Landeka M. (ed.), Općina Ivankovo, Ivankovo, 29–43.
- Anđelinović, Š., Anterić, I., Škorić, E., Bašić, Ž. 2015, Skeleton changes induced by horse riding on medieval skeletal remains from Croatia, *The International Journal of the History of Sport*, Vol. 32(5), 708–721. <https://doi.org/10.1080/09523367.2015.1038251>
- Aufderheide, A. C., Rodríguez-Martín, C. 1998, *The Cambridge encyclopedia of human paleopathology*, Cambridge University Press, Cambridge.
- Bass, W. M. 1995, *Human osteology. A laboratory and field manual of the human skeleton*, Missouri Archaeological Society, Columbia.
- Belaj, J. 2006, Interpretiranje novovjekovnih nalaza iz grobova crkve Sv. Martina na Prozorju / Interpretation of the Modern Age finds from the graves of the church of St. Martin at Prozorje, *Prilozi instituta za arheologiju u Zagrebu*, Vol. 23, 257–294.
- Brooks, S. T., Suchey, J. M. 1990, Skeletal age determination based on the os pubis: A comparison of the Acsádi-Nemeskéri and Suchey-Brooks methods, *Human Evolution*, Vol. 5(3), 227–238. <https://doi.org/10.1007/BF02437238>
- Brothwell, D. R. 1981, *Digging up bones*, Cornell University Press, Ithaca.
- Buckberry, J. L., Chamberlain, A. T. 2002, Age estimation from the auricular surface of the ilium: A revised method, *American Journal of Physical Anthropology*, Vol. 119(3), 231–239. doi: 10.1002/ajpa.10130
- Buikstra, J. E., Ubelaker, D. H. 1994, *Standards for data collection from human skeletal remains*, Arkansas Archaeological Survey, Fayetteville.
- Burić, T. 2001, Putalj u srednjem vijeku, in: *Sv. Juraj od Putalja*, Burić T., Čače S., Fadić I. (eds.), Muzej hrvatskih arheoloških spomenika, Split, 151–322.
- Daniell, C. 2005, *Death and burial in medieval England 1066-1550*, Routledge, London – New York.
- Demo, Ž. 2007, *Opatovina - tragovi povijesti izgubljene u sadašnjosti*, Arheološki muzej, Zagreb.
- Dolenz, H. T. 1992, Studien zu den Eisenmessern vom Magdalensberg in Kärnten, *Carinthia*, Vol. 1, 93–134.
- Dorn, A. 1978, Kliško groblje, Klis, Vukovar – srednjovjekovna nekropola, *Arheološki pregled*, Vol. 20, 130–133.
- Egan, G., Pritchard, F. 2002, *Dress Accessories c. 1150 – c. 1450*, Medieval Finds from Excavations in London 3, Boydell Press, London.
- Freeth, C. 2000, Dental health in British antiquity, in: *Human osteology in archaeology and forensic science*, Cox M., Mays S. (eds.), Cambridge University Press, Cambridge, 227–237.
- Goodman, A. H., Rose, J. C. 1990, Assessment of systemic physiological perturbations from dental enamel hypoplasias and associated histological structures, *American Journal of Physical Anthropology*, Vol. 33(S11), 59–110. <https://doi.org/10.1002/ajpa.1330330506>
- Gustafson, G., Koch, G. 1974, Age estimation up to 16 years of age based on dental development, *Odontologisk revy*, Vol. 25, 297–306.
- Hillson, S. 1996, *Dental anthropology*, Cambridge University Press, Cambridge.
- Holl, I. 1995, A Középkori kées mesterség, *Archeologiai Értesítő*, Vol. 121–122/1994–1995, 159–188.
- Horvat, R. 2000, *Srijem, naselja i stanovništvo*, Hrvatski Institut za povijest, Podružnica za povijest Slavonije, Srijema i Baranje, Slavonski Brod.
- Işcan, M. Y., Loth, S. R., Wright, R. K. 1984, Age estimation from the rib by phase analysis: white males, *Journal of Forensic Sciences*, Vol. 29(4), 1094–1104. <https://doi.org/10.1520/JFS11776J>
- Işcan, M. Y., Loth, S. R., Wright, R. K. 1985, Age estimation from the rib by phase analysis: white females, *Journal of Forensic Sciences*, Vol. 30(3), 853–863. <https://doi.org/10.1520/JFS11018J>
- Jelovina, D., Vrsalović, D. 1981, Srednjovjekovno groblje na „Begovači“ u selu Biljanima Donjima kod Zadra, *Starohrvatska prosvjeta*, Vol. III(11), 55–136.
- Judd, M. A., Roberts, C. A. 1999, Fracture trauma in a medieval British farming village, *American Journal of Physical Anthropology*, Vol. 109(2), 229–243. [https://doi.org/10.1002/\(SICI\)1096-8644\(199906\)109:2<229::AID-AJPA7>3.0.CO;2-Y](https://doi.org/10.1002/(SICI)1096-8644(199906)109:2<229::AID-AJPA7>3.0.CO;2-Y)
- Juraga, B. 1981, Nakit s galije kod otoka Gnalica s konca 16. st., in: *Nakit na tlu sjeverne Dalmacije od prapovijesti do danas*, katalog izložbe, Batović Š. (ed.), Narodni muzej Zadar, Zadar, 69–71.
- Kerman, B. 1997, Srednji in novi vek v Prekmurju v luči arheoloških najdb, in: *Katalog stalne razstave*, Pokrajinski muzej Murska Sobota, Murska Sobota, 45–54.
- Kolar Dimitrijević, M. 2003, Urbar pavlinskog samostana u Strezi 1477, *Podravina*, Vol. 2(3), 103–123.
- Krogman, W. M., İşcan, M. Y. 1986, *The human skeleton in forensic medicine*, C. C. Thomas, Springfield.
- Krznar, S. in press, Can the position of the forearms serve as a dating determinant in medieval and early modern cemeteries on the territory of the northern Croatia?, in: *Homines, Funera, Astra VI: Proceedings of the International Symposium on Funerary Anthropology*, Alba Iulia, Romania.
- Krznar, S., Novak, M. 2013, Slučaj koštane tuberkuloze s nalazišta Sv. Ivan Krstitelj u Ivankovu kraj Vinkovaca / A case of skeletal tuberculosis from St. John the Baptist site in Ivankovo near Vinkovci, *Prilozi Instituta za arheologiju u Zagrebu*, Vol. 30, 93–106.
- Krznarić Škrivanko, M. 2003, Arheološka topografija nalaza i nalazišta na području Ivankova, in: *Ivankovo*, Landeka M. (ed.), Općina Ivankovo, Ivankovo, 15–27.
- Krznarić Škrivanko, M. 2007, Rekognosciranje vinkovačkog kraja, *Hrvatski arheološki godišnjak*, 3/2006, 48–51.
- Krznarić Škrivanko, M. 2009, Ivankovo – crkva rođenja Sv. Ivana Krstitelja, *Hrvatski arheološki godišnjak*, 5/2008, 83–86.
- Landeka, M. 2003, Razvoj Ivankova od 1536. do 2000. godine, in: *Ivankovo*, Landeka M. (ed.), Općina Ivankovo, Ivankovo, 45–63.
- Larsen, C. S. 1997, *Bioarchaeology: Interpreting behavior from the human skeleton*, Cambridge University Press, Cambridge. <https://doi.org/10.1017/CBO9780511802676>
- Lewis, M. 2007, *The bioarchaeology of children: Perspectives from biological and forensic anthropology*, Cambridge University Press, Cambridge. <https://doi.org/10.1017/CBO9780511542473>
- Lovejoy, C. O. 1985, Dental wear in the Libben population: Its functional pattern and role in the determination of adult skeletal age at death, *American Journal of Physical Anthropology*, Vol. 68(1), 47–56. <https://doi.org/10.1002/ajpa.1330680105>
- Lovejoy, C. O., Meindl, R. S., Pryzbeck, T. R., Mensforth, R. P. 1985, Chronological metamorphosis of the auricular surface of the ilium: a new method for the determination of age at death, *American Journal of Physical Anthropology*, Vol. 68(1), 15–28. <https://doi.org/10.1002/ajpa.1330680103>
- Lovell, N. C. 1997, Trauma analysis in paleopathology, *Yearbook of Physical Anthropology*, Vol. 104(S25), 139–170. [https://doi.org/10.1002/\(SICI\)1096-8644\(1997\)25+<139::AID-AJPA6>3.0.CO;2-%23](https://doi.org/10.1002/(SICI)1096-8644(1997)25+<139::AID-AJPA6>3.0.CO;2-%23)
- Maneva, E. 2011, Primjeri pečatnog prstenja iz Vodičke nekropole kod Strumice, *Archeologia Adriatica*, Vol. 4, 339–356.
- Mann, R. W., Hunt, D. R. 2005, *Photographic regional atlas of bone disease: A guide to pathologic and normal variation in the human skeleton*, C. C. Thomas, Springfield.
- Maresh, M. M. 1970, Measurements from roentgenograms, in: *Human growth and development*, McCammon R. W. (ed.), C. C. Thomas, Springfield, 157–200.
- Meindl, R. S., Lovejoy, C. O. 1985, Ectocranial suture closure: A revised method for the determination of skeletal age at death based on the lateral-anterior sutures, *American Journal of Physical Anthropology*, Vol. 68(1), 57–66. <https://doi.org/10.1002/ajpa.1330680106>
- Mensforth, R. P., Lovejoy, C. O., Lallo, J. W., Armelagos, G. J. 1978, The role of constitutional factors, diet, and infectious disease in the etiology of porotic hyperostosis and periosteal reactions in prehistoric infants and children, *Medical Anthropology*, Vol. 2(1), 1–59. <https://doi.org/10.1080/01459740.1978.9986939>
- Metress, J. F., Conway, T. 1975, Standardized system for recording dental caries in prehistoric skeletons, *Journal of Dental Research*, Vol. 54(4), 908. doi: 10.1177/00220345750540043901
- Milošević, D. 1990, *Nakit od 12. do 15. veka iz zbirke Narodnog muzeja*, Narodni muzej, Beograd.

- Moorrees, C. F. A., Fanning, E. A., Hunt, E. E. 1963a, Formation and re-
 sorption of three deciduous teeth in children, *American Journal of
 Physical Anthropology*, Vol. 21(2), 205–213.
<https://doi.org/10.1002/ajpa.1330210212>
- Moorrees, C. F. A., Fanning, E. A., Hunt, E. E. 1963b, Age variation of for-
 mation stages for ten permanent teeth, *Journal of Dental Resear-
 ch*, Vol. 42, 1490–1502. doi: 10.1177/00220345630420062701
- Novak, M., Šlaus, M. 2011, Vertebral pathologies in two Early Modern pe-
 riod (16th–19th century) populations from Croatia, *American Jour-
 nal of Physical Anthropology*, Vol. 145(2), 270–281.
<https://doi.org/10.1002/ajpa.21491>
- Novak, M., Šlaus, M., Pasarić, M. 2009, Subadultni stres u srednjovje-
 kovnim i novovjekovnim populacijama kontinentalne Hrvatske /
 Subadult Stress in the Medieval and Early Modern Populations of
 Continental Croatia, *Prilozi Instituta za arheologiju u Zagrebu*, Vol.
 26, 247–270.
- Novak, M., Šlaus, M., Vyroubal, V., Bedić, Ž. 2010, Dental pathologies in
 rural medieaval populations from continental Croatia, *Anthropo-
 logiai Közlemények*, Vol. 51, 11–21.
- Nyáradi, Z., Gáll, E. 2015, The 'westernisation' of the Transylvanian Basin:
 Migration and/or acculturation?: Wearing hairpins in the 12th cen-
 tury Transylvanian Basin, *Vjesnik Arheološkog muzeja u Zagrebu*,
 3.s. Vol. XLVIII, 85–120.
- Ortner, D. J. 2003, *Identification of pathological conditions in human ske-
 letal remains*, Academic Press, London. [https://doi.org/10.1016/
 B978-0-12-528628-2.X5037-6](https://doi.org/10.1016/B978-0-12-528628-2.X5037-6)
- Pálóczy-Horváth, A. 1984, A rakacaszendi református templom régészeti
 kutatása, *Communicationes archaeologicae Hungariae*, Vol. 1984,
 109–145.
- Perkić, D. 2010, Pavlinski samostan u Kamenskom kod Karlovca, nalazi iz
 grobova kasnog srednjeg i novog vijeka, *Vjesnik Arheološkog mu-
 zeja u Zagrebu*, 3.s. Vol. XLIII, 227–288.
- Perkić, D. 2017, Crkva sv. Jurja u Mateškom Selu: nalazi iz grobova kasno-
 ga srednjeg i novog vijeka / The Church of St. George in Mateško
 Selo: the finds from the graves from the Late Middle Ages and
 the Modern Age, *Prilozi Instituta za arheologiju u Zagrebu*, Vol. 34,
 185–225.
- Petković, D. 2006, *Srednjovjekovna naselja sjeverozapadnog dijela Vin-
 kovačkog kraja*, Acta musei cibalensis 3, Gradski muzej Vinkovci,
 Vinkovci.
- Petrinec, M. 1996, Kasnosrednjovjekovno groblje kod crkve Sv. Spasa u
 Vrh Rici – Katalog, *Starohrvatska prosvjeta*, Vol. III(23), 7–138.
- Pinhasi, R., Bourbou, C. 2007, How representative are human skeletal
 assemblages for population analysis?, in: *Advances in human pa-
 leopathology*, Pinhasi R., Mays S. (eds.), John Wiley & Sons, New
 York, 31–44. <https://doi.org/10.1002/9780470724187.ch2>
- Podpečan, B. 2006, *Nagrobnik, podoba živih*, Archaeologia historica Slo-
 venica 5, Filozofska fakulteta, Oddelek za arheologiju, Ljubljana.
- Predovnik, K., Dacar, M., Lavrinc, M. 2008, *Cerkev Sv. Jerneja v Šentjerneju*,
 Archaeologia historica Slovenica 6, Filozofska fakulteta, Oddelek
 za arheologiju, Ljubljana.
- Roberts, C. 2012, Re-emerging infections: Developments in bioarchaeo-
 logical contributions to understanding tuberculosis today, in: *A
 companion to paleopathology*, Grauer A. L. (ed.), Wiley-Blackwell,
 Chichester, 434–457.
<https://doi.org/10.1002/9781444345940.ch24>
- Roberts, C., Manchester, K. 2005, *The archaeology of disease*, Cornell Uni-
 versity Press, Ithaca.
- Sándor, M. 1985, A Győr-gabonavásártéri XVI-XVII. századi temető,
Communicationes archaeologicae Hungariae, Vol. 1985, 185–198.
- Schaefer, M., Black, S. M., Scheuer, L. 2009, *Juvenile osteology: A labora-
 tory and field manual*, Elsevier Academic Press, London.
- Scheuer, L., Black, S. M. 2000, *Developmental juvenile osteology*, Acade-
 mic Press, London.
<https://doi.org/10.1016/B978-0-12-624000-9.X5000-X>
- Sekelj Ivančan, T., Tkalčec, T. 2003, Arheološko nalazište Torčec – Cirkvi-
 šće, *Podravina*, Vol. 2(4), 5–36.
- Simonyi, E. 2004, Középkori templom és temető Felsőzsolca-Nagyszilvá-
 son, *A Herman Ottó múzeum Évkönyve*, Vol. 43, 161–197.
- Szőke, B. M. 1996, Die prämonstrattenserpropstei von Alsórajk-Ke-
 stélydomb, *Antaeus*, Vol. 23, 251–305.
- Šlaus, M., Bedić, Ž., Rajić Šikanjić, P., Vodanović, M., Domic Kunić, A. 2011,
 Dental health at the transition from the Late Antique to the early
 Medieval period on Croatia's eastern Adriatic coast, *International
 Journal of Osteoarchaeology*, Vol. 21(5), 577–590.
<https://doi.org/10.1002/oa.1163>
- Tkalčec, T. 2010, *Burg Vrbovec u Klenovcu Humskom*, Muzeji Hrvatskog Za-
 gorja – Institut za arheologiju, Zagreb.
- Tkalčec, T. 2016, Odabir mjesta za pokop djece u novom vijeku na pri-
 mjeru Crkvara kod Orahovice, in: *Groblja i pogrebni običaji u sred-
 njem i ranom novom vijeku na prostoru sjeverne Hrvatske*, Zbornik
 Instituta za arheologiju / Serta Instituti Archaeologici 4, Krznar S.,
 Sekelj Ivančan T., Tkalčec T., Belaj J. (eds.), Institut za arheologiju,
 Zagreb, 161–201.
- Tomičić, Ž., Mahović, G. 2011, Metalni nalazi i katalog, in: *Suhopolje – Kliš-
 kovac, Od mjestopisa do arheološke spoznaje*, Tomičić Ž., Jelinčić K.
 (eds.), Monographiae Instituti Archaeologici 4, Institut za arheo-
 logiju, Zagreb, 137–143.
- Unger, J. 2006, *Pohřební ritus 1. až 20. století v Evropě z antropologicko-
 archeologické perspektivy*, Panoráma biologické a sociokulturní
 antropologie 2, Akademické nakladatelství CERM, Brno.
- Veršnik, N. 2009, Knives, in: *The Ljubljana – a river and its past*, Turk P.,
 Istenič J., Knific T., Nabergoj T. (eds.), Narodni muzej Slovenije,
 Ljubljana.
- Vukičević-Samaržija, D. 1986, *Sakralna gotička arhitektura u Slavoniji*, Stu-
 dije i monografije Instituta za povijest umjetnosti 4, Centar za po-
 vijesne znanosti, Odjel za povijest umjetnosti, Zagreb.
- Waldron, T. 2009, *Palaeopathology*, Cambridge University Press, Cam-
 bridge.
- Walker, P. L., Bathurst, R. R., Richman, R., Gjerdrum, T., Andrushko, V. A.
 2009, The causes of porotic hyperostosis and cribra orbitalia: a
 reappraisal of the iron-deficiency anemia hypothesis, *American
 Journal of Physical Anthropology*, Vol. 139(2), 109–125.
 doi: 10.1002/ajpa.21031
- Wheeler, S. M. 2012, Nutritional and disease stress of juveniles from the
 Dakhleh Oasis, Egypt, *International Journal of Osteoarchaeology*,
 Vol. 22(2), 219–234. <https://doi.org/10.1002/oa.1201>
- White, T. D., Folkens, P. A. 2005, *The human bone manual*, Academic Press,
 London. <https://doi.org/10.1016/C2009-0-00102-0>
- Whitehead, R. 1996, *Buckles 1250 – 1800*, Greenlight Publishing,
 Chemsford.
- Zečević, E. 2006, *Nakit Novog Brda / Jewelry from Novo Brdo*, Narodni mu-
 zej u Beogradu, Beograd.



T. 1 Nalazi iz grobova (snimili: D. Doračić: 1–3, 5–15; S. Krznar: 4, 16–17; izradila: K. Turkalj)

Pl. 1 Grave finds (photo by: D. Doračić: 1–3, 5–15; S. Krznar: 4, 16–17; made by: K. Turkalj)