

# Razvojni poremećaj kuka: primjer iz kasnosrednjovjekovne Novske

---

**Kokotović, Tea**

*Source / Izvornik:* **Prilozi Instituta za arheologiju u Zagrebu, 2024, 41, 145 - 174**

**Journal article, Published version**

**Rad u časopisu, Objavljena verzija rada (izdavačev PDF)**

<https://doi.org/10.33254/piaz.41.2.6>

*Permanent link / Trajna poveznica:* <https://urn.nsk.hr/urn:nbn:hr:291:410254>

*Rights / Prava:* [Attribution 4.0 International](#)/[Imenovanje 4.0 međunarodna](#)

*Download date / Datum preuzimanja:* **2025-02-05**



INSTITUT ZA  
ARHEOLOGIJU

*Repository / Repozitorij:*

[RIARH - Repository of the Institute of archaeology](#)



UDK 902  
ISSN 1330-0644  
Vol. 41/2  
ZAGREB, 2024.

# PRILOZI

Instituta za arheologiju u Zagrebu

Pril. Inst. arheol. Zagrebu  
Str./Pages 1–204, Zagreb, 2024.

**PRILOZI INSTITUTA ZA ARHEOLOGIJU  
U ZAGREBU, 41/2/2024  
STR./PAGES 1–204, ZAGREB, 2024.**

Izdavač / Publisher  
INSTITUT ZA ARHEOLOGIJU  
INSTITUTE OF ARCHAEOLOGY

Adresa uredništva /  
Address of the editor's office  
Institut za arheologiju / Institute of archaeology  
HR-10000 Zagreb, Jurjevska ulica 15  
Hrvatska / Croatia  
Telefon / Phone ++385 / (0)1 61 50 250  
Fax ++385(0)1 60 55 806  
e-mail: urednistvo.priloz@iarh.hr  
<http://www.iarh.hr>

Glavni i odgovorni urednik / Editor in chief  
Marko DIZDAR

Tehnički urednici / Technical editors  
Marko DIZDAR  
Katarina BOTIĆ

Uredništvo / Editorial board  
Prapovijest / Prehistory:  
Marko DIZDAR, Institut za arheologiju, Zagreb,  
Hrvatska  
Snježana VRDOLJAK, Institut za arheologiju, Zagreb,  
Hrvatska  
Viktória KISS, Hungarian Academy of Sciences,  
Institute of Archaeology, Budapest, Hungary  
Antika / Antiquities:  
Goranka LIPOVAC VRKLJAN, Institut za arheologiju,  
Zagreb, Hrvatska  
Ivan RADMAN-LIVAJA, Arheološki muzej u Zagrebu,  
Zagreb, Hrvatska  
Srednji vijek i novi vijek / Middle Ages and Modern era:  
Tajana SEKELJ IVANČAN, Institut za arheologiju,  
Zagreb, Hrvatska  
Katarina Katja PREDOVNIK, University of Ljubljana,  
Faculty of Arts, Ljubljana, Slovenia  
Natascha MEHLER, Eberhard Karls University of  
Tübingen, Tübingen, Germany  
Tatjana TKALČEC, Institut za arheologiju, Zagreb,  
Hrvatska  
Juraj BELAJ, Institut za arheologiju, Zagreb, Hrvatska  
Metodologija / Methodology  
Predrag NOVAKOVIĆ, University of Ljubljana, Faculty  
of Arts, Ljubljana, Slovenia

Izdavački savjet / Editorial advisory board  
Dunja GLOGOVIĆ, Zagreb, Hrvatska  
Ivor KARAVANIĆ, Sveučilište u Zagrebu, Filozofski  
fakultet, Odsjek za arheologiju, Zagreb, Hrvatska  
Kornelija MINICHREITER, Zagreb, Hrvatska  
Alexander T. RUTTKAY, Nitra, Slovakia  
Ivančica SCHRUNK, University of St. Thomas, St. Paul,  
Minnesota, USA  
Željko TOMIČIĆ, Hrvatska Akademija znanosti i  
umjetnosti, Zagreb, Hrvatska  
Ante UGLEŠIĆ, Sveučilište u Zadru, Odjel za  
arheologiju, Zadar, Hrvatska

Prijevod na engleski / English translation  
Zdravka HINCAK DARIS, Tea KOKOTOVIĆ,  
Ana KONESTRA, Martina KORIĆ, Marko MARAS,  
Porin ŠČUKANEC REZNIČEK, Nikola VUKOSAVLJEVIĆ

Lektura / Language editor  
Marko DIZDAR (hrvatski jezik / Croatian)  
Marko MARAS, Katarina BOTIĆ (engleski jezik / English)

Korektura / Proofreads  
Katarina BOTIĆ

Grafičko oblikovanje / Graphic design  
Umjetnička organizacija OAZA

Računalni slog / Layout  
Hrvoje JAMBREK

Tisak / Printed by  
Tiskara Zelina d.d., Sv. I. Zelina

Naklada / Issued  
400 primjeraka / 400 copies

Prilozi Instituta za arheologiju u Zagrebu indeksirani su u /  
Prilozi Instituta za arheologiju u Zagrebu are indexed by:  
DYABOLA – Sachkatalog der Bibliothek – Römisch-  
Germanische Kommission des Deutschen  
Archaeologischen Instituts, Frankfurt a. Main  
Clarivate Analytics services – Web of Science Core  
Collection  
CNRS / INIST – Centre National de la Recherche  
Scientifique que / L'Institut de l'Information Scientifique et  
Technique, Vandoeuvre-lès-Nancy  
EBSCO – Information services, Ipswich  
ERIH PLUS – European Reference Index for the  
Humanities and Social Sciences, Norwegian  
Directorate for Higher Education and Skills, Bergen  
SciVerse Scopus – Elsevier, Amsterdam

E-izdanja. Publikacija je dostupna u digitalnom obliku i  
otvorenom pristupu na  
<https://hrcak.srce.hr/priloz-i-az>  
E-edition. The publication is available in digital and  
open access form at  
<https://hrcak.srce.hr/priloz-i-az?lang=en>

DOI 10.33254

Ovaj rad licenciran je pod Creative Commons  
Attribution By 4.0 međunarodnom licencom /  
This work is licenced under a Creative Commons  
attribution By 4.0 international licence  
<https://creativecommons.org/licenses/by/4.0/>



# SADRŽAJ

## CONTENTS

### Izvorni znanstveni radovi

5

VIRGINIA BARCIELA GONZÁLEZ  
AITOR RUIZ-REDONDO  
ANTE VUJNOVIĆ  
NIKOLA VUKOSAVLJEVIĆ

**Prehistoric Schematic Rock Art in the Eastern Adriatic: the discovery of Rock Art at the Badanj II rock shelter (Bosnia and Herzegovina) viewed from the Western Mediterranean**

27

DARIA LOŽNJAK DIZDAR  
SNJEŽANA VRDOLJAK  
IVAN DRNIĆ

**Tragovi igre djece tijekom kasnoga brončanog doba na jugu Karpatske kotline**

59

MARTINA KORIĆ  
**Grčki keramički utezi za tkalački stan iz Fara na otoku Hvaru**

87

NIVES DONEUS  
MICHAEL DONEUS  
TIM KINNAIRD  
SAM TURNER  
MARTIN FERA  
DORIS JETZINGER  
GEERT J. VERHOEVEN

**Lost and found: Roman surveying of municipal territories on the northern Adriatic islands, Croatia**

### Original scientific papers

VIRGINIA BARCIELA GONZÁLEZ  
AITOR RUIZ-REDONDO  
ANTE VUJNOVIĆ  
NIKOLA VUKOSAVLJEVIĆ

Prapovijesna shematska stijenska umjetnost istočnog Jadrana: otkriće stijenske umjetnosti u pripećku Badanj II (Bosna i Hercegovina) iz perspektive zapadnog Mediterana

DARIA LOŽNJAK DIZDAR  
SNJEŽANA VRDOLJAK  
IVAN DRNIĆ

Traces of children's play during the Late Bronze Age in the southern Carpathian Basin

MARTINA KORIĆ

Greek ceramic loom weights from Pharos on the island of Hvar

NIVES DONEUS  
MICHAEL DONEUS  
TIM KINNAIRD  
SAM TURNER  
MARTIN FERA  
DORIS JETZINGER  
GEERT J. VERHOEVEN

Izgubljeno-nađeno: rimsko mjerenje municipalnih zemljišta na sjevernim otocima hrvatskog Jadrana

<b>119</b>	ANA KONESTRA <b>(Peri)urbano vrtlarstvo u Saloni? O nalazu <i>ollae perforatae</i> u salonitanskome <i>urbs orientalis</i> u kontekstu vrtlarstva na istočnome Jadraniu u rimskome razdoblju</b>	ANA KONESTRA <b>(Peri)urban gardening in Salona? On the discovery of <i>ollae perforatae</i> in Salonitan <i>urbs orientalis</i> in the context of gardening on the eastern Adriatic in the Roman period</b>
<b>145</b>	TEA KOKOTOVIĆ <b>Razvojni poremećaj kuka: primjer iz kasnosrednjovjekovne Novske</b>	TEA KOKOTOVIĆ <b>Developmental dysplasia of the hip: an example from late medieval Novska</b>
<b>175</b>	IRENA ĆIRIĆ ANA MIKULKA ZDRAVKA HINČAK DARIS <b>Forenzična rekonstrukcija lica pomoću 3D računalne tehnologije</b>	IRENA ĆIRIĆ ANA MIKULKA ZDRAVKA HINČAK DARIS <b>Forensic facial reconstruction using 3D computerized technology</b>
<b>197</b>	<b>Upute autorima</b>	<b>Guidelines for contributors</b>

# RAZVOJNI POREMEĆAJ KUKA: PRIMJER IZ KASNOSREDNJOVJEKOVNE NOVSKE

## DEVELOPMENTAL DYSPLASIA OF THE HIP: AN EXAMPLE FROM LATE MEDIEVAL NOVSKA

Izvorni znanstveni rad / srednjovjekovna arheologija

Original scientific paper / Mediaeval archaeology

UDK UDC 902:616.72(497.5 Novska)''653''

Primljeno / Received: 30. 09. 2024. Prihvaćeno / Accepted: 27. 11. 2024.

[doi.org/10.33254/piaz.41.2.6](https://doi.org/10.33254/piaz.41.2.6)

**TEA KOKOTOVIĆ**

Institut za arheologiju

Jurjevska ulica 15

HR-10000 Zagreb

[tkokotovic@iarh.hr](mailto:tkokotovic@iarh.hr)

ORCID 0000-0001-8437-0567

U arheološkim istraživanjima crkve sv. Luke Evanđeliste u Novskoj, osim ostataka crkve iz 13. stoljeća, ukupno su otkrivena 94 groba koji potječu iz dva horizonta pokopavanja; kasnosrednjovjekovnog i novovjekovnog. U fokusu ovoga radu je grob 16 koji datira iz razdoblja kasnog srednjeg vijeka. U radu su predstavljeni rezultati bioarheološke analize kosturnih ostataka pronađenih u grobu te diferencijalna dijagnoza na temelju promjena uočenih na području zdjelice i bedrenih kostiju. Pokojnik iz groba 16 bolovao je od razvojnog poremećaja kuka (RPK) koji je rezultirao dislokacijom oba zgloba. RPK se razvija u prvim godinama čovjekova života, a označava poremećaj normalnih anatomskih odnosa u zglobu kuka u kojemu je normalna artikulacija zgloba spriječena. Entezalne promjene uočene na gornjim ekstremitetima, u kombinaciji s RPK-om, otvaraju mogućnost da se osoba za kretanje služila štakama ili nekim drugim pomagalom. Bol uzrokovana RPK-om, kao i moguće korištenje štaka, svakako su utjecali na obavljanje svakodnevnih aktivnosti, pogotovo ako u obzir uzmemo ruralni karakter podneblja u kojem je osoba živjela.

**KLJUČNE RIJEČI:** crkva sv. Luka Evanđeliste, Novska, bioarheologija, razvojni poremećaj kuka, bilateralna dislokacija kuka

In archaeological excavations at the Church of St. Luke the Evangelist in Novska, alongside the remains of the 13<sup>th</sup>-century church, 94 graves from two burial horizons (late medieval and early modern) were discovered. This paper focuses on grave 16, dating to the late Middle Ages. The paper presents the results of a bioarchaeological analysis of the skeletal remains found in the grave, as well as a differential diagnosis based on observed changes to the pelvis and femurs. The individual from grave 16 suffered from developmental dysplasia of the hip (DDH), which resulted in bilateral hip dislocation. DDH, a disorder that develops in the first years of life, disrupts the normal anatomical relations within the hip joint, preventing normal joint articulation. Enthesal changes on the upper extremities, combined with DDH, suggest the individual may have relied on crutches or other mobility aids. The pain associated with DDH, combined with potential crutch use, likely impacted the individual's ability to perform daily activities, especially considering the rural context of their life.

**KEY WORDS:** Church of St Luke the Evangelist, Novska, bioarchaeology, developmental dysplasia of the hip, bilateral hip dislocation



Copyright © Autor(i)  
The Author(s) 2024

Open Access This work is distributed under the terms and conditions of the Creative Commons Attribution 4.0 International license (<https://creativecommons.org/licenses/by/4.0/>) which permits unrestricted re-use, distribution, and reproduction in any medium, provided the original work is properly cited. Open Access Ovaj rad dijeli se prema odredbama i uvjetima licence Creative Commons Attribution 4.0 International license (<https://creativecommons.org/licenses/by/4.0/>), koja dopušta neograničenu ponovnu upotrebu, dijeljenje i reprodukciju u bilo kojem mediju, pod uvjetom da je izvorno djelo ispravno citirano.

## UVOD

Bioarheološka istraživanja pružaju jedinstven uvid u život ljudskih zajednica u prošlosti donoseći nova saznanja o aktivnostima i zdravlju prošlih populacija (Larsen, Walker 2010: 379–380). U paleopatološkim istraživanjima fokus je stavljen na proučavanje bolesti, to jest na niz različitih stanja koje utječu na zdravstveni status pojedinca ili šire zajednice koristeći, ne samo bioarheološke metode i informacije već i dostupne podatke iz arheoloških i povijesnih konteksta, ali i modernih medicinskih istraživanja. Takvim multidisciplinarnim pristupom paleopatološka i bioarheološka istraživanja rekonstruiraju način života zajednica ali i životne povijesti pojedinaca iz prošlosti (Buikstra 2010: 395–396).

Cilj ovog rada je prikazati rijedak primjer razvojnog poremećaja kuka (RPK) koji je rezultirao dislokacijskom oba zgloba kuka te predstavlja jedinstven slučaj u arheološkim populacijama s prostora današnje Hrvatske. Kostur je pronađen tijekom arheoloških istraživanja crkve sv. Luke Evanđeliste u Novskoj 2018. godine i datira iz razdoblja kasnog srednjeg vijeka. U radu je predstavljena diferencijalna dijagnoza na temelju promjena uočenih na zdjelici i bedrenim kostima pokojnika te je raspravljen mogući utjecaj ovog poremećaja na obavljanje svakodnevnih aktivnosti i generalnu kvalitetu života osobe.

### Razvojni poremećaj kuka

Razvojni poremećaj kuka (RPK) označava poremećaj normalnih anatomskih odnosa u zglobu kuka u čijoj je osnovi nedovoljno razvijen acetabul te posljedično, glava bedrene kosti (Manaster 2016: 719), a normalna je artikulacija zgloba spriječena (Plischuk et al. 2018: 108). Poremećaj se javlja u neonatalnoj, natalnoj ili dojenačkoj dobi, a može varirati od prolazne novorođenačke nestabilnosti do potpune dislokacije zgloba kuka (Đapić, Bergovec 2010: 15). RPK se može pojaviti na jednom zglobu kuka (unilateralno) ili na oba (bilateralno). Unilateralni slučajevi su češći (63,4 %), lijevi zglob kuka je češće pogođen (64,0 %) nego desni (Loder, Skopelja 2011: 32) te ovaj poremećaj češće pogađa žene nego muškarce (1 : 5 – 8) (Manaster 2016: 718). U objavljenosti u literaturi podaci o učestalosti ovog poremećaja u modernom dobu variraju, a ovisi o različitim faktorima kao što su period djetetova života u vrijeme pregleda ili metoda korištena prilikom pregleda. Stoga

## INTRODUCTION

Bioarchaeological research offers unique insights into the lives of past communities, shedding new light on the activities and health of ancient populations (Larsen, Walker 2010: 379–380). Palaeopathological research focuses on studying diseases, or various conditions that affect the health of individuals and communities, using not only bioarchaeological methods and information but also data from archaeological and historical contexts, as well as modern medical research. This approach enables palaeopathological and bioarchaeological research to reconstruct the way of life of past populations and the life histories of individuals from the past (Buikstra 2010: 395–396).

This paper presents a rare case of developmental dysplasia of the hip (DDH) that resulted in the dislocation of both hip joints, representing a unique case in archaeological populations on the territory of present-day Croatia. The skeleton was discovered during archaeological excavations at the Church of St Luke the Evangelist in Novska in 2018 and dates to the late medieval period. The paper presents a differential diagnosis based on changes observed on the pelvis and femurs of the deceased and discusses the potential impact of this disorder on the individual's ability to perform daily activities and overall quality of life.

### Developmental dysplasia of the hip

Developmental dysplasia of the hip (DDH) is a disorder that disrupts the normal anatomical relations within the hip joint, characterized by an underdeveloped acetabulum and, consequently, the femoral head (Manaster 2016: 719). It prevents normal joint articulation (Plischuk et al. 2018: 108). DDH can manifest during the neonatal, perinatal, or infantile period and can range from transient neonatal instability to complete dislocation of the hip joint (Đapić, Bergovec 2010: 15). It can affect one hip joint (unilateral) or both (bilateral), with unilateral cases being more common (63.4%). The left hip joint is more frequently affected (64.0%) than the right (Loder, Skopelja 2011: 32), and women are more frequently affected than men (1: 5–8) (Manaster 2016: 718). In published literature, the prevalence of this disorder in modern times varies depending on factors such as the child's age at examination and the screening method used. As a result, prevalence estimates range

se učestalost ovog poremećaja kreće između 1 i 20 ili 1 i 34 slučajeve na 1000 rođene djece (Vasilcova et al. 2022: 2), a u Hrvatskoj se učestalost RPK kreće između 20 i 120 slučajeve na 1000 rođene djece (Vrdoljak et al. 2019: 71). Učestalost također ovisi i o geografskoj regiji. Najmanje je slučajeva RPK zabilježeno na području Afrike (0,6/1000) dok urođeničke populacije sjeverne Amerike bilježe najviše učestalosti (76/1000) (Loder, Skopelja 2011: 32). Etiologija RPK je složena i nije u potpunosti razriješena no moderna klinička istraživanja izdvajaju genetske, okolišne i mehaničke čimbenike koji mogu utjecati na njegov razvoj. Faktori rizika za ovaj poremećaj uključuju ženski spol, pozitivnu obiteljsku povijest (Loder, Skopelja 2011: 32), intrauterino okruženje koje uključuje položaj u maternici (položaj na zadak) (Chan et al. 1997: 99; Dezateux, Rosendhal 2007: 1546), malformacije maternice koje stvaraju pritisak na plod (Chan et al. 1997: 97) te smanjenu koncentraciju hormona relaksina tijekom poroda (Forst et al. 1997). Osim navedenih čimbenika, rizik od razvoja RPK-a također povećavaju i kulturne prakse vezane uz način povijanja djeteta u dojenačkoj dobi u kojemu su noge djeteta ispružene, to jest u ekstenziji i adukciji (Yamamuro, Ischida 1984: 38–39; Mahan, Kasser 2008: 177; Wang et al. 2012: 1076).

Razvojni poremećaj kuka se najčešće ne rješava sam od sebe niti spontano. Danas se ovaj poremećaj dijagnosticira u najranijoj djetetovoj dobi kliničkim pregledom i ultrazvukom kukova te testovima za nestabilnost, sublukaciju i luksaciju kuka (Hefti et al. 2007: 179–196; Vrdoljak et al. 2019: 71–72). Liječenje RPK potrebno je provesti što ranije, a metoda liječenja ovisi o nizu faktora, od kojih se izdvajaju stupanj PRK te djetetova dob (Vrdoljak et al. 2019: 72–73). Metode liječenja uključuju različite vrste ortoza, fizikalnu terapiju te, u najtežim slučajevima, operacijsko liječenje (Hefti et al. 2007: 196–199; Vrdoljak et al. 2019: 72–73). U prošlosti metode rane detekcije nisu bile dostupne i bolest je postala vidljiva tek u trenutku kada dijete počne hodati (Roberts, Manchester 2010: 154). Bez intervencije mobilnost osobe se smanjuje s dobi, a bol se pogoršava te utječe na obavljanje svakodnevnih aktivnosti (Dezateux, Rosendhal 2007: 1545).

Osim nekolicine istraživanja (Mafart et al. 2007; Mitchell, Redfern 2007; 2008; 2011), u paleopatološkoj literaturi većina objavljenih primjera ovog poremećaja na kosturnim ostaci-

from 1 to 20 or 1 to 34 cases per 1,000 births (Vasilcova et al. 2022: 2). In modern-day Croatia, the reported prevalence ranges from 20 to 120 cases per 1,000 births (Vrdoljak et al. 2019: 71). Geographic region also influences prevalence, with the lowest incidence reported in Africa (0.6/1,000) and the highest among Native American populations in North America (76/1,000) (Loder, Skopelja 2011: 32). The etiology of DDH is complex and not yet fully understood, but modern clinical research highlights the potential influence of genetic, environmental, and mechanical factors in its development. Risk factors for this disorder include female sex, a family history of DDH (Loder, Skopelja 2011: 32), an intrauterine environment including breech position (Chan et al. 1997: 99; Dezateux, Rosendhal 2007: 1546), uterus malformations that exert pressure on the foetus (Chan et al. 1997: 97), and reduced levels of the hormone relaxin during birth (Forst et al. 1997). Additionally, cultural practices related to infant swaddling, which keep the child's legs extended and adducted, can increase the risk of DDH (Yamamuro, Ischida 1984: 38–39; Mahan, Kasser 2008: 177; Wang et al. 2012: 1076).

Developmental dysplasia of the hip rarely resolves on its own. It is now diagnosed in the earliest stages of a child's life through clinical examination, hip ultrasound, and tests for instability, subluxation, and dislocation of the hip (Hefti et al. 2007: 179–196; Vrdoljak et al. 2019: 71–72). Early treatment is essential, and treatment methods depend on factors such as the severity of DDH and the child's age (Vrdoljak et al. 2019: 72–73). Treatment methods include various types of orthoses, physical therapy, and, in severe cases, surgery (Hefti et al. 2007: 196–199; Vrdoljak et al. 2019: 72–73). In the past, early detection methods were absent, leading to diagnosis only when children began walking (Roberts, Manchester 2010: 154). Without treatment, mobility declines with age, pain intensifies, and daily activities become increasingly difficult (Dezateux, Rosendhal 2007: 1545).

Apart from a few studies (Mafart et al. 2007; Mitchell, Redfern 2007; 2008; 2011), most examples of this disorder in archaeological skeletal assemblage published in palaeopathological literature are case studies. Significant contributions to understanding this disorder have been made by Mitchell and Redfern (2007; 2008; 2011) through their research on



ma arheološke starosti su studije slučaja. Najveći doprinos razumijevanju ovog poremećaja donijeli su Mitchell i Redfern (2007; 2008; 2011) istraživanjem učestalosti RPK-a u populaciji srednjovjekovnog Londona<sup>1</sup> na temelju kojeg su opisali široki raspon promjena vidljivih na koštanim ostacima koji se mogu povezati s ovom poremećajem. Osim na području Ujedinjenog Kraljevstva (Dawes, Magilton 1980; Wakely 1993; Caffell, Holst 2010), RPK u arheološkim populacijama zabilježen je u Francuskoj (Arnaud, Arnaud 1975; Blondiaux, Millot 1991; Mafart et al. 2007), Nizozemskoj (Katzmarzyk, Schats 2011), Slovačkoj (Masnicová, Beňuš 2003), Poljskoj (Agnew, Justus 2013), Rumunjskoj (Eng et al. 2009), Srbiji (Đukić et al. 2021) i Italiji (Petrella et al. 2016; Saccheri, Travan 2022). Mogući slučaj RPK na prostoru Hrvatske opisali su Kriletić i suradnici (2023) u kasnosrednjovjekovnoj i novovjekovnoj populaciji iz Đakova. Riječ je o odrasloj ženskoj osobi (G1/2019) kod koje je RPK zabilježen na desnom zglobu kuka (Kriletić et al. 2023: 218). Na području Sjeverne Amerike istraživanja su se fokusirala na visoku učestalost RPK u autohtonim zajednicama (Cableaux 1997; Blatt 2015; Aysel 2016), dok je na području južne Amerike, zbog nedovoljnog stanja istraženosti, objavljeno tek nekoliko slučajeva (Moodie 1923; Costa Junqueira, Llagostera Martínez 1994; Plischuk et al. 2018).

## MATERIJALI

Crkva sv. Luke Evanđeliste nalazi se u gradu Novska u Sisačko-moslavačkoj županiji (karta 1), a smještena na omanjem brežuljku u samom središtu grada. Arheološka istraživanja ovog lokaliteta 2018. godine proveo je Institut za arheologiju pod vodstvom dr. sc. Jurja Belaja. Tijekom istraživanja istražen je dio unutrašnjosti crkve te sjeveroistočni i istočni dio izvan nje (Belaj, Stingl 2019; 2021). Iz povijesnih izvora bilo je moguće rekonstruirati pet graditeljskih faza crkve, a izgled prije obnove 2018. godine crkva poprima na kraju pete faze (Belaj, Stingl 2019: 79). Istraživanja su otkrila ostatke najstarije crkve iz druge polovice 13. stoljeća (1. graditeljska faza) te je pretpostavljen njezin tlocrt. Riječ je o jednobrodnoj crkvi s nešto užim kvadratnim svetištem i manjim triforijem na zapadnom dijelu (Belaj, Stingl 2019: 95). Na temelju njezinih ka-

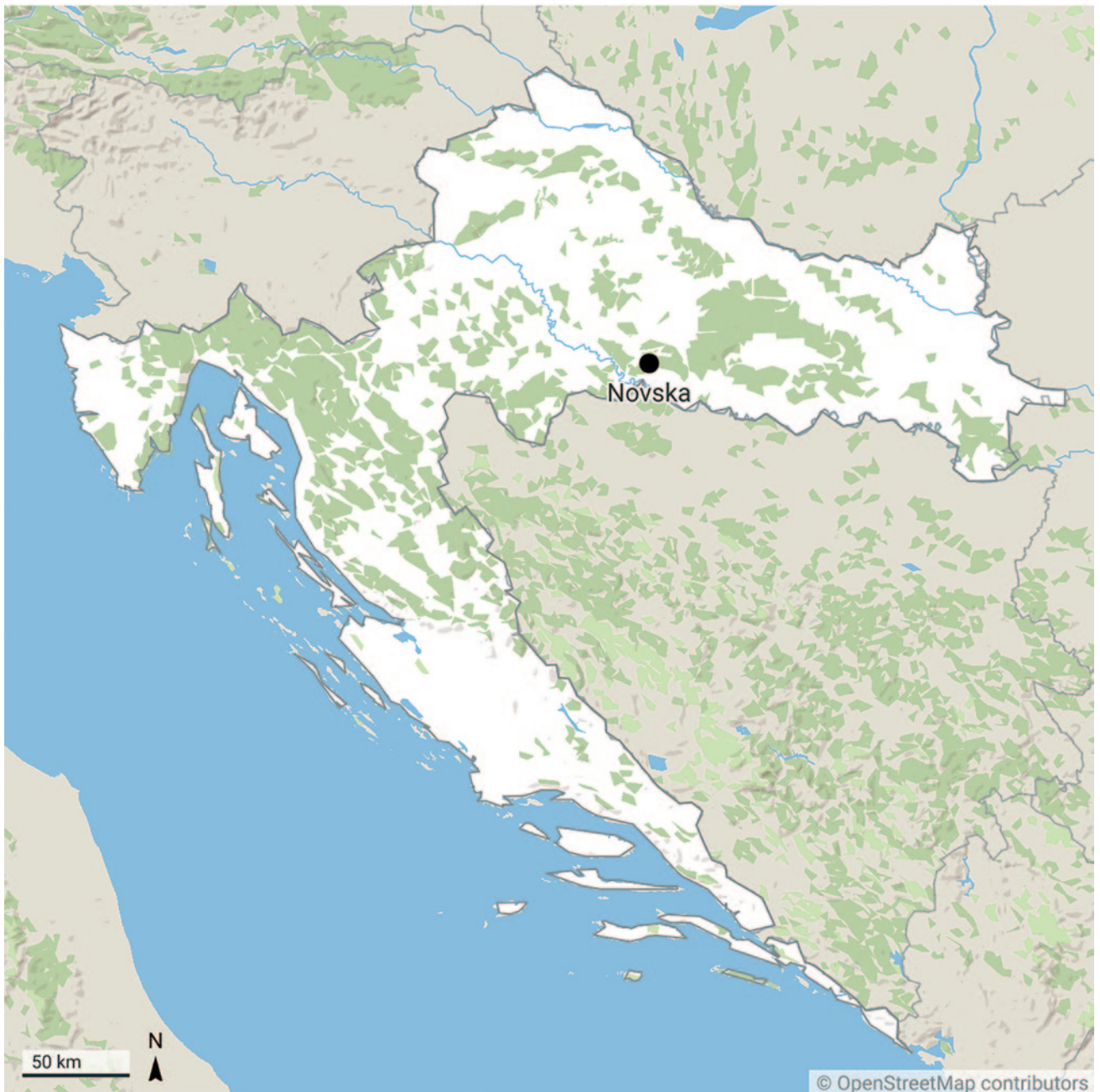the prevalence of DDH in the medieval population of London<sup>1</sup>, where they described a wide range of skeletal changes associated with this disorder. Besides the United Kingdom (Dawes, Magilton 1980; Wakely 1993; Caffell, Holst 2010), DDH has been documented in archaeological populations from France (Arnaud, Arnaud 1975; Blondiaux, Millot 1991; Mafart et al. 2007), the Netherlands (Katzmarzyk, Schats 2011), Slovakia (Masnicová, Beňuš 2003), Poland (Agnew, Justus 2013), Romania (Eng et al. 2009), Serbia (Đukić et al. 2021), and Italy (Petrella et al. 2016; Saccheri, Travan 2022). A possible case of DDH in Croatia was described by Kriletić et al. (2023) in a late medieval and early modern population from Đakovo, where changes indicative of DDH were observed on the right hip of an adult female (G1/2019) (Kriletić et al. 2023: 218). In North America, research has focused on the high prevalence of DDH in Indigenous communities (Cableaux 1997; Blatt 2015; Aysel 2016), while in South America, due to limited research, only a few cases have been published (Moodie 1923; Costa Junqueira, Llagostera Martínez 1994; Plischuk et al. 2018).

## MATERIALS

The Church of St Luke the Evangelist is located in the town of Novska in Sisak-Moslavina County (Map 1), on a small hill in the town centre. Archaeological excavations conducted in 2018 by the Institute of Archaeology, under the direction of Dr. Juraj Belaj, investigated parts of the church interior and the northeastern and eastern exterior areas (Belaj, Stingl 2019; 2021). Five construction phases of the church were reconstructed from historical sources, with the final appearance before the 2018 restoration representing the end of the fifth phase (Belaj, Stingl 2019: 79). The excavations uncovered the remains of the oldest church, dating to the second half of the 13<sup>th</sup> century (1<sup>st</sup> construction phase), allowing for the reconstruction of its layout. It was a single-nave church with a relatively narrow rectangular sanctuary and a small triforium (Belaj, Stingl 2019: 95). Based on its characteristics, Belaj and Stingl (2019: 95) suggest it was a priva-

1 Analizirani kosturni material potječe s groblja bolnice i samostana svete Marije Spital u Spitalfieldsu u Londonu i datira između 1100. i 1530. godine (Thomas 2004; Mitchell, Redfern 2007; 2008; 2011)

1 The analyzed skeletal assemblage comes from the cemetery of the hospital and priory of St Mary Spital, located in Spitalfields, London, and dating from 1100 to 1530 (Thomas 2004; Mitchell, Redfern 2007; 2008; 2011)



Karta 1 – Položaj crkve sv. Luke Evanđeliste u Novskoj (izvor: OpenStreetMap, Creative Commons Attribution-ShareAlike 2.0 license, CC BY-SA 2.0; Created with Datawrapper; izradila: T. Kokotović, 2024)

Map 1 – Position of the Church of St. Luke the Evangelist in Novska (source: OpenStreetMap, Creative Commons Attribution-ShareAlike 2.0 license, CC BY -SA 2.0; created with Datawrapper; made by: T. Kokotović, 2024)

rakteristika, Belaj i Stingl (2019: 95) pretpostavljaju kako je riječ o privatnoj, dvoranskoj crkvi ili kapeli nekog novljanskog gospodara. U istraživanjima su ukupno istražena 94 groba, od kojih je 50 grobova pronađeno unutar crkve, a njih 44 izvan. Identificirana su sveukupno dva horizonta pokopavanja: stariji, kasnosrednjovjekovni horizont, iz vremena 1. graditeljske faze koji traje do dolaska Osmanlija polovicom 16. stoljeća, kada i sama najstarija cr-

te, court church or chapel of a local Novska nobleman. A total of 94 graves were excavated, 50 within the church and 44 outside. Two burial horizons were identified: an older, late medieval horizon, dating from the 1<sup>st</sup> construction phase until the Ottoman arrival in the mid-16<sup>th</sup> century, when the oldest church was destroyed, and a younger, early modern horizon. Six graves inside the church belong to

kva biva uništena, te mlađi, novovjekovni horizont. Najmlađem horizontu zasigurno pripada šest grobova pronađenih unutar crkve, dok ostali potječu iz starijeg horizonta, prije dolaska Osmanlija (Belaj, Stingl 2019: 87). U tom su razdoblju pokojnici često samo omotani u platno i polagani u svježe iskopanu grobnu raku (Demo 2007: 52; Belaj, Stingl 2019: 87). Također, u većini grobova kasnog srednjeg vijeka pronađeni su omanji zelenkasti ulomci troske bakrene legure (Belaj, Stingl 2019: 88) čija namjena zasad nije poznata. S obzirom da pozicija troske u grobovima nije ujednačena, vjerojatnije je u grobne zapune došla zbog njezine rasprostranjenosti na širem terenu, nego što bi u njih bila namjerno prilagana. U vrijeme ranog novog vijeka prisutna je praksa pokapanja pokojnika u drvenom lijesu (Belaj, Stingl 2019: 87). U grobovima novog vijeka češći su prilozi, od kojih dominiraju nabožni predmeti pronađeni u tri od šest (50 %) grobova pripisanih novovjekovnom horizontu (Belaj, Stingl 2019: 92).

## Grob 16

Grob 16 se nalazio izvan crkve, u sektoru VIII-c, sjeverno od današnjeg svetišta odnosno sjeverno od broda starije crkve, na području negdašnje velike sakristije (sl. 1: 1). Pokojnik je bio položen u zemljanu raku orijentacije zapad – istok. Tijelo je bilo položeno na leđa s rukama prekrivenim na području trbuha i ispruženim nogama (sl. 1: 2). U grobu nisu pronađeni tragovi lijesa, a na području desne podlaktice pronađeni su ulomci zelene troske bakrene legure. Kao i svi ostali grobovi pronađeni izvan crkve te većina njih iz njezine unutrašnjosti, grob 16 se pripisuje starijem, kasnosrednjovjekovnom horizontu. U području stopala grob je bio presječen temeljem za zid. Riječ je temelju jednog od mlađih zidova otkrivenih sjeverno od crkve koji je naknadno pridodan temeljima SJ 28 i 31 prigodom skraćivanja velike sakristije.<sup>2</sup> Nažalost, sama datacija temelja ne pomaže u određivanju starosti groba 16. Ako promotrimo dubinu, odnosno apsolutnu visinu groba, svi grobovi u sektoru VIII, njih 27, pokopani su na visini koja varira za 51,5 cm.<sup>3</sup> Visina groba 16 gotovo je identična visini groba 1 u kojemu je pronađeno zvono s urezanim natpisom na glagoljici (Belaj, Stingl 2021: 33–34, sl. 27), razlika je tek 2,3 cm. Budući da je grob 1 datiran radiokarbonskom analizom između 1400. i 1440. godine (Belaj, Stingl

the youngest horizon, while the others date to the older horizon, predating the Ottoman arrival (Belaj, Stingl 2019: 87). During this period, the deceased were often wrapped in cloth and interred in freshly dug graves (Demo 2007: 52; Belaj, Stingl 2019: 87). Small greenish copper alloy slag fragments, of unknown purpose, were found in most late medieval graves (Belaj, Stingl 2019: 88). Given its non-uniform positioning, it is more likely that the slag ended up in the grave fills due to its widespread local presence, rather than being intentionally placed. In the early modern period, the practice shifted to burying the deceased in wooden coffins (Belaj, Stingl 2019: 87). Grave goods, predominantly religious objects, became more common, appearing in three of the six graves (50%) attributed to the early modern horizon (Belaj, Stingl 2019: 92).

## Grave 16

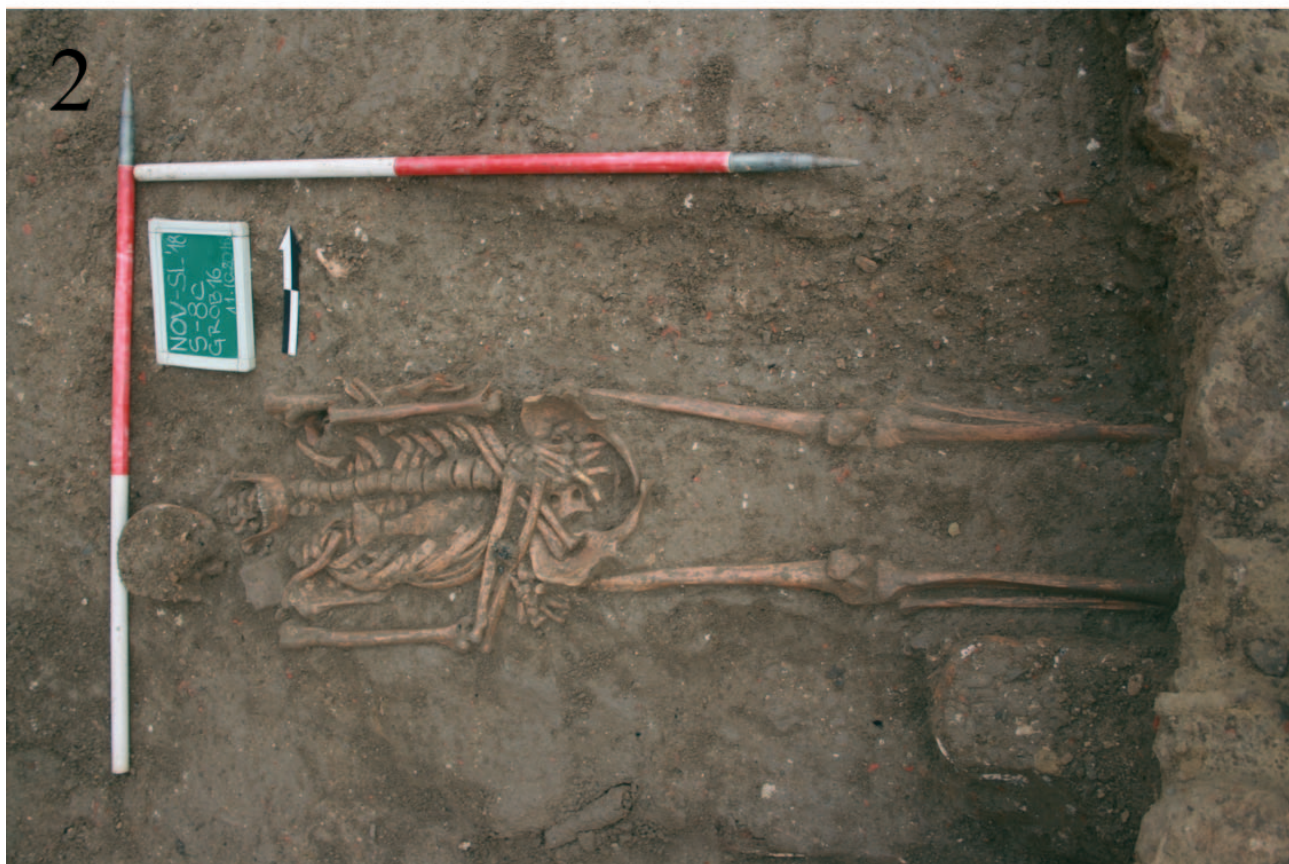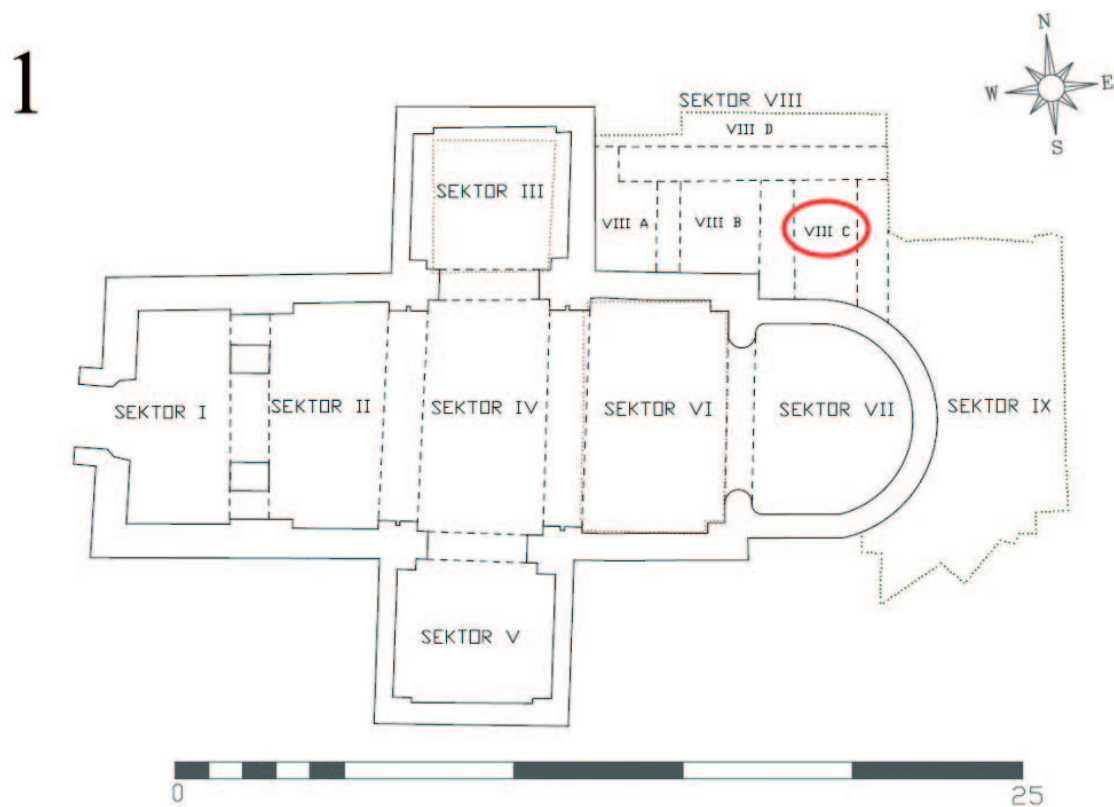
Grave 16 was located outside the church, in sector VIII-c, north of the current sanctuary, i.e., north of the nave of the older church, in the area of the former large sacristy (Fig. 1: 1). The deceased was laid in an earthen grave oriented east-west, positioned supine with arms crossed at the abdomen and legs extended (Fig. 1: 2). No coffin traces were found in the grave, but fragments of green copper alloy slag were found near the right forearm. Like all graves outside the church and most inside, grave 16 is attributed to the older, late medieval horizon. The grave was truncated above the feet of the skeleton by a wall foundation, part of a younger wall discovered north of the church, which was later added to the foundations SU 28 and 31 when the large sacristy was shortened.<sup>2</sup> Unfortunately, the dating of the foundation does not help determine the age of grave 16. If we look at the depth or absolute height, all 27 graves in sector VIII were buried at a height that varies by 51.5 cm.<sup>3</sup> The height of grave 16 is almost identical to grave 1, where a bell with a Glagolitic inscription was found (Belaj, Stingl 2021: 33–34, Fig. 27), differing by only 2.3 cm. As grave 1 was radiocarbon dated between 1400 and 1440 (Belaj, Stingl 2021:

<sup>2</sup> Temelji pronađeni sjeverno od crkve pripisuju se različitim razdobljima, a neki od njih su ostaci različitih faza sakristije (Belaj, Stingl 2019: 90–91).

<sup>3</sup> Dokumentirane apsolutne visine kostura iznose od 123,279 do 123,794 m.

<sup>2</sup> The foundations located north of the church belong to different periods; some of them are remnants of the various phases of the sacristy (Belaj, Stingl 2019: 90–91)

<sup>3</sup> The documented absolute heights of the skeleton range from 123.279 to 123.794 m



Sl. 1 – 1 Podjela lokaliteta na sektore s označenim sektorom u kojemu je pronađen grob 16 (prema Belaj, Stingl 2019: sl. 1; uz dozvolu; prilagodila: T. Kokotović); 2 Grob 16 (snimio: D. Balaban, 2018) (izradila: T. Kokotović, 2024)  
Fig. 1 – 1 Division of the site into sectors with the marked sector where grave 16 was found (after Belaj, Stingl 2019: Fig.1; with permission; adapted by: T. Kokotović); 2 Grave 16 (photo by: D. Balaban, 2018) (made by: T. Kokotović, 2024)

2021: 33),<sup>4</sup> možemo pretpostaviti da mu je i grob 16 suvremen te da je pokopan početkom 15. stoljeća. Kako bi potvrdili ovu dataciju groba, uzorak kosti poslan je na radiokarbonsku analizu u laboratorij Isotoptech Zrt. u Debrecenu (Mađarska), a rezultati se tek očekuju.

## METODOLOGIJA

Koštani materijal makroskopski je analiziran na Institutu za arheologiju u Zagrebu primjenjujući standardne antropološke metode i kriterije. Bioarheološka analiza obuhvatila je procjenu spola i starosti u trenutku smrti, izmjeru postkranijalnog kostura, analizu zubi i paleopatološku analizu. Spol je određen prema morfološkim karakteristikama lubanje i zdjelice (Buikstra, Ubleaker 1994; Klaes 2020). Starost u trenutku smrti je određena na temelju istrošenosti zubnih ploha (Smith 1984), obliteracije ektokranijalnih šavova na lubanji (Meindl, Lovejoy 1985) te morfoloških karakteristika aurikularine površine (Lovejoy et al. 1985) i pubične simfize (Gilbert, McKern 1973; Brooks, Suchey 1990) na zdjelici. Mjere su uzete koristeći standardne osteološke protokole (Buikstra, Ubleaker 1994). Tijekom analize, na kosturu su zabilježene sve vidljive patološke promjene, a kratki opis uočenih promjena slijedi u nastavku teksta.

Linearna hipoplazija zubne cakline je subadultni poremećaj u stvaranju zubne cakline uzrokovan epizodama akutnog stresa u vrijeme djetinjstva, to jest, u vrijeme formacije zuba. Stres može biti uzrokovan fizičkim ili psihološkim traumama, metaboličkim poremećajima, periodima izgladnjivanja, kao i različitim virusnim ili bakterijskim bolestima (Pindborg 1970; Goodman, Rose 1990: 59). Prepoznaje se kao jedna ili više vodoravnih linija na površini krune zuba (Pindborg 1970). Najčešće se pojavljuje na prednjim zubima (sjekutićima i očnjacima), čija formacija enamela započinje u prvoj godini života (AlQahtani et al. 2010: 486–490), stoga su u analizi uključeni sjekutići i očnjaci gornje čeljusti te očnjaci donje čeljusti.

*Cribra orbitalia* je vrsta porotične hiperostoze na gornjim svodovima orbita koja se pojavljuje tijekom djetinjstva, a manifestira se u obliku manjih poroznih lezija (Aufderheide, Rodríguez-

33),<sup>4</sup> we can infer that grave 16 is contemporary, buried at the beginning of the 15<sup>th</sup> century. To confirm this dating, a bone sample was sent for radiocarbon analysis to the Isotoptech Zrt. Laboratory in Debrecen (Hungary), and results are pending.

## METHODOLOGY

The skeletal material was analyzed macroscopically at the Institute of Archaeology in Zagreb using standard anthropological methods and criteria. The bioarchaeological analysis included assessments of sex and age at death, postcranial skeletal measurements, dental analysis, and palaeopathological analysis. Sex was determined based on the morphological characteristics of the skull and pelvis regions (Buikstra, Ubleaker 1994; Klaes 2020). Age at death was estimated based on dental wear (Smith 1984), ectocranial suture obliteration (Meindl, Lovejoy 1985), auricular surface morphology (Lovejoy et al. 1985), and pelvic pubic symphysis (Gilbert, McKern 1973; Brooks, Suchey 1990). Measurements were taken following standard osteological protocols (Buikstra, Ubleaker 1994). During the analysis, all visible pathological changes on the skeleton were recorded. A brief description of the observed changes follows below.

Linear enamel hypoplasia is a subadult disorder affecting tooth enamel formation, caused by episodes of acute stress during childhood, specifically during tooth development. Stress can be caused by physical or psychological trauma, metabolic disorders, periods of starvation, and various viral and bacterial diseases (Pindborg 1970; Goodman, Rose 1990: 59). Linear enamel hypoplasia manifests as one or more horizontal lines on the surface of the tooth crown (Pindborg 1970), most commonly appearing on the front teeth (incisors and canines), whose enamel formation begins in the first year of life (AlQahtani et al. 2010: 486–490). Therefore, the analysis included the maxillary incisors and canines, as well as the mandibular canines.

*Cribra orbitalia* is a type of porotic hyperostosis affecting the upper orbital vaults, appearing during childhood and manifesting as small, porous lesions (Aufderheide, Rodríguez-Martín 1998:

<sup>4</sup> Analiza je provedena u Isotoptech Zrt. laboratoriju u Debrecenu u Mađarskoj (AMS 14C Lab Code – DeA). DeA-28490 (NGr1 bone) Conventional age (BP) ( $\pm\sigma$ ) – 513 $\pm$ 21; Calibrated calendar age (cal AD/BC) ( $2\sigma$ ) – 1400–1440. Kalibracija programom Calib 8.1.0:  $1\sigma$  – cal AD 1410: cal AD 1428 (100 %);  $2\sigma$  – cal AD 1403: cal AD 1439 (100 %).

<sup>4</sup> The AMS radiocarbon age determination was done in Isotoptech Zrt. Laboratory in Debrecen (Hungary) (AMS 14C Lab Code – DeA). DeA-28490 (NGr1 bone) Conventional age (BP) ( $\pm\sigma$ ) – 513 $\pm$ 21; Calibrated calendar age (cal AD/BC) ( $2\sigma$ ) – 1400–1440. Calibrated in Calib 8.1.0:  $1\sigma$  – cal AD 1410: cal AD 1428 (100%);  $2\sigma$  – cal AD 1403: cal AD 1439 (100%).

Martín 1998: 348–351). Pojavljuje se u dva glavna oblika, aktivnom i zraslom (White et al. 2012: 449). Etiologija *cribra orbitalie* je multifaktorijalna, a može se javiti kao posljedica interakcije više faktora koje nije uvijek moguće razlikovati (Schats 2021). Najčešće se povezuje s neadekvatnom prehranom, parazitizmom i nehigijenskim uvjetima života (Hengen 1971; Wolter 1979; Griffeth et al. 1997), a kao uzročnici *cribra orbitalie* navode se megaloblastična i hemolitička anemija (Walker et al. 2009), respiratorna oboljenja (O'Donnell et al. 2020), metaboličkih bolesti poput skorbuta i zarazne bolesti (malarija) (Gowland, Western 2012).

Degenerativni osteoarthritis se na kostima manifestira u obliku pojave osteofita, eburnizacije, formiranja jama na zglobnim plošinama ili promjenama u obrisima zgloba. Karakterizira ga gubitak zglobne hrskavice i reakcija subhondralne kosti i rubova zglobnih plošina (Rogers, Waldron 1995: 34–36). Na razvoj degenerativnog osteoartrisa utječu različiti čimbenici, kao što su pretilost ili genetska predispozicija, no biomehanički stres i starost pojedinca se izdvajaju kao faktori koji najviše pridonose razvoju ovih promjena (Rogers, Waldron 1995: 33). Osteoarthritis se najčešće pojavljuje u zglobovima koji su nosivi i odgovorni za nošenje velikog tereta te je učestaliji kod starijih osoba (White, Folkens 2005: 325).

Zglobne su plohe na kralješcima asimetrične u slučajevima kada su superiorne i inferiorne zglobne plohe na posteriornom dijelu kralješka različitih veličina ili u slučajevima kada superiorni i inferiorni zglobni nastavci nisu paralelni (Mitchell, Redfern 2008: 67). Asimetrija zglobnih ploha je procijenjena makroskopski.

Prijelazni kralježak na lumbosakralnom dijelu kralježnice ima morfološke karakteristike lumbalne i sakralne regije. Riječ je o prirodnoj grešci koja se može pojaviti u dva oblika, sakralizacija i lumbalizacija. Sakralizacija, češći oblik, označava prelazak zadnjeg (petog) slabinskog kralješka u križnu kost. Morfologija križne kosti ostaje nepromijenjena, ali vidljiv je dodatni (peti) otvor križne kosti, dok se kralješnica sastoji od četiri slabinska kralješka. Rjeđi oblik, lumbalizacija, prirodna je greška kralježnice u kojoj je prvi sakralni kralježak odvojen od ostatka križne kosti, a lumbalna se kralješnica sastoji od šest kralježaka. Sakralizacija i lumbalizacija mogu biti potpune ili djelomične, unilateralne ili bilateralne te simetrične ili asimetrične (Aufderheide, Rodríguez-Martín 1998: 65).

Kut velikog sjednog ureza izračunat je prema metodi koju su opisali i primijenili Singh i Pot-

348–351). It occurs in two main forms: active and healed (White et al. 2012: 449). The etiology of *cribra orbitalia* is multifactorial, resulting from the interaction of several factors that are not always distinguishable (Schats 2021). It is most commonly associated with inadequate nutrition, parasitism, and unhygienic living conditions (Hengen 1971; Wolter 1979; Griffeth et al. 1997), and the causes include megaloblastic and haemolytic anaemia (Walker et al. 2009), respiratory diseases (O'Donnell et al. 2020), metabolic diseases like scurvy, and infectious diseases such as malaria (Gowland, Western 2012).

Degenerative osteoarthritis manifests on bones as the appearance of osteophytes, eburnation, the formation of pits on joint surfaces, or changes in joint contours. It is characterized by the loss of joint cartilage and the reaction of subchondral bone and joint surface edges (Rogers, Waldron 1995: 34–36). Various factors influence the development of degenerative osteoarthritis, such as obesity or genetic predisposition, but biomechanical stress and individual age are the most significant contributors (Rogers, Waldron 1995: 33). Osteoarthritis most commonly affects load-bearing joints and is more frequent in older individuals (White, Folkens 2005: 325).

The articular facets of the vertebrae were considered asymmetrical when the superior and inferior articular facets on the posterior ends of the vertebra differed in size or when the superior and inferior auricular facets were not parallel (Mitchell, Redfern 2008: 67). Asymmetry was assessed macroscopically.

A lumbosacral transitional vertebra exhibits morphological characteristics of both the lumbar and sacral regions. It is a congenital anomaly which appears in two forms: sacralization and lumbarization. Sacralization, the more common form, refers to the incorporation of the last (fifth) lumbar vertebra into the sacrum. The sacrum's morphology remains unchanged, but an additional (fifth) sacral foramen is visible, while the spine consists of four lumbar vertebrae. Lumbarization, the less common form, is a congenital defect in which the first sacral vertebra is separated from the rest of the sacrum, resulting in a six-vertebrae lumbar spine. Both sacralization and lumbarization can be complete or partial, unilateral or bilateral, and symmetrical or asymmetrical (Aufderheide, Rodríguez-Martín 1998: 65).

The angle of the greater sciatic notch was calculated using the method described and implemented by Singh and Potturi (1978) and Shah et al. (2011). The angle of the greater sciatic

turi (1978) i Shah i suradnici (2011). Kut velikog sjednog ureza (< ACB) čini kut koji zatvaraju dvije zamišljene linije koje se protežu od koštanog zatka (*spina ischiadica*) na sjednoj kosti (A) i hvatišta za *m. piriformis* na bočnoj kosti (B) do točke u kojoj je veliki sjedni urez najdublji (C) (Shah et al. 2011: 27, Fig. 1). Normalne vrijednosti kuta velikog sjednog ureza kreću se oko 30° kod muškaraca te oko 60° kod žena (Šlaus 2006: 66). Za izračun kuta velikog sjednog ureza korišten je ImageJ software.

Anteverzija vrata bedrene kosti opisuje anteriorni otklon vrata bedrene kosti u odnosu na tijelo kada se osovina vrata nalazi ispred osovine kondila (Rubinić et al. 2003: 118; Mitchell, Redfern 2008: 65). U odrasloj populaciji prosječna anteverzija iznosi 10° do 15° (Shapiro 2001). Ukoliko je ovaj otklon veći normalnih vrijednosti, riječ je o povećanoj anteverziji to jest, antetorziji vrata bedrene kosti (Rubinić et al. 2003: 118). Kut anteverzije je izmjenjen prema metodi koju su razvili Kingsley i Olmsted (1948). Za obradu fotografija i izračun kuta anteverzije korišten je ImageJ software.

Entezalne promjene su patološke i nepatološke promjene na entezama, hvatištima mišića i tetiva na kostima (Berthon 2019: 18). Entezopatije su patološke promjene na entezama koje se mogu pojaviti kao rezultat mehaničkih faktora, mikrotraume, metaboličkih i endokrinih bolesti te upalnih procesa (Sudoł-Szopińska et al. 2015: 73). Metoda za određivanje stupnja razvoja entezopatija, kao i robusticiteta enteza korištene u ovome radu predložili su Marrioti i suradnici (2004; 2007). Marrioti i suradnici (2004: 148) definirali su dva tipa entezopatija: osteofitički tip (OF) kojeg karakterizira pojava entezofiza (EF) te osteolitički tip (OL) u kojemu je područje enteze porozno te je na njoj vidljivo erodirano područje.

## REZULTATI

Sve su kosti dobro očuvane, izuzev kostiju lica i stopala, koje nedostaju. Zbog promjena uočenih na području zdjelice nije bilo moguće procijeniti spol na temelju njezinih karakteristika. Kost lubanje su djelomično sačuvane, stoga spol osobe nije bilo moguće procijeniti sa sigurnošću. Svejedno, na temelju dostupnih elemenata (ulomci donje čeljusti, zatiljne i čelone kosti) kostur je procijenjen kao vjerojatno muški. Starosti u trenutku smrti procijenjena je između 30 i 35 godina. Zbog djelomično sačuvanih kostiju lubanje i njezine fragmentarnosti, nije bilo moguće uzeti kranijalne mjere. Postkranijalne mjere su prikazane u tab. 1.

notch (< ACB) is formed by two imaginary lines extending from the ischial spine (*spina ischiadica*) on the ischium (A) and the piriformis muscle attachment site on the ilium (B) to the deepest point of the greater sciatic notch (C) (Shah et al. 2011: 27, Fig. 1). Normal values for the greater sciatic notch range from 30° in women to 60° in men (Šlaus 2006: 66). The angle was measured using ImageJ software.

Femoral neck anteversion refers to the deviation of the femoral neck axis relative to the transverse axis of the condyles, where the neck axis is anterior to the condyle axis (Rubinić et al. 2003: 118; Mitchell, Redfern 2008: 65). In the adult population, average anteversion ranges from 10° to 15° (Shapiro 2001). Anteversion exceeding this range is referred to as increased anteversion or antetorsion of the femoral neck (Rubinić et al. 2003: 118). The angle of anteversion was measured according to the method developed by Kingsley and Olmsted (1948). ImageJ software was used for digital processing and measurement of the anteversion angle.

Entheseal changes are pathological and non-pathological changes at entheses, the sites where muscles and tendons attach to bones (Berthon 2019: 18). Enthesopathies are pathological changes of entheses that can develop as a result of mechanical stress, microtrauma, metabolic and endocrine diseases, or inflammation (Sudoł-Szopińska et al. 2015: 73). The method proposed by Marrioti et al. (2004; 2007) was used to score enthesopathies and entheses robusticity. According to Mariotti et al. (2004: 148), there are two types of enthesopathies: the osteophytic type, characterized by the appearance of enthesophytes, and the osteolytic type, where the entheses area is porous and eroded.

## RESULTS

All bones were well-preserved except for the missing facial bones and foot bones. Due to pathological changes, the morphology of the pelvis was altered, hindering sex determination based on its characteristics. The partially preserved skull prevented definitive sex determination. However, based on the available elements (mandible, occipital, and frontal bone fragments), the individual was probably male. Age at death was estimated to be between 30 and 35 years. Cranial measurements were impossible due to the partial preservation and fragmentation of the skull. Postcranial measurements are provided in Tab. 1.

Element / Element	Lijevo / Left (mm)	Desno / Right (mm)
<b>nadlaktična kost / humerus</b>		
najveća duljina / max. length	346	345
epikondilarna širina / epicondylar breadth	64	63
najveći promjer glave / max. vertical diam. of the head	47	/
najveći promjer na sredini kosti / max. diam. at midshaft	23	/
najmanji promjer na sredini kosti / min. diam. at midshaft	17,5	/
<b>palčana kost / radius</b>		
najveća duljina / max. length	260	/
A-P promjer na sredini kosti / A-P diam. at midshaft	14	/
M-L promjer na sredini kosti / M-L diam. at midshaft	16	/
<b>bedrena kost / femur</b>		
najveća duljina / max. length	460	458
bikondilarna širina / bicondylar length	16	16
epikondilarna širina / epicondylar breadth	76	78
najveći promjer glave / max diam. of the head	/	/
A-P subtrohanterični promjer / A-P subtroch. diam.	24	27
M-L subtrohanterični promjer / M-L subtroch. diam.	20,5	21
A-P promjer na sredini kosti / A-P diam. at midshaft	25	26
M-L promjer na sredini kosti / M-L diam. at midshaft	23	23
obujam na sredini kosti / circumference at midshaft	81	80
<b>goljenica / tibia</b>		
najveća duljina / max. length	/	406
najveća širina proksimalne goljenice / max. prox. epiphyseal breadth	/	/
najveća širina distalne goljenice / max. dist. epiphyseal breath	/	/
najveći promjer u razini hranidbenog otvora / max. diam. at the nutrient for.	33	32
M-L promjer u razini hranidbenog otvora / M-L diam. at the nutrient for.	23	23
obujam u razini hranidbenog otvora / circumference at the nutrient for.	90	87

Tab. 1 – Postkranijalne mjere kostura iz groba 16 (prema Buikstra, Ubelaker 1994: 69–84; izradila: T. Kokotović, 2024)

Tab. 1 – Postcranial measurements of the skeleton from grave 16 (after Buikstra, Ubelaker 1994: 69–84; made by: T. Kokotović, 2024)

Patološke su promjene uočene na kranijalnom i postkranijalnom dijelu kostura. Entezalne promjene uočene na kosturnim ostacima su prikazane u tab. 2. te na sl. 2. Osim na entezama prikazanim u tablici, na entezi za *m. infraspinatus* na nadlaktičnoj kosti uočen je makroporozitet (erodirano područje). Na očnjaku

Pathological changes were observed on both the cranial and postcranial skeleton. Enteseal changes observed on the skeletal remains are presented in Tab. 2 and Fig. 2. In addition to the changes described in the table, macroporosity (eroded areas) was observed on the entesis for *m. infraspinatus* on both humeri. Linear enamel



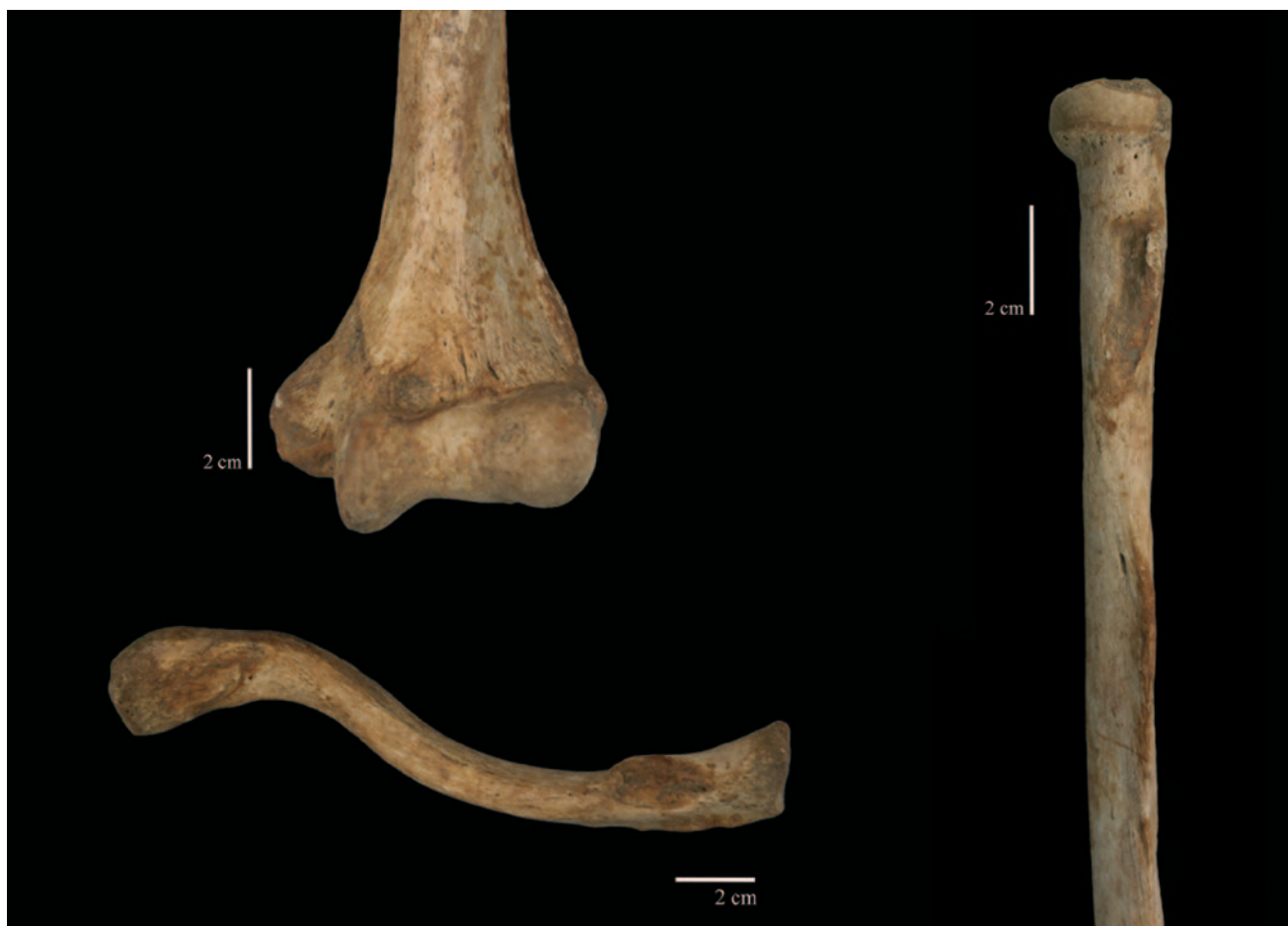Element / Element	Lijeva / Left			Desna / Right		
	Rob.	EF	OL	Rob.	EF	OL
<b>Lopatica / Scapula</b>						
<i>m. triceps brachii</i>	2	2		2	2	
<b>Ključna kost / Clavicula</b>						
kostoklavikularni lig. / costoclavicular lig.	3	2		3	2	
konoidni lig. / conoid lig.	1c			2		
trapezoidni lig. / trapezoid lig.	1c			2	1	
<i>m. deltoideus</i>	1c			2	1	
<i>m. pectoralis major</i>	1c	1		1c		
<b>Nadlaktična kost / Humerus</b>						
<i>m. pectoralis major</i>	1c					
<i>m. deltoideus</i>	1a			1a		
<i>m. latissimus dorsi / m. teres major</i>	1c			1c		
<i>m. brachioradialis</i>	3	1		3	1	
<b>Palčana kost / Radius</b>						
<i>m. biceps brachii</i>	2	2		3	3	
<i>m. pronator teres</i>	1c			1c		
međukošna opna (superiorni dio) / interosseous membrane (superior part)	1b			1c		
<b>Lakatna kost / Ulna</b>						
<i>m. triceps brachii</i>	2	1		2	1	
<i>m. supinator</i>	1c	1		2	1	
<b>Iver / Patella</b>						
tetiva četveroglavog mišića / quadriceps tendon				1c		
<b>Goljenica / Tibia</b>						
tetiva četveroglavog mišića / quadriceps tendon	2	1		2	1	

Tab. 2 – Entezalne promjene na kosturnim ostacima iz groba 16 (Rob. – robuscitet; EF – entezofitičke entezopatije; OF – osteolitičke entezopatije) (prema Marriotti et al. 2004; 2007; izradila: T. Kokotović, 2024)

Tab. 2 – Entheseal changes on the skeletal remains from grave 16 (Rob. – robusticity; EF – enthesophytic enthesopathies; OF – osteolytic enthesopathies) (after Marriotti et al. 2004; 2007; made by: T. Kokotović, 2024)

donje čeljusti (C<sub>3</sub>) prisutan je linearna hipoplazija zubne cakline. U desnoj orbiti prisutan je zarasli oblik *cribra orbitalie*. Degenerativni osteoarthritis zabilježen je na području prsne (T 3 – 10) i slabinske (L1 – 5) kralježnice te na zglobnim površinama glave rebra (*facies articularis tuberculi costae*) na tri rebra s desne i četiri rebra s lijeve strane. Asimetrija zglobnih ploha evidentirana je na jednom prsnom (T 12) i četiri slabinska (L1 – 3 i L 5) kralježaka (sl. 3). Djelomična, asimetrična lumbalizacija prvog sakralnog kralješka uočena je na lumbosakralnom dijelu kralježnice. Vidljiva karakteristična praznina između tijela prvog i drugog

hypoplasia was observed on the mandibular canine (C<sub>3</sub>). A healed form of *cribra orbitalia* was noted in the right orbit. Degenerative osteoarthritis was recorded on the thoracic (T3–10) and lumbar (L1–5) vertebrae, as well as on the auricular facets (*facies articularis tuberculi costae*) of three ribs on the right side and four ribs on the left side. Asymmetry of the articular facets on vertebrae was observed on one thoracic (T12) and four lumbar (L1–3 and L5) vertebrae (Fig. 3). Partial, asymmetrical lumbarization of the first sacral vertebra was observed on the sacrum. On the left side, the transverse process of the first sacral vertebra is not fused with the rest of the sacrum, and



Sl. 2 – Entezalne promjene na nadlaktičnoj, ključnoj i palčanoj kosti (snimila i prilagodila: T. Kokotović, 2024)  
Fig. 2 – Enthesal changes on the humerus, clavícula, and radius (photo and adapted by: T. Kokotović, 2024)



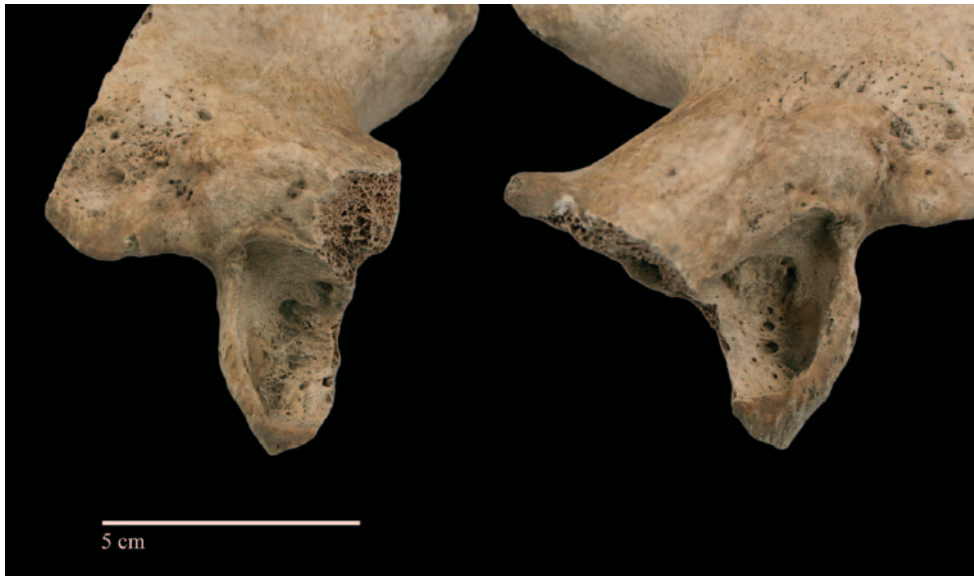Sl. 3 – Asimetrija zglobnih ploha na prsnom i slabinskom kralješku (snimila i prilagodila: T. Kokotović, 2024)  
Fig. 3 – Asymmetric lumbar facets on thoracic and lumbar vertebrae ((photo and adapted by: T. Kokotović, 2024)

sakralnog kralješka, a s lijeve strane poprečni nastavak prvog sakralnog kralješka nije spojen s ostatkom križne kosti.

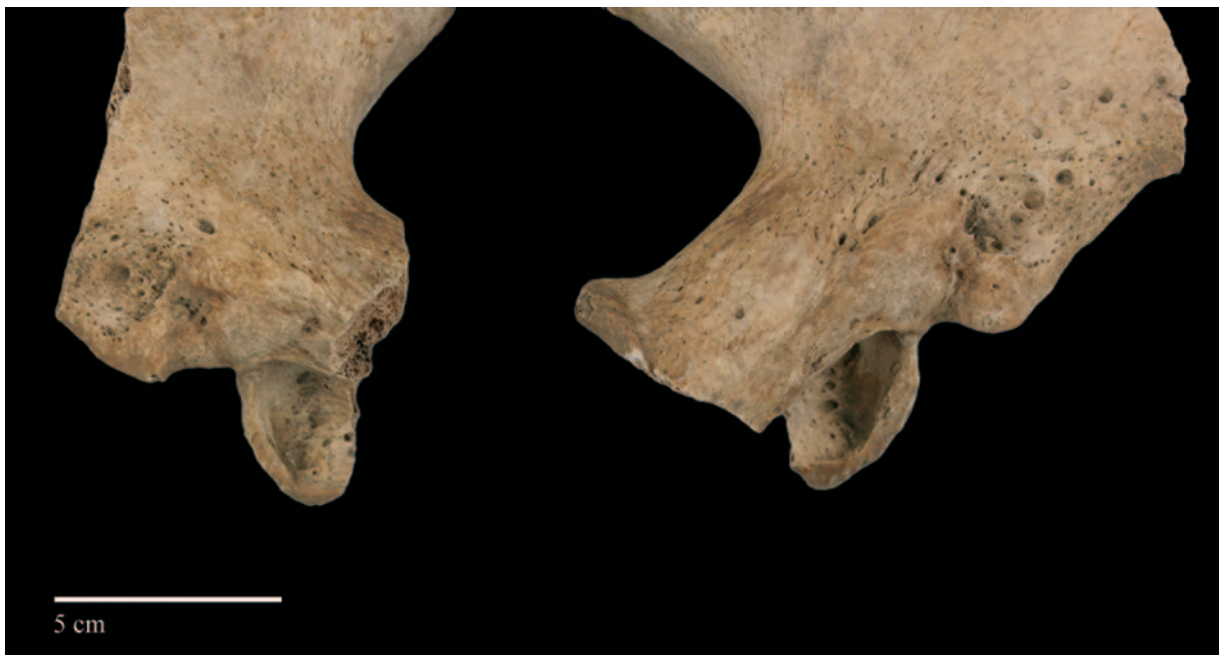Oba acetabula na zdjeličnim kostima nepravilnog (ovalno-trokutastog) su oblika, manjeg su

a characteristic gap is visible between the first and second sacral vertebrae.

Both acetabula on the pelvic bones are irregularly shaped (oval-triangular), smaller in diameter, and shallower than normal acetabula (Fig. 4). The



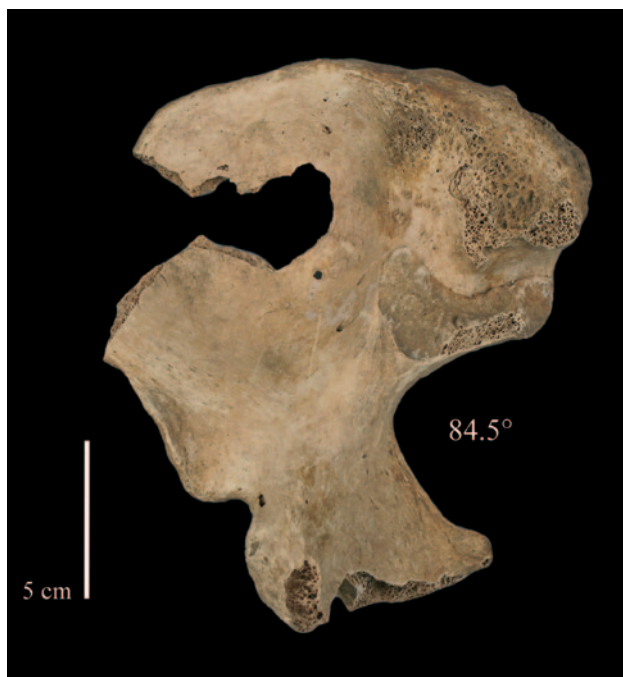Sl. 4 – Lijevi i desni acetabuli kostura iz groba 16 (snimila i prilagodila: T. Kokotović, 2024)  
Fig. 4 – Left and right acetabula on the skeleton from grave 16 (photo and adapted by: T. Kokotović, 2024)



Sl. 5 – Lažni acetabuli na kosturu iz groba 16 (snimila i prilagodila: T. Kokotović, 2024)  
Fig. 5 – False acetabula on the skeleton from grave 16 (photo and adapted by: T. Kokotović, 2024)

promjera te su plići nego u normalnim slučajevima (sl. 4). Zglobna ploha (*facies lunata*) nije vidljiva, a unutrašnjost je nepravilna te popraćena makroporozitetom i udubljenjima. Na bočnim kostima, prisutne su plitke ovalne udubine nepravilnog i poroznog dna (sl. 5). Na rubovima udubina prisutna je formacija nove kosti u obliku manjih koštanih spikula. Na lijevoj bočnoj kosti udubina se nalazi 22,5 mm superiorno od acetabula, dok se na desnoj nalazi 23,6 mm superiorno od acetabula. Kut velikog sjednog ureza na desnoj kosti zdjelice je povećan, a iznosi 84,5° (sl. 6). Zbog

joint surface (*facies lunata*) is not visible, and the inner surface is irregular, with macroporosity and cavitations. On the ilia, shallow oval depressions with irregular and porous bottoms were observed (Fig. 5). New bone formation in the form of small bony spicules was noted on the edges. The depression on the left ilium is located 22.5 mm superior to the acetabulum, while on the right ilium, it is located 23.6 mm superior to the acetabulum. The angle of the greater sciatic notch on the right pelvic bone is increased, measuring 84.5° (Fig. 6). Due to bone damage, it was not possible to



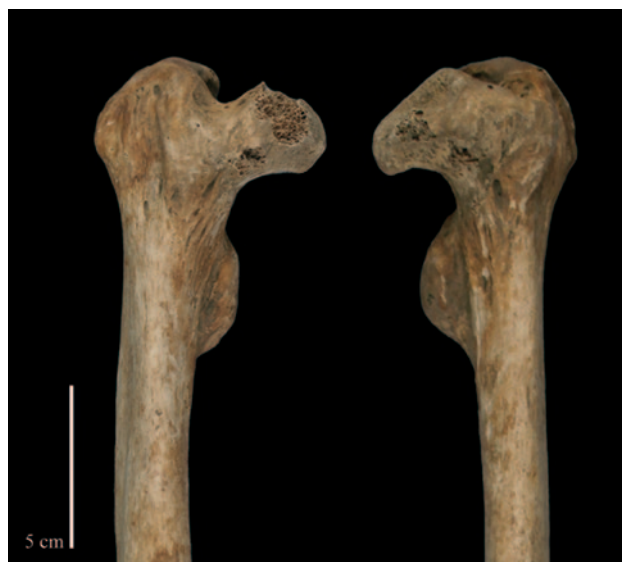Sl. 6 – Kut velikog sjednog ureza na desnoj zdjelici (snimila i prilagodila: T. Kokotović, 2024)  
Fig. 6 – Great sciatic notch angle on the right pelvic bone (photo and adapted by: T. Kokotović, 2024)

postmortalnog oštećenja kosti, na lijevoj strani kut velikog sjednog ureza nije bilo moguće izračunati. Glave obje bedrene kosti manjeg su opsega i volumena nego u normalnim slučajevima (sl. 7). Glava desne bedrene kosti je djelomično sačuvana, a glava lijeve bedrene kosti (koja je kompletno sačuvana) ovalnog je oblika, dimenzija 30 x 45 mm te je na njoj uočen porozitet. Vrat obje bedrene kosti je blago skraćen i zadebljan. Mali obrtač na obje bedrene kosti izduženog je oblika. Povećana anteverzija vrata uočena je na lijevoj bedrenoj kosti. Kut anteverzije na desnoj bedrenoj kosti iznosi 11,3°, a na lijevoj 38,6°.

## RASPRAVA

Abnormalnosti zgloba kuka mogu se pripisati različitim patološkim stanjima, pa su tako u diferencijalnu dijagnozu uključene bolesti i poremećaji koje zahvaćaju područje zgloba kuka, a promjene se posebno očituju na području glave i vrata bedrenih kosti te acetabula na zdjelici. To uključuje razvojni poremećaj kuka, Legg-Calvé-Perthesovu bolest, poskliz (epifiziolizu) glave bedrene kosti i bilateralni prijelom vrata bedrene kosti (tab. 3).

Legg-Calvé-Perthesova bolest definira se kao osteohondroza glave bedrene kosti, a rezultat je opstrukcije krvotoka u predjelu glave



Sl. 7 – Glave desne i lijeve bedrene kosti kostura iz groba 16 (snimila i prilagodila: T. Kokotović, 2024)  
Fig. 7 – Left and right femoral heads of the skeleton from grave 16 (photo and adapted by: T. Kokotović, 2024)

calculate the angle on the left side. The heads of both femora are smaller in volume and circumference than normal femora and are flattened (Fig. 7). The head of the right femur is partially preserved, while the head of the left femur (which is fully preserved) is oval-shaped (30x45 mm) with observable porosity. The necks of both femora are slightly shortened and thickened. The lesser trochanters on both femora are elongated. Increased anteversion of the femoral neck was observed on the left femur. The angle of anteversion on the right femur is 11.3°, and on the left, it is 38.6°.

## DISCUSSION

Abnormalities of the hip joint can result from various pathological conditions. Therefore, the differential diagnosis encompasses diseases and disorders that affect the hip joint, with the most notable changes visible on the head and neck of the femur and the acetabulum on the pelvis. These conditions include developmental dysplasia of the hip, Legg-Calvé-Perthes disease, slipped capital femoral epiphysis, and bilateral femoral neck fractures (Tab. 3).

Legg-Calvé-Perthes disease is defined as osteochondrosis of the femoral head, resulting from obstructed blood flow to the femoral head, which can lead to avascular necrosis (Aufderheide, Rodríguez-Martín 1998: 84). The disease most commonly develops in children between



bedrene kosti što može rezultirati avaskularnom nekrozom (Aufderheide, Rodríguez-Martín 1998: 84). Ova se bolest najčešće razvija kod djece između tri i deset godina starosti, te se češće javlja kod dječaka (80 %) nego kod djevojčica (Tripathy et al. 2010: 2). Najčešće zahvaća samo jedan zglob kuka, dok je bilateralnih slučajeva oko 10–20 %. Etiologija ove bolesti nije do kraja razjašnjena, no njezin razvoj mogu utjecati genetski, metabolički, okolišni, hormonalni i hematološki čimbenici (Salter 1999: 345–346; Pavone et al. 2019). Na koštanim materijalu promjene su vidljive na acetabulu na zdjelici te na glavi bedrene kosti (tab. 3) (Aufderheide, Rodríguez-Martín 1998: 84). S obzirom da je u slučaju Legg-Calvé-Perthesova bolesti glava bedrene kosti najčešće gljivolikog oblika, što u ovom primjeru nije uočeno, i u većini slučajeva glava bedrene kosti nastavlja artikulirati s acetabulom ova je bolest isključena. Poskliz (epifiziolizu) glave bedrene kosti karakterizira inferiorno-posteriorni pomak epifize glave bedrene kosti (Ortner, Puschar 1985: 239). Tijekom razvoja ovog poremećaja, pomak glave je postupan i ova se promjena može kategorizirati u tri stupnja; blagi, srednji i jači (MacEwan 1992: 70–71). Razvija se u adolescenciji, između desete i 15 godine života te češće pogađa muškarce nego žene (2,5 : 1) (Jaffe 1972: 537; Ortner, Puschar 1985: 239). Najčešće je zahvaćen jedan zglob, dok su bilateralni slučajevi pojavljuju u oko 25 %. Osim genetskih faktora, na njegov razvoj mogu utjecati pretilost, period naglog rasta u vrijeme puberteta te trauma (Aufderheide, Rodríguez-Martín 1998: 90). Kako inferiorno-posteriorni pomak glave bedrene kosti nije uočen, a linija frakture nije evidentirana, poskliz (epifizioliza) glave bedrene kosti je isključen. Bilateralni prijelom vrata bedrene kosti je isključen iz istog razloga. Također, kod prijeloma vrata bedrene kosti često su vidljivi i prijelomi na drugim koštanim elementima koju su posljedica iste epizode koja je dovela do prijeloma vrata bedrene kosti (Buckwalter et al. 2015: 73), a u ovom slučaju prijelomi na drugim kostima nisu uočeni. Osim toga, prijelom vrata bedrene kosti češći su kod starijih ljudi zbog smanjene gustoće trabekularne i kortikalne kosti (osteopenija, osteoporozna) te su bilateralni slučajevi iznimno rijetki (Buckwalter et al. 2015: 72). Neke od promjena uočenih na kosturu iz groba 16 (tab. 3) mogu se pripisati više spomenutih poremećaja i bolesti no uzimajući u obzir sve promjene uočene

the ages of three and ten and is more frequent in boys (80%) than in girls (Tripathy et al. 2010: 2). Typically, only one hip joint is affected, while bilateral cases occur in 10–20%. The etiology of this disease is not fully understood, but genetic, metabolic, environmental, hormonal, and hematological factors may contribute to its development (Salter 1999: 345–346; Pavone et al. 2019). Changes to the bones are visible on the acetabulum and the femoral head (Tab. 3) (Aufderheide, Rodríguez-Martín 1998: 84). Since the femoral head in cases of Legg-Calvé-Perthes disease is usually mushroom-shaped – an alteration not observed in this case – and usually continues to articulate with the acetabulum, Legg-Calvé-Perthes disease is excluded. Slipped capital femoral epiphysis is characterized by the inferior-posterior displacement of the femoral head epiphysis (Ortner, Puschar 1985: 239). During the development of the disorder, the displacement of the femoral head is gradual, and the severity can be categorized into three degrees: mild, moderate, and severe (MacEwan 1992: 70–71). It develops in adolescence, between the ages of ten and 15, and more frequently affects males than females (2.5:1) (Jaffe 1972: 537; Ortner, Puschar 1985: 239). Usually, one joint is affected, while bilateral cases occur in about 25% of cases. Besides genetic factors, obesity, periods of rapid growth during puberty, and trauma can influence its development (Aufderheide, Rodríguez-Martín 1998: 90). Since no inferior-posterior displacement of the femoral head was observed, and the fracture line was not evident, slipped capital femoral epiphysis is excluded. A bilateral femoral neck fracture was also excluded for the same reason. Moreover, in femoral neck fractures, other bone elements often show fractures resulting from the same episode that caused the femoral neck fracture (Buckwalter et al. 2015: 73), but no other fractures were observed in this case. Furthermore, femoral neck fractures are more common in older individuals due to decreased trabecular and cortical bone density (osteopenia, osteoporosis), and bilateral cases are extremely rare (Buckwalter et al. 2015: 72). Some of the changes observed on the skeleton from grave 16 (Tab. 3) can be attributed to several mentioned disorders and diseases, but considering all the changes observed on the skeleton from grave 16, it can be concluded that it is a case of developmental dysplasia of the hip (DDH). The most indicative signs of this disorder are the oval shape of the acetabulum and the appearance of shallow depressions on both

na kosturu iz groba 16 možemo zaključiti kako je riječ o razvojnom poremećaju kuka. Najindikativniji pokazatelji su ovalni oblik acetabula te pojava plitkih udubina na bočnim kostima koje predstavljaju lažni acetabul, to jest područje artikulacije glave bedrene kosti i bočne kosti.

Postoje tri tipa razvojnog poremećaja kuka. Prvi je definiran kao displazija kuka i podrazumijeva nedovoljnu razvijenosti kuka, kojeg karakterizira gubitak konkavnosti acetabula i nedovoljna natkrovljenost glave bedrene kosti no acetabul i glava bedrene kosti i dalje artikuliraju te tvore zglobov. Drugi je subluksacija, to jest djelomični gubitak kontakta acetabula i glave bedrene kosti, u kojem je glava bedrene kosti pomaknuta lateralno te artikulira s lateralnim rubom acetabula. Posljednji, treći, je dislokacija (luksacija) kuka, ili potpuni gubitak kontakta između glave bedrene kosti i acetabula. Glava bedrene kosti nije u kontaktu s acetabulom već artikulira s bočnom kosti, najčešće superiorno ili posterosuperiorno od acetabula. Na tom se mjestu pojavljuje lažni acetabul (Mitchell, Redfern 2008: 61–62; Blatt 2015: 121). U slučaju kostura iz groba 16, lažni su acetabuli uočeni na obje bočne kosti, a glava bedrene kosti ne artikuliraju s „pravim“ acetabulom već s lažnim (sl. 8). Na temelju ovog opisa možemo zaključiti kako je riječ o bilateralnoj dislokaciji kuka. U slučaju dislokacije i pojave lažnog acetabula, Mitchell i Redfern (2008) izdvojili su 4 tipa lažnog acetabula. Lažni acetabul tipa 1 opisan je kao glatka manja udubina, tip 2 definiran je kao sloj nove kosti nepravilne površine, tip 3 kao povišen koštani plak, te tip 4 predstavlja dublji acetabul kružnog oblika (Mitchell, Redfern 2008: 63). Prema svojim karakteristikama, lažni acetabuli uočeni na kosturu iz groba 16 odgovarali bi tipu 1 lažnog acetabula. Naime, riječ je o malim udubinama, no njihova unutrašnjost nije glatka, što je jedna od karakteristika ovog tipa. Međutim, u opisivanju prvog tipa acetabula, autori su izdvojili slučaj acetabula tipa 1 s makroporozitetom koji je mogao biti rezultat degenerativnih promjena ili upale (Mitchell, Redfern 2008: 63), što bi odgovaralo opisu lažnih acetabula kostura iz groba 16.

Osim navedenih promjena, i ostale se promjene na bedrenim kostima (povećana anteverzija vrata bedrene kosti), zdjelici (povećan kut sjednog ureza) i kralježnici (asimetrija zglobnih ploha na kralješcima, prijelazni kralježak u lumbosakralnoj regiji) uočene na kosturu iz groba

ilia, representing a false acetabulum, i.e. the area where the head of the femur would have articulated with the ilium.

There are three types of developmental dysplasia of the hip. The first type is hip dysplasia, involving insufficient development of the hip, characterized by the loss of acetabular concavity and inadequate coverage of the femoral head, but the acetabulum and femoral head still articulate and form a joint. The second type is subluxation, a partial loss of contact between the acetabulum and the femoral head, where the femoral head is displaced laterally and articulates with the lateral edge of the acetabulum. The third and final type is hip dislocation, a complete loss of contact between the femoral head and the acetabulum. In this case, the femoral head is not in contact with the acetabulum but articulates with the ilium, usually superior or posterosuperior to the acetabulum, and a false acetabulum appears at this point (Mitchell, Redfern 2008: 61–62; Blatt 2015: 121). On the skeleton from the grave 16, false acetabula were observed on both ilia, and the femoral head does not articulate with the “true” acetabulum but with the false one (Fig. 8). Based on this description, we can conclude that this is a case of bilateral hip dislocation. In cases of dislocation and the formation of a false acetabulum, Mitchell and Redfern (2008) identified four types of false acetabula. Type 1 is described as a small, smooth depression; type 2 as a layer of new bone with an irregular surface; type 3 as an elevated bony plaque; and type 4 represents a circularly shaped, deeper acetabulum (Mitchell, Redfern 2008: 63). Based on the observed changes, the false acetabula noted on the skeleton from grave 16 would correspond to type 1 false acetabulum. They are small depressions, but their interior is not smooth, which is one of the characteristics of this type. Interestingly, in describing the first type of acetabulum, the authors identified a case of type 1 false acetabulum exhibiting macroporosity, which could have resulted from degenerative changes or inflammation (Mitchell, Redfern 2008: 63). This corresponds with the changes observed on the false acetabula of the individual from grave 16.

Besides the aforementioned changes, other alterations observed on the femora (increased femoral neck anteversion), pelvis (increased angle of the great ischiatic notch), and spine (asymmetric articular facets on vertebrae and lumbosacral transitional vertebra) of the skeleton from grave



Sl. 8 – Lijevo lažni zglob kuka na kosturnim ostacima iz groba 16 (snimila i izradila: T. Kokotović, 2024)  
 Fig. 8 – Left false hip joint on the skeletal remains from grave 16 (photo and made by: T. Kokotović, 2024)

16 mogu povezati s RPK-om. U srednjovjekovnoj populaciji Londona povećana anteverzija vrata bedrene kosti zabilježena je u čak 83 % slučajeva (Mitchell Redfern 2008: 65), kao i na tri od devet kostura s RPK na groblju katedrale Notre-Dame-du-Borg u Digneu u Francuskoj (Mafart et al. 2007: 30–32) te u slučaju bilateralnog RPK iz Cape Towna u Južnoj Africi (Voegt et al. 2023: 30). U istraživanju RPK u srednjovjekovnoj populaciji Londona Mitchell i Redfern (2008) su također uočili širi kut sjednog ureza na pogođenoj strani u većini unilateralnih i bilateralnih slučajeva RPK. Vrijednosti kuta velikog sjednog ureza kretale su se u rasponu od 50° do 110° s prosječnom srednjom vrijednosti koja iznosi 85° (Mitchell, Redfern 2008: 64) što odgovara vrijednosti kuta sjednog ureza osobe iz groba 16. Širi kut velikog sjednog ureza zabilježen je u unilateralnom slučaju RPK kod djeteta iz srednjovjekovne Poljske (Agnew, Justus 2013), te u bilateralnim slučajevima RPK kod odraslih osoba u Nizozemskoj (Katzmarzyk, Schats 2011), Južnoj Africi (Voegt et al. 2023) i Argentini (Plischuk et al. 2018). Kao posljedica RPK-a, različiti oblici kompenzacijskih asimetrija mogu se pojaviti na području kralježnice te služe kao jedan od kriterija u dijagnozi ovog poremećaja na kosturnim ostacima. Na anteriornom dije-

16 can also be associated with DDH. In the medieval population of London, increased femoral neck anteversion was recorded in 83% of cases (Mitchell Redfern 2008: 65), as well as in three out of nine skeletons diagnosed with DDH from the cemetery of Notre-Dame-du-Borg Cathedral in Digne, France (Mafart et al. 2007: 30–32), and in the case of bilateral DDH from Cape Town, South Africa (Voegt et al. 2023: 30). In their study of DDH in the medieval population of London, Mitchell and Redfern (2008) also observed a wider sciatic notch on the affected side in most unilateral cases, as well as in bilateral cases of DDH. The angle of the greater sciatic notch on the affected side ranged from 50° to 110°, with an average value of 85° (Mitchell, Redfern 2008: 64). This range corresponds to the value of the sciatic notch angle of the skeleton from grave 16. A wider greater sciatic notch has also been recorded in a unilateral case of DDH in a child from medieval Poland (Agnew, Justus 2013) and in bilateral DDH cases in adults from the Netherlands (Katzmarzyk, Schats 2011), South Africa (Voegt et al. 2023), and Argentina (Plischuk et al. 2018). As a result of DDH, various forms of compensatory spinal asymmetries can develop, which can be used as diagnostic criteria for this disorder on skeletal remains. On the anterior part of the



lu kralježaka superiorne i inferiorne pokrovne plohe nisu uvijek paralelne, a na posteriornom dijelu razlike se mogu pojaviti u položaju i duljini poprečnih nastavaka kralježaka te u veličini i obliku zglobnih ploha na kralješcima. Kao krajnji rezultat ovih promjena (i njihove kombinacije na prsnom i slabinskom dijelu kralježnice) može se razviti skolioza na kralježnici (Mitchell, Redfern 2008: 67). Osim asimetrije u zglobnim ploham na području prsne i slabinske kralježnice, na kosturu iz groba 16 ostale promjene nisu uočene. Asimetrične zglobne plohe na slabinskim kralješcima su uočene u unilateralnim slučajevima RPK u srednjovjekovnoj populaciji Londona (Mitchell, Redfern 2008: 67), te na slabinskoj kralježnici muškarca pronađenog na groblju kasnosrednjovjekovnog franjevačkog samostana u Alkmaaru (Nizozemska) s unilateralnim RPK-om (Katzmarzyk, Schats 2011). Osim asimetrija, prirodene greške kralježnice, kao što je prijelazni kralježak u lumboskaralnoj regiji, također se mogu povezati s RPK-om (Sun et al. 2021). Sakralizacija je uočena kod muškarca pronađenog na srednjovjekovnom groblju u Devínu u Slovačkoj (Masnicová, Beňuš 2003: 272–273) koji je bolovao od unilateralnog RPK te u slučaju bilateralnog RPK-a kod muškarca iz Južne Afrike (Voegt et al. 2023) dok je lumbalizacija uočena na kosturu mlade žene (MSM12) pronađene u srednjovjekovnom samostanu Santa Maria in Valle u sjeveroistočnoj Italiji koja je bolovala od istog poremećaja (Saccheri, Travan 2022: 84). Ostale promjene koje se vežu uz RPK kao što su povećanje (varus položaj kuka, *coxa vara*) ili smanjivanje (valgus položaj kuka, *coxa valga*) kuta nagiba između vrata i tijela bedrene kosti (kolodijafizalni kut) kao i valgus položaj koljena nisu uočene. Također, popratni sindromi na kralježnici koji se povezuju s RPK-om, kao što su skolioza, lumbalna hiperlordoza, spondilolisteza i hemivertebra (Mitchell, Redfern 2008: 66–68) na kosturu iz groba 16 također nisu evidentirani. Položaji lažnog acetabula približno su jednaki na obje bočne, a dimenzije bedrenih kostiju, kao i ostalih dugih kostiju su slične (tab. 1). Na temelju tih dimenzija možemo zaključiti da je skraćenje nogu bilo jednako ili približno jednako, što je često u bilateralnim slučajevima RPK te omogućava bolju funkcionalnost nego u unilateralnim slučajevima (Voegt et al. 2023: 31).

Kliničke implikacije razvojnog poremećaja kuka uključuju rani razvoj osteoartritisa, bol te promjene u hodu, najčešće Trendelenburgov

vertebrae, the superior and inferior end plates may not always be parallel, and on the posterior part, differences may appear in the position and length of the transverse processes, as well as in the size and shape of the articular facets on the vertebrae. These changes, and their combination on the thoracic and lumbar spine, can lead to scoliosis (Mitchell, Redfern 2008: 67). Apart from the asymmetry of the auricular facets on the thoracic and lumbar spine, no other changes were observed on the skeleton from grave 16. Asymmetrical articular facets in the lumbar vertebrae were observed in unilateral cases of DDH in the medieval population of London (Mitchell, Redfern 2008: 67) and on the lumbar spine of a male affected with bilateral DDH from the late medieval Franciscan monastery in Alkmaar, the Netherlands (Katzmarzyk, Schats 2011). Apart from asymmetries, congenital spine defects, such as lumbosacral transitional vertebrae, can be associated with DDH (Sun et al. 2021). Sacralization was observed on a male skeleton from a medieval cemetery in Devín, Slovakia (Masnicová, Beňuš 2003: 272–273), who had unilateral DDH, and in a bilateral case of DDH in a male from South Africa (Voegt et al. 2023). Lumbarization was observed in a young female (MSM12) found in the medieval monastery of Santa Maria in Valle in northeastern Italy (Saccheri, Travan 2022: 84). Other changes associated with DDH, such as an increase (varus hip position, *coxa vara*) or decrease (valgus hip position, *coxa valga*) of the angle of inclination between the neck and the body of the femur (collodiaphyseal angle) and valgus knee position, were not observed. Additionally, accompanying spinal syndromes associated with DDH, such as scoliosis, lumbar hyperlordosis, spondylolisthesis, and hemivertebra (Mitchell, Redfern 2008: 66–68), were also absent in the skeleton from grave 16. The false acetabula are positioned approximately equally on both sides, and the lengths of the leg bones (femora) and other long bones are similar (Tab. 1). Based on these measurements, we can conclude that the shortening of the legs was either equal or approximately equal, which is common in bilateral cases of DDH and allows for better functionality than in unilateral cases (Voegt et al. 2023: 31).

Clinical implications of developmental dysplasia of the hip include early-onset osteoarthritis, pain, and gait changes, most commonly Trendelenburg gait or waddling gait in cases whe-

hod ili geganje pri hodu u slučajevima kada je zahvaćen jedan zglob (Voegt et al. 2023: 42). Bol se najčešće pojavljuje u području prepona, zgloba kuka, koljena i donjeg dijela leđa, nije prisutna tijekom djetinjstva no može se pojaviti već tijekom adolescencije (Dezateux, Rosendhal 2007: 1547). Najčešće je uzrokovana pojavom osteoartritisa na području lažnog acetabula, koljena i kralježnice, povećava se s dobi te može biti izraženija nakon aktivnosti koje zahtijevaju nošenje određenog tereta, uključujući i dugotrajno stajanje ili hodanje (Dezateux, Rosendhal 2007: 1547, Blatt 2015: 118; Voegt et al. 2023: 31). Na pojavu degenerativnih promjena i boli u području kuka utječe i tip lažnog acetabula. U slučajevima kada je lažni acetabul plitak (tip 1, 2 i 3) degenerativne promjene koje uzrokuju bol najčešće se javljaju nakon četrdesete godine, dok u slučaju dubljeg acetabula (tip 4) lažni će se zglob ranije potrošiti te se degenerativne promjene, pa tako i bol uzrokovana njima javljaju ranije, već u mlađoj životnoj dobi (Mitchell, Redfern 2008: 70). Iako se kod tipa 1 lažnog acetabula bol pojavljuje kasnije u životu, pojava osteoartritisa na kralježnici, lažnom acetabulu te na području koljena ukazuje na to da je u svojoj odrasloj dobi pokojnik iz groba 16 vjerojatno osjećao određenu bol uzrokovanu ovim stanjem. Na to je, osim degenerativnih promjena, također mogla utjecati i lumbalizacija, to jest prijelazni kralježak, koji u slučajevima degradacije diska, uklještenja živaca, degenerativnih promjena ili promjene u rasporedu opterećenja u unilateralnim slučajevima može izazvati oštre bolove u donjem dijelu leđa (Mahato 2010: 911).

## Entezalne promjene

Osim promjena povezanih s RPK, na kosturu su uočene i promjene na entezama pretežito na gornjim ekstremitetima, dok su enteze na kostima nogu, izuzev koljena, puno gracilnije. Osim izraženog robusticiteta, mišići *m. triceps brachii*, *m. deltoideus*, *m. pectoralis major*, *m. brachioradialis*, *m. biceps brachii*, *m. supinator* i *m. infraspinatus* (tab. 2) se ističu i po pojavi entezopatija. Promjene se pojavljuju bilateralno, što ukazuje kako na to da je mehanički stres bio podjednak na obje ruke, te nije moguće razlučiti koja je ruka bila dominantna. Mišići na čijim su entezama uočene promjene koriste se u pokretima koji uključuju adukciju (*m. pectoralis major*) i abdukciju (*m. deltoideus*), lateralnu ro-

re one joint is affected (Voegt et al. 2023: 42). Pain typically arises in the pelvic area, hip joint, knee, and lower back. While it is not present during childhood, it can emerge during adolescence (Dezateux, Rosendahl 2007: 1547). It is primarily caused by the onset of degenerative changes in the false acetabulum, knee, and spine. It increases with age and can be more pronounced after load-bearing activities, including prolonged standing or walking (Dezateux, Rosendahl 2007: 1547, Blatt 2015: 118; Voegt et al. 2023: 31). The type of false acetabulum also influences the occurrence of degenerative changes and pain in the hip area. In cases where the false acetabulum is shallow (types 1, 2, and 3), degenerative changes causing pain usually occur after the age of 40. In contrast, in case of a deeper acetabulum (type 4), the false joint deteriorates earlier, leading to the earlier onset of degenerative changes and pain, sometimes even in young adulthood (Mitchell, Redfern 2008: 70). Although pain usually appears later in life for type 1 false acetabula, the presence of osteoarthritis on the spine, false acetabulum, and knee suggests that the individual from grave 16 likely experienced some degree of pain in adulthood due to this condition. In addition to degenerative changes, lumbarization, or lumbosacral transitional vertebrae, could also have contributed to pain. In cases of disc degradation, pinched nerves, degenerative changes or changes in load distribution in unilateral cases can cause sharp pain in the lower back region (Mahato 2010: 911).

## Enteseal changes

Apart from the changes associated with DDH, enteseal changes, primarily on the upper extremities, were also observed, while entheses on the lower extremities were much more gracile. In addition to robusticity, enthesopathies were evident on *m. triceps brachii*, *m. deltoideus*, *m. pectoralis major*, *m. brachioradialis*, *m. biceps brachii*, *m. supinator*, and *m. infraspinatus* (Tab. 2). The bilateral nature of these changes suggests that both arms experienced similar physical stress, making it impossible to differentiate a dominant hand. The muscles exhibiting enteseal changes are most commonly involved in adduction (*m. pectoralis major*), abduction (*m. deltoideus*), lateral rotation (*m. infraspinatus*, *m. teres minor*), flexion (*m. biceps brachii*, *m. deltoideus*), and

taciju (*m. infraspinatus*, *m. teres minor*), fleksiju (*m. biceps brachii*, *m. deltoideus*) i ekstenziju (*m. triceps brachii*, *m. deltoideus*) ruke te fleksiju (*m. brachioradialis*, *m. pronator teres*) i ekstenziju (*m. triceps brachii*) lakta kao i supinaciju podlaktice (*m. supinator*) (Paulsen, Waschake 2011: 160–185). Ovi se mišići i pokreti mogu povezati s nizom aktivnosti, između ostalog s korištenjem štaka ili nekog pomagala za hod. Künsel i suradnici (1992), Künsel i Göggel (1993) te Belcastro i Mariotti (2000) objavili su detaljan opis entezalnih promjena uočenih na gornjim ekstremitetima koje su autori povezali s korištenjem štaka. Kao repetitivne pokrete koji se koriste prilikom korištenja štaka autori izdvaaju adukciju ramena i podlaktice, supinaciju te lateralnu i medijalnu rotaciju nadlaktice kao i fleksiju i ekstenziju lakta (Künsel et al. 1992: 112–114; Künsel, Göggel 1993: 161–162; Belcastro, Mariotti 2000: 536). Prilikom korištenja štaka, lateralna i medijalna rotacije te adukcija nadlaktice su potrebne kako bi osoba zamahnula štakama ispred sebe (Künsel, Göggel 1993: 163); lakat je u fleksiji tijekom podizanja štake (Künsel et al. 1992: 114), a podlaktica je u supinaciji dok se tijelo pomiče prema naprijed (Künsel et al. 1992: 116). Na kosturu svećenika iz srednjovjekovne bolnice svetog Egidija u sjevernom Yorkshireu koji je bolovao od unilateralnog poskliza glave bedrene kosti, autori su na kostima podlaktice i šaka<sup>5</sup> uočili entezalne promjene. Promjene su uočene na desnoj palčanoj i lakatnoj kosti, na hvatištima za *m. biceps brachii* i *m. brachialis*, a uočena je i razvijena stražnja kvržica (*tuberculum dorsale*) na distalnom dijelu palčane kosti (Künsel et al. 1992: 112–116). Na kosturu muškarca pronađenog na groblju srednjovjekovne bolnice svetog Jakova i Marije Magdalene u Chicesteru (West Sussex, UK) koji je bolovao od lepre, na kostima desne ruke i zgloba ramena uočene entezalne promjene. Promjene su vidljive na lopatici (*m. teres minor*, *m. triceps brachii*), ključnoj kosti (*m. pectoralis major*, *m. subclavicularis*, *ligamentum costoclaviculare*), nadlaktičnoj kosti (*m. deltoideus*, te na hvatištima mišića pregibača i opružaća na distalnom dijelu nadlaktične kosti) te na lakatnoj (*margo intraosseus ulnae* i *m. supinator*) i palčanoj kosti (*m. biceps brachii*, *m. pronator teres*, *m. pronator quadratus*) (Künsel, Göggel 1993: 159–163). Belcastro i Mariotti

extension (*m. triceps brachii*, *m. deltoideus*) of the arm; flexion (*m. brachioradialis*, *m. pronator teres*) and extension (*m. triceps brachii*) of the elbow; and supination (*m. supinator*) of the forearm (Paulsen, Waschake 2011: 160–185). These movements and muscles can be associated with various activities, one of which could be the use of crutches or other walking aids. Künsel et al. (1992), Künsel and Göggel (1993), and Belcastro and Mariotti (2000) have provided detailed descriptions of enthesal changes on the upper extremities which they associate with crutch use. Repetitive movements involved in crutch use include shoulder adduction, humeral adduction, supination, lateral and medial rotation, as well as elbow flexion and extension (Künsel et al. 1992: 112–114; Künsel, Göggel 1993: 161–162; Belcastro, Mariotti 2000: 536). During crutch use, lateral and medial rotation, along with adduction, of the forearm occur when the person swings the crutch forward in front of the body (Künsel, Göggel 1993: 163); the elbow is flexed when lifting the crutch off the ground (Künsel et al. 1992: 114), and the forearm is supinated when the body moves forward (Künsel et al. 1992: 116). On the skeleton of a priest from the medieval St Giles' Hospital in northern Yorkshire, who suffered from a unilateral case of the slipped proximal femoral epiphysis, the authors observed enthesal changes on the bones of the forearm and hand.<sup>5</sup> These include changes on the right ulna and radius, at the entheses for the *m. biceps brachii* and *m. brachialis*, as well as an overdeveloped *tuberculum dorsale* on the distal end of the radius (Künsel et al. 1992: 112–116). Similarly, on the male skeleton affected by leprosy from the cemetery of the medieval hospital of Sts. James and Mary Magdalene in Chichester (West Sussex, UK), enthesal changes were observed on the right shoulder and arm. These changes were visible on the scapula (*m. teres minor*, *m. triceps brachii*), clavicle (*m. pectoralis major*, *m. subclavicularis*, *ligamentum costoclaviculare*), humerus (*m. deltoideus*, and the entheses for the flexor and extensor muscles on the distal end of the humerus), and on the ulnae (*margo intraosseus ulnae* and *m. supinator*) and radius (*m. biceps brachii*, *m. pronator teres*, *m. pronator quadratus*) (Künsel, Göggel 1993: 159–163). When describing changes on a male skeleton from

5 Nažalost nadlaktice i kosti ramenog zgloba nisu pronađene (Künsel et al. 1992: 112).

5 Unfortunately, the bones of the shoulder region and humera were not found (Künsel et al. 1992:112).

(2000) su na primjeru muškarca pronađenog u rimskoj nekropoli Casalecchio di Reno u Bolonji izdvojili *m. teres minor*, *m. infraspinatus*, *m. triceps brachii*, *m. anconeus*, *m. deltoideus* i *m. pectoralis major* na čijim se hvatištima pojavljuju promjene koje upućuju na njihovo pretjerano korištenje uzrokovano korištenjem štaka (Belcastro, Mariotti 2000: 536). U novijoj literaturi, Van Kant (2018) je entezalne promjene uočene na desnoj nadlaktičnoj kosti (*m. pectoralis major*, *m. deltoideus*) i lijevoj ključnoj kosti (*ligamentum costoclaviculare*) mlade žene iz kasnosrednjovjekovne ruralne zajednice s lokaliteta Mooresl u Belgiji čiji je desna noga bila amputirana također povezala s korištenjem štaka. Ako promotrimo entezalne promjene zabilježene na kostima ruku i rame-nog zgloba uočene na kosturu iz groba 16 (tab. 2), te uzmemo u obzir i RPK koji je mogao utjecati na nesmetano kretanje osobe, one mogu sugerirati da je pokojnik iz groba 16 za hodanje koristio štake ili neko drugo pomagalo za hod. Nažalost, ovo ostaje tek samo pretpostavka. Osim entezalnih promjena, Künsel i suradnici (1992) i Künsel i Göggel (1993) su na kosturnim ostacima uočili i degenerativne promjene na karpalnim i metakarpalnim kostima koje su rezultat fleksije metakarpalnih kostiju i sugeriraju jak stisak, kao i degenerativne promjene na području ramena, lakta i zapešća kao rezultat mehaničkog stresa izazvanog opterećenjem koje bi odgovaralo korištenju štaka. Slične su promjene uočili i Belcastro i Mariotti (2000). Na pokojniku iz groba 16 takve promjene nisu uočene, no treba napomenuti kako su gore navedeni primjeri pripadaju starijim osobama<sup>6</sup>, dok je pokojnik iz groba 16 ipak nešto mlađi te ako je štake ili neku vrstu pomagala za hod koristio samo dio života (kasnije u životu kada su se razvile degenerativne promjene povezane s RPK-om te je počeo osjećati bol) nije nužno da bi razvio ovakve degenerativne promjene. Osim degenerativnih promjena, moderna istraživanja također povezuju i prijelom zamora na lateralnoj strani lopatice s korištenjem pomagala za hod (Darton 2010: 119) međutim ovakva promjena nije uočena na lopaticama pokojnika iz groba 16. U paleopatološkoj literaturi slučajevi RPK

the Roman necropolis of Casalecchio di Reno in Bologna (Italy), Belcastro and Mariotti (2000) highlighted muscles *m. teres minor*, *m. infraspinatus*, *m. triceps brachii*, *m. anconeus*, *m. deltoideus*, and *m. pectoralis major*, whose attachment sites exhibit changes suggestive of their overuse due to crutch use (Belcastro, Mariotti 2000: 536). In more recent publications, Van Kant (2018) proposed that the enthesal changes observed on the right humerus (*m. pectoralis major*, *m. deltoideus*) and left clavicle (*ligamentum costoclaviculare*) of a young female from the late medieval rural community at the Mooresl site in Belgium, whose right leg was amputated, were indicative of crutch use. Looking at the enthesal changes on the upper extremities observed on the skeleton from grave 16 (Tab. 2), and considering the DDH which could have influenced the individual's movement and gait, it is possible that these changes are related to the use of crutches or some other walking aid. However, this remains speculative. In addition to enthesal changes, Künsel et al. (1992) and Künsel and Göggel (1993) observed degenerative changes on carpal and metacarpal bones resulting from the flexion suggestive of a tight grip, as well as degenerative changes on the shoulders, elbows and wrists caused by mechanical stress from crutch use. Similar changes were observed by Belcastro and Mariotti (2000). While degenerative changes on these skeletal elements were not observed on the skeleton from grave 16, it is important to note that those other individuals were older than the person from grave 16<sup>6</sup>, and if he used crutches later in his life, after the development of degenerative changes related to DDH and the onset of pain, it is not strictly necessary for him to have also developed degenerative changes related to crutch use. In addition to degenerative changes, modern research mentions a stress fracture on the lateral aspect of the scapula in connection with crutch use (Darton 2010: 119), but no such fractures were noted on the skeleton from grave 16. In the palaeopathological literature, cases of DDH and associated crutch use are not well-documented. However, Voegt et al. (2023: 30–31) observed enthes-

6 Za muškarca iz srednjovjekovne bolnice svetog Egidija (sjeverni Yorkshire) nije specificirana starost, no opisan je kao „jako star u trenutku smrti“ (Künsel et al. 1992: 110); muškarac iz bolnice svetog Jakova i Marije Magdalene u Chichesteru je imao najmanje 45 godina u trenutku smrti (Künsel, Göggel 1993: 154); muškarac iz rimske nekropole Casalecchio di Reno u Bolonji opisan je kao „stariji muškarac“ (Belcastro, Mariotti 2000: 530).

6 Although the exact age at death was not specified, a male from St Giles' Hospital in Yorkshire was described as “probably quite old at his death” (Künsel et al. 1992: 110); a male from the Hospital of Sts. James and Mary Magdalen in Chichester was at least 45 years old at the time of his death (Künsel, Göggel 1993: 154); a male from the necropolis of Casalecchio di Reno in Bologna was described as an „aged male skeleton“ (Belcastro, Mariotti 2000: 530).

koji se dovode uvezu s korištenjem štaka ili nekog drugog pomagala za hod nisu podrobno opisani. Voegt i suradnici (2023: 30–31) su uočili entezalne promjene na kostima ruku kod muškarca iz Južne Afrike koji je bolovao od RPK te ističu mogućnost kako su osobi bile potrebne štake ili neka vrsta pomagala za hod, no zaključuju kako entezalne promjene na kostima ukazuju kako je osoba za života bila aktivna unatoč invalidnosti. Nadalje, Caffell i Holst (2010: 8–9) su na kosturnim ostacima žene pronađene na lokalitetu Crkva sv. Mihaela i Lovre u Fewstonu u sjevernom Yorkshireu, čiji je desni kuk bio dislociran, uočili izražene entezalne promjene na kostima obje ruke, zgloba ramena i lijeve noge na temelju kojih su predložili mogućnost kako je žena za života koristila štake. Nažalost, autorice nisu izdvojile mišiće na čijim su entezama promjene uočene niti su entezalne promjene opisane.

## Utjecaj na svakodnevni život

O povijesti Novske nam nije puno toga poznato prije dolaska Osmanlija u 16. stoljeću (Marković 2002). Područje današnjeg grada Novske u srednjem vijeku pripadalo je južnom dijelu velikog posjeda Svetačje, koji je obuhvaćao prostor od pakračkog prostora na sjeveru, rijeke Save na jugu, Lipovljana i Kraljeve Velike na zapadu te granice Brodsko-posavske županije na istoku (Marković 2002: 539). Ovim je prostorom u razvijenom i kasnom srednjem vijeku gospodarila plemićka obitelj Tiboldovića-Svetački (Škiljan 2007: 129). Kao i ostatak Slavonije, i ovo je područje u tom periodu bilo relativno gusto naseljeno seljacima koji su bili podanici velikaša ili crkve s obavezom davanja dijela dohodaka, isprva u obliku naturalnih davanja, a kasnije i u novcu (Škiljan 2007: 122–123). Utvrde koje su se nalazile u njihovom posjedu, pa i crkva sv. Luke Evanđeliste predstavljali su političke, vojne i duhovne centre karakteristične za onodobno feudalno uređenje. Osim njih, na širem su području zabilježeni i ostaci manjih naselja ruralnog karaktera, koji su najvjerojatnije, kao i ostatak Slavonije u to doba, bili dominantno orijentirani na poljoprivrednu proizvodnju (Drnić, Zorić 2021: 17). U tom kontekstu, pojava zaraslog oblika *cribrae orbitaliae* u desnoj orbiti te linearne hipoplazije zubne cakline na očnjaku donje čeljusti kod pokojnika iz groba 16 svjedoči o lošijem zdravstvenom stanju u vrijeme djetinjstva te se uklapa u sliku o životu u

al changes on the upper extremities of a male from South Africa affected by DDH and suggested the possibility of crutch or other walking aid use, but concluded that the individual was fairly active during their lifetime despite the disability. Moreover, Caffell and Holst (2010: 8–9) observed enthesal changes on both arms, shoulders, and bones of the left leg of a female skeleton from the Church of St. Michael and Lawrence in Fewston (North Yorkshire), who suffered from unilateral hip dislocation. They suggested that the female used crutches during her life. Unfortunately, the authors did not specify which entheses were affected, nor did they describe the exact changes observed on them.

## Impact on daily life

Unfortunately, little is known about the history of Novska prior to the arrival of the Ottoman Empire in the 16<sup>th</sup> century (Marković 2002). In the medieval period, the area of modern-day Novska belonged to the southern part of the Svetačje estate, which encompassed the area from Pakrac and the surrounding region in the north to the River Sava in the south and from Lipovljan and Kraljeva Velika in the west to the border of the Brod-Posavina County in the east (Marković 2002: 539). In the High and Late Middle Ages, this area was under the administration of the Tibaldović-Svetački noble family (Škiljan 2007: 129). Like the rest of Slavonia, this region was densely populated by rural communities under the jurisdiction of local noble families or the Church. These communities were obligated to contribute a portion of their income, initially as payment in kind and later in money (Škiljan 2007: 122–123). The forts within their estates, as well as the Church of St. Luke the Evangelist, represented the political, military, and spiritual centres characteristic of the feudal society of that time. In addition to the forts, remains of smaller, rural villages were also found in the wider area. Like the rest of Slavonia at that time, these villages were primarily agricultural (Drnić, Zorić 2021: 17). Given this context, healed *cribra orbitalia* on the right orbit and linear enamel hypoplasia on the mandibular canine, observed on the remains from grave 16, attest to poor childhood health which is consistent with similar findings from medieval communities in continental Croatia. Both changes are well-documented in medieval

kontinentalnoj Hrvatskoj u razdoblju srednjega vijeka. Obje su promjene dobro dokumentirane u srednjovjekovnim populacijama kontinentalne Hrvatske (Novak et al. 2009; Novak, Bedić 2011; Krznar, Hajdu 2020), a ukazuju na periode fiziološkog stresa u vrijeme djetinjstva koji su mogli biti izazvani različitim faktorima, kao što su nehidijenski uvjeti života, neadekvatna prehrana, parazitizam i druga gastrointestinalna oboljenja, a generalno loše zdravstveno stanje u vrijeme djetinjstva karakteristično je za srednjovjekovne zajednice kontinentalne Hrvatske (Krznar, Hajdu 2020: 182). U takvom društvu, primarno orijentiranom na poljoprivredu, pokojnik iz groba 16, s visokim stupnjem RPK sigurno je bio u određenoj mjeri bio ograničenu obavljanju svakodnevnih aktivnosti. Čak i ako je bio u određenoj mjeri funkcionalan, sigurno nije mogao samostalno i nesmetano sudjelovati u obavljanju svih svakodnevnih aktivnosti, pogotovo ako su one uključivale težak fizički rad, nošenje tereta ili dugotrajno stajanje i hodanje. Slične su zaključke predstavili i drugi autori opisujući slučajeve RPK u arheološkim populacijama. Đukić i suradnici (2021: 78) zaključuju kako muškarac pronađen u nekropoli u Velebitu u sjevernoj Srbiji koja datira iz 2. i 3. stoljeća vjerojatno bio ograničen u obavljanju svakodnevnih aktivnosti koje su uključivale bavljenje poljoprivredom, lov ili ratovanje, te da mu je bila potrebna pomoć zajednice u svakodnevnom životu. Možda bliži primjeri dolazi novovjekovnog sela Bobald u Transilvaniji. Eng i suradnici (2009: 30) navode kako su dvije žene s RPK-om vjerojatno bile ograničene u sudjelovanju u svakodnevnim aktivnostima, radovima u poljoprivredi i stočarstvu te navode kako je bilo koje tjelesno oboljenje, pa tako i RPK, moglo negativno odraziti ne samo na njihov život, već i na egzistenciju i život njihovih obitelji.

## ZAKLJUČAK

Razvojni poremećaj kuka jedna je od češćih poremećaja koja se danas relativno lagano dijagnosticira i ispravlja već u najranijoj dobi. Svejedno, ovaj se poremećaj rijetko bilježi u arheološkim populacijama. Jedini dosad objavljeni mogući primjer s prostora današnje Hrvatske evidentiran je relativno nedavno, u novovjekovnoj populaciji u Đakovu (Kriletić et al. 2023), dok je drugi predstavljen u ovome radu.

Riječ je o kosturu odrasle osobe, vjerojatno muškarca, iz kasnog srednjeg vijeka s lokaliteta

populations in the region (Novak et al. 2009; Novak, Bedić 2011; Krznar, Hajdu 2020). They suggest periods of physiological stress during childhood caused by various factors and their combinations, including unhygienic living conditions, inadequate nutrition, parasitic and other gastrointestinal diseases, and generally poor health conditions, which are characteristic of medieval communities in continental Croatia (Krznar, Hajdu 2020: 182). In a primarily agricultural community, an individual with advanced DDH, such as the one from the grave 16, would certainly have been limited in performing everyday activities, especially those involving physical labour, load-carrying, or prolonged walking or standing. Similar conclusions have been drawn by other authors researching cases of DDH in archaeological populations. Đukić et al. (2021: 78) suggested that a male found in the necropolis of Velebit in northern Serbia, dated to the 2<sup>nd</sup> and 3<sup>rd</sup> centuries, would likely have been limited in his ability to perform everyday activities, especially agricultural activities, hunting, or warfare, and would have needed the assistance of the community in his daily life. A much closer example comes from the early modern period village of Bobald in Transylvania. Eng et al. (2009: 30) stated that two females diagnosed with DDH were probably limited in their ability to participate in everyday activities, agricultural work, and husbandry. They argued that any kind of physical impediment, including DDH, would not only have reflected poorly on the affected individuals but also on the lives and livelihoods of their families.

## CONCLUSION

Developmental dysplasia of the hip is a relatively common disorder that is easily recognised and treated in the modern world. Nevertheless, this disorder is rare in archaeological populations. The only other possible case of this disorder from the territory of present-day Croatia is reported relatively recently, in the early modern population of Đakovo (Kriletić et al. 2023). The case presented in this paper is the second such case.

The presented case involves an adult skeleton, probably male, dating from the late medieval period, from the site of the Church of St. Luke the Evangelist in Novska. Based on the pathological changes observed on the skeletal remains, we concluded that the individual

crkva sv. Luke Evanđeliste u Novskoj. Na temelju patoloških promjena uočenim na kosturnim ostacima, možemo zaključiti kako je pokojnik iz groba 16 bolovao od razvojnog poremećaja kuka koji je rezultirao dislokacijom oba zgloba kuka. Degenerativne promjene uočene u oba lažna acetabula, zajedno s lumbalizacijom evidentiranom na području lumboskralne kralježnice sugeriraju da je tijekom života čovjek osjećao određeni stupanj boli uzorkovane ovim poremećajem, koji je također otežavao njegovo nesmetano kretanje te obavljanje svakodnevnih aktivnosti. S obzirom da je područje Novske i njezine okolice u kasnom srednjem vijeku bilo ruralnog karaktera čije se stanovništvo pretežitavo bavilo poljoprivredom, ovaj poremećaj i njegovi simptomi su uvelike mogli utjecati i otežati život pokojnika iz groba 16. Nadalje, entezalne promjene na kostima ramenog zgloba i ruku sugeriraju kako je pokojnik iz groba 16 za života ipak bio aktivan, te u kombinaciji s RPK-om, otvaraju mogućnost da su navedene promjene uzrokovane korištenjem štaka ili nekog drugog pomagala za hod, no nažalost tu pretpostavku na temelju bioarheološke analize trenutno nismo u mogućnosti sa sigurnošću potvrditi. Ova studija slučaja kostura iz groba 16 donosi rekonstrukciju čovjekova života te pruža nova saznanja o životu u srednjovjekovnoj Novskoj i njezinoj okolici, periodu o kojemu imamo malo informacija iz arheoloških i povijesnih izvora.

## Napomena

Ovaj je rad financirala Hrvatska zaklada za znanost projektom *Razvoj i naslijeđe viteških redova u Hrvatskoj* (milOrd) (HRZZ, IP-2019-04-5513).

suffered from DDH, resulting in the dislocation of both hip joints. Degenerative changes observed on both false acetabula, along with transitional vertebrae noted in the lumbosacral region, suggest that the individual experienced some degree of pain during his lifetime, caused by this disorder, which also made it difficult for him to move freely and perform his daily activities. Given that Novska and its surroundings were rural areas in the Middle Ages, primarily focused on agriculture, this disorder and its associated symptoms would have greatly affected the individual buried in grave 16, making their life more difficult. Moreover, enthesal changes observed on the shoulders and arms of the deceased suggest that he was active during his lifetime. In conjunction with DDH, this raises the possibility that the observed changes were caused by crutch use, but unfortunately, this assumption is difficult to verify through bioarchaeological analysis. This case study of the skeleton from grave 16 provides a reconstruction of the individual's life and offers new insights into life in medieval Novska and its surroundings, a period about which we have limited information from archaeological and historical sources.

## Acknowledgement

This work was supported by the Croatian Science Foundation under the project *Development and Heritage of the Military Orders in Croatia* (milOrd) (HRZZ, IP-2019-04-5513).

**Prijevod** Translation

**PORIN ŠČUKANEC REZNIČEK, TEA KOKOTOVIĆ**

**Lektura** Proofreading **MARKO MARAS**

## INTERNETSKI IZVORI INTERNET SOURCES

**Datawrapper** – Datawrapper GmbH, [www.datawrapper.de](http://www.datawrapper.de)

**OpenStreetMap** – Open StreetMap Foundation (OSMF), [www.openstreetmap.org/copyright](http://www.openstreetmap.org/copyright)

## LITERATURA BIBLIOGRAPHY

- Agnew, A. M., Justus, H. M.** 2013, Developmental dysplasia of the hip in a child from medieval Poland, in: *40<sup>th</sup> Annual North American Meeting*, Knoxville, Tennessee, April 9–10, 2013, (s.ed.), book of abstracts, Paleopathology Newsletter Supplement, Paleopathology Association, s.l., 25.
- AlQahtani, S. J., Hector, M. P., Liversidge, H. M.** 2010, Brier Communication: The London atlas of human tooth development and eruption, *American Journal of Physical Anthropology*, Vol. 142(3), 481–490. <https://doi.org/10.1002/ajpa.21258>
- Arnaud, G., Arnaud, S.** 1975, Luxation congénitale bilatérale de la hanche et manifestations d'hyperostose porotique sur un squelette d'époque paléo-chrétienne, *Bulletins et Mémoires de la Société d'Anthropologie de Paris*, Vol. 2–4, 307–326.
- Aufderheide, A. C., Rodríguez-Martín, C.** 1998, *The Cambridge Encyclopedia of Human Paleopathology*, Cambridge University Press, Cambridge.
- Ausel, E.** 2016, Down but not out: a probable case of congenital hip dysplasia in the late prehistoric Native American community, in: *43<sup>rd</sup> Annual North American Meeting*, Atlanta, Georgia, April 12<sup>th</sup>–13<sup>th</sup>, 2016, book of abstracts, Paleopathology Association Scientific Program, 33.
- Belaj, J., Stingl, S.** 2019, O arheološkim istraživanjima crkve sv. Luke Evanđeliste u Novskoj 2018. godine, *Annales Instituti Archaeologici*, Vol. XV, 75–99.
- Belaj, J., Stingl, S.** 2021, Otkrivanje novljanskih tajni: prikaz arheoloških istraživanja crkve sv. Luke Evanđeliste, in: *Arheološka baština novljanskog kraja*, 2. prošireno izdanje, Drnić I. (ed.), Arheološki muzej u Zagrebu, Pučko otvoreno učilište Novska, Zagreb – Novska, 29–38.
- Belcastro, M. G., Mariotti, V.** 2000, Morphological and Biomechanical Analysis of a Skeleton from Roman Imperial Necropolis of Casalecchio di Reno (Bologna, Italy, II–III c. A. D.). A Possible Case of Crutch Use, *Collegium Anthropologicum*, Vol. 24(2), 529–539.
- Berthon, W.** 2019, *Bioarchaeological analysis of the mounted archers from the Hungarian Conquest period (10<sup>th</sup> century): Horse riding and activity-related skeletal changes*, Unpublished PhD Thesis, Université Paris sciences et lettres, Paris; Szegedi Tudományegyetem, Szeged.
- Blatt, S. H.** 2015, To Swaddle, or Not to Swaddle? Paleoepidemiology of Developmental Dysplasia of the Hip and the Swaddling Dilemma Among the Indigenous Populations of North America, *American Journal of Human Biology*, Vol. 27(1), 116–128. <https://doi.org/10.1002/ajhb.22622>
- Blondiaux, J., Millot, F.** 1991, Dislocation of the hip: Discussion of eleven cases from mediaeval France, *International Journal of Osteoarchaeology*, Vol. 1(3–4), 203–207. <https://doi.org/10.1002/oa.1390010311>
- Brooks, S., Suchey, J. M.** 1990, Skeletal age determination based on the Os Pubis: A comparison of the Acsádi-Nemeskéri and Suchey-Brooks methods, *Human Evolution*, Vol. 5(3), 227–238. <https://doi.org/10.1007/BF02437238>
- Buckwalter, J., Westerlind, B., Karam, M.** 2015, Asymmetric Bilateral Hip Dislocations: A Case Report and Historical Review of the Literature, *The Iowa Orthopaedic Journal*, Vol. 35, 70–91.
- Buikstra, J. E.** 2010, Paleopathology: A Contemporary Perspective, in: *A Companion to Biological Anthropology*, Larsen C. S. (ed.), Wiley-Blackwell, Oxford, 395–411. <https://doi.org/10.1002/9781444320039.ch22>
- Buikstra, J. E., Ubelaker, D.** 1994, *Standards for data collection from human skeletal remains*, Arkansas Archaeological Survey, Fayetteville, Arkansas.
- Caffell, A. C., Holst, M.** 2010, *Osteological Analysis, The Church of Saint Michael and Saint Lawrence, Fewston*, York Osteoarchaeology Ltd, York. <https://doi.org/10.5284/1025701>
- Cableaux, M. S.** 1997, Congenital dislocation of the hip in the prehistoric northeast, *Bulletin of the New York Academy of Medicine*, Vol. 53(4), 338–346.
- Chan, A., McCaul, K. A., Cundy, P. J., Haan, E. A., Byron-Scott, R.** 1997, Perinatal risk factors for developmental dysplasia of the hip, *Archives of Disease in Childhood – Fetal and Neonatal Edition*, Vol. 76 (2), 94–100. <https://doi.org/10.1136/fn.76.2.f94>
- Costa Junqueira, M. A., Llagostera Martínez, A.** 1994, Coyo 3: Momentos finales del Período Medio en San Pedro de Atacama, *Estudios Atacameños*, Vol. 11, 73–107. <https://doi.org/10.22199/S07181043.1994.0011.00005>
- Darton, Y.** 2010, Scapular Stress Fracture: A Palaeopathological Case Consistent with Crutch Use, *International Journal of Osteoarchaeology*, Vol. 20(1), 113–121. <https://doi.org/10.1002/oa.1002>
- Dawes, J. D., Magilton, J. R.** 1980, *The Cemetery of St Helen-on-the-Walls, Aldwark, The Medieval Cemeteries*, The Archaeology of York, The Medieval Cemeteries 12(1), Council for British Archaeology for York Archaeological Trust, York.
- Demo, Ž.** 2007, *Opatovina. Tragovi povijesti izgubljene u sadašnjosti. Rezultati arheoloških iskopavanja pred crkvom svetog Franje u Zagrebu 2002. godine*, Arheološki muzej u Zagrebu, Zagreb.
- Dezateux, C., Rosendhal, K.** 2007, Developmental dysplasia of the hip, *The Lancet*, Vol. 369(9582), 1541–1552. [https://doi.org/10.1016/S0140-6736\(07\)60710-7](https://doi.org/10.1016/S0140-6736(07)60710-7)
- Drnić, I., Zorić, J.** 2021, Arheološka baština novljanskog kraja, in: *Arheološka baština novljanskog kraja*, 2. prošireno izdanje, Drnić I. (ed.), Arheološki muzej u Zagrebu, Pučko otvoreno učilište Novska, Zagreb – Novska, 9–18.
- Đapić, T., Bergovec, M.** 2010, O razvojnom poremećaju kuka općenito, in: *Razvojni poremećaj kuka*, Delimar D. (ed.), Klinički bolnički centar Zagreb, Zagreb, 15–30.



- Đukić, K., Milenković, P., Pavlović, T., Nestorović, D., Ramadanski, R., Đurić, M.** 2021, The case of hip dysplasia of an adult from the Roman Period site of Velebit (Serbia), *Journal of Bioanthropology*, Vol. 1, 73–80.
- Eng, J. T., Szócs, P., Hagen, C.** 2009, Developmental Dysplasia of the Hip in a Post-Medieval Transylvanian Population: Case study and Diagnosis, *Paleopathology Newsletter*, Vol. 148, 25–32.
- Forst, J., Forst, C., Forst, R., Heller, K.-D.** 1997, Pathogenetic relevance of the pregnancy hormone relaxin to inborn hip instability, *Archives of Orthopaedic and Trauma Surgery*, Vol. 116, 209–212. <https://doi.org/10.1007/bf00393711>
- Gilbert, B. M., McKern, T. W.** 1973, A method for aging the female Os pubis, *American Journal of Physical Anthropology*, Vol. 38(1), 31–38. <https://doi.org/10.1002/ajpa.1330380109>
- Goodman, A. H., Rose, J. C.** 1990, Assessment of systemic physiological perturbations from dental enamel hypoplasias and associated histological structures, *American Journal of Biological Anthropology: Supplement American Journal of Physical Anthropology*, Vol. 33(S11), 59–110. <https://doi.org/10.1002/ajpa.1330330506>
- Gowland, R. L., Western, A. G.** 2012, Morbidity in the Marshes: Using Spatial Epidemiology to Investigate Skeletal Evidence for Malaria in Anglo-Saxon England (AD 410–1050), *American Journal of Physical Anthropology*, Vol. 147(2), 301–311. <https://doi.org/10.1002/ajpa.21648>
- Griffeth, M. T., Dailey, R. A., Ofner, S.** 1997, Bilateral spontaneous subperiosteal hematoma of the orbits: a case report, *The Archives of Ophthalmology*, Vol. 115(5), 679–680. <https://doi.org/10.1001/archophth.1997.01100150681026>
- Hengen, O. P.** 1971, Cribra Orbitalia: Pathogenesis and Probable Aetiology, *Homo*, Vol. 22, 57–75.
- Hefti, F., Brunner, R., Hasler, C. C., Jundt, G.** 2007, *Pediatric Orthopedics in Practice*, Springer, Berlin – Heidelberg. <https://doi.org/10.1007/978-3-540-69964-4>
- Jaffe, H. L.** 1972, *Metabolic, Degenerative, and Inflammatory Diseases of Bones and Joints*, Lea and Febiger, Philadelphia.
- Katzmarzyk, C., Schats, R.** 2011, Conflicting Pelvic Morphology in a Pathological Late Medieval Skeleton from the Netherlands, poster presentation, *The Missing*, British Association for Human Identification (BAHID) Conference, 9<sup>th</sup>–10<sup>th</sup> April, 2011, Manchester, United Kingdom.
- Kingsley, P. C., Olmsted, K. L.** 1948, A study to determine the angle of anteversion of the neck of the femur, *The Journal of Bone and Joint Surgery. American Volume*, Vol. 30(3), 745–751.
- Klales, A. R.** (ed.) 2020, *Sex estimation of the human skeleton. History, methods, and Emerging Techniques*, Academic Press, London. <https://doi.org/10.1016/C2017-0-03550-4>
- Kriletić, B., Ivanušec, D., Carić, M., Novak, M.** 2023, The usual suspects: deciphering the epidemiology, variation of injuries and lifestyle in Late Medieval / Early Modern population from Đakovo, *Arheološki radovi i rasprave*, Vol. 22, 211–234. <https://dx.doi.org/10.21857/9e31lhzg8m>
- Krznar, S., Hajdu, T.** 2020, Kasnosrednjovjekovna i ranonovovjekovna populacija iz Ivankova, istočna Hrvatska: rezultati (bio)arheološke analize / Late medieval/early modern population from Ivankovo, eastern Croatia: the results of the (bio)archaeological analysis, *Prilozi Instituta za arheologiju u Zagrebu*, Vol. 37, 165–194. <https://doi.org/10.33254/pijaz.37.6>
- Künsel, C. J., Chundun, Z. C., Cardwell, P.** 1992, Slipped proximal femoral epiphysis in a priest from the medieval period, *International Journal of Osteoarchaeology*, Vol. 2(2), 109–119. <https://doi.org/10.1002/oa.1390020203>
- Künsel, C. J., Göggel, S.** 1993, A Cripple from the Medieval Hospital of Sts James and Mary Magdalen, Chichester, *International Journal of Osteoarchaeology*, Vol. 3(3), 155–165. <https://doi.org/10.1002/oa.1390030302>
- Larsen, C. S., Walker, P. L.** 2010, Bioarchaeology: Health, Lifestyle, and Society in Recent Human Evolution, in: *A Companion to Biological Anthropology*, Larsen C. S. (ed.), Wiley-Blackwell, Oxford, 379–394. <https://doi.org/10.1002/9781444320039.ch21>
- Loder, R. T., Skopelja, E. N.** 2011, The Epidemiology and Demographics of Hip Dysplasia, *International Scholarly Research Notice*, Vol. 2011, 238607. <https://doi.org/10.5402%2F2011%2F238607>
- Lovejoy, C. O., Meindl, R. S., Pryzbeck, T. R., Mensforth, R. P.** 1985, Chronological metamorphosis of the auricular surface of the ilium: A new method for the determination of adult skeletal age at death, *American Journal of Physical Anthropology*, Vol. 68, 15–28. <https://doi.org/10.1002/ajpa.1330680103>
- MacEwan, G. D.** 1992, Epiphisiolisis de la cabeza femoral, in: F. H. Netter, *Sistema musculoesquelético. Trastornos del desarrollo, tumores, enfermedades reumáticas y reemplazamiento articular. Tomo 8.2A*, Colección Ciba de Ilustraciones Médicas, Salvat, Barcelona, 70–71.
- Mafart, B., Kéfi, R., Béraud-Colomb, E.** 2007, Palaeopathological and Paleogenetic Study of 13 Cases of Developmental Dysplasia of the Hip with Dislocation in a Historical Population from Southern France, *International Journal of Osteoarchaeology*, Vol. 17, 26–38. <https://doi.org/10.1002/oa.857>
- Mahan, S. T., Kasser, J. R.** 2008, Does Swaddling Influence Developmental Dysplasia of the Hip?, *Pediatrics*, Vol. 121(1), 177–178. <https://doi.org/10.1542/peds.2007-1618>
- Mahato, N. K.** 2010, Morphological traits in sacra associated with complete and partial lumbarization of first sacral segment, *The Spine Journal*, Vol. 10(10), 910–915. <https://doi.org/10.1016/j.spinee.2010.07.392>
- Manaster, B. J.** 2016, *Diagnostic Imaging: Musculoskeletal: Non-Traumatic Disease*, 2<sup>nd</sup> edition, Elsevier, Philadelphia.
- Marriotti, V., Facchini, F., Belcastro, M. G.** 2004, Enthesopathises – Proposal of a Standardized Scoring Method and Applications, *Collegium Anthropologicum*, Vol. 28(1), 145–159.
- Marriotti, V., Facchini, F., Belcastro, M. G.** 2007, The Study of Enthesis: Proposal of the Standardised Scoring Method for Twenty-Three Entheses of the Postcranial Skeleton, *Collegium Anthropologicum*, Vol. 31(1), 291–313.

- Marković, M.** 2002, *Slavonija. Povijest naselja i podrijetlo stanovništva*, Golden marketing, Zagreb.
- Masnicová, S., Beňuš, R.** 2003, Developmental Anomalies in Skeletal Remains from the Great Moravia and Middle Ages Cemeteries at Devín (Slovakia), *International Journal of Osteoarchaeology*, Vol. 13(5), 266–274. <https://doi.org/10.1002/oa.684>
- Meindl, R. S., Lovejoy, C. O.** 1985, Ectocranial suture closure: A revised method for the determination of skeletal age at death based on the lateral-anterior sutures, *American Journal of Physical Anthropology*, Vol. 68(1), 57–66. <https://doi.org/10.1002/ajpa.1330680106>
- Mitchell, P. D., Redfern, R. C.** 2007, The Prevalence of Dislocation in Developmental Dysplasia of the Hip in Britain over the Past Thousand Years, *Journal of Pediatric Orthopaedics*, Vol. 27(8), 890–892. <https://doi.org/10.1097/bpo.0b013e31815a6091>
- Mitchell, P. D., Redfern, R. C.** 2008, Diagnostic Criteria for Developmental Dislocation of the Hip in Human Skeletal Remains, *International Journal of Osteoarchaeology*, Vol. 18(1), 61–71. <https://doi.org/10.1002/oa.919>
- Mitchell, P. D., Redfern, R. C.** 2011, Brief Communication: Developmental Dysplasia of the Hip in Medieval London, *American Journal of Physical Anthropology*, Vol. 144(3), 479–484. <https://doi.org/10.1002/ajpa.21448>
- Moodie, R. L.** 1923, *Paleopathology. An Introduction to the Study of Ancients Evidences of Disease*, University of Illinois Press, Urbana.
- Novak, M., Šlaus, M., Pasarić, M.** 2009, Subadultni stres u srednjovjekovnim i novovjekovnim populacijama kontinentalne Hrvatske / Subadult Stress in the Medieval and Early Modern Populations of Continental Croatia, *Prilozi Instituta za arheologiju u Zagrebu*, Vol. 26, 247–270.
- Novak, M., Bedić, Ž.** 2011, Bioarheološke karakteristike srednjovjekovne populacije s nalazišta Suhopolje – Kliškovac, in: *Suhopolje – Kliškovac. Od mjestopisa do arheološke spoznaje*, Tomičić Ž., Jelinčić K. (eds.), Monographiae Instituti Archaeologici 4, Institut za arheologiju, Zagreb, 167–174.
- O'Donnell, L., Hill, E. C., Anderson Anderson, A. S., Edgar, H. J. H.** 2020, Cribra orbitalia and porotic hyperostosis are associated with respiratory infections in a contemporary mortality sample from New Mexico, *American Journal of Physical Anthropology*, Vol. 173 (4), 721–733. <https://doi.org/10.1002/ajpa.24131>
- Ortner, D. J., Puschar, W. G.** 1985, *Identification of Pathological Conditions in Human Skeletal Remains*, Smithsonian Institution Press, Washington D.C.
- Paulsen, F., Waschke, J.** 2011, *Sobotta Atlas of Human Anatomy. General Anatomy and Musculoskeletal System*, 15<sup>th</sup> edition, Urban & Fischer, Munich.
- Pavone, V., Chisari, E., Vescio, A., Lizzio, C., Sessa, G., Testa, G.** 2019, Aetiology of Legg- Calvé-Perthes disease: a systematic review, *World Journal of Orthopaedics*, Vol. 10(3), 145–165. <https://doi.org/10.5312/wjo.v10.i3.145>
- Petrella, E., Piciucchi, S., Feletti, F., Barone, D., Piraccini, A., Minghetti, C., Gruppioni, G., Poletti, V., Bertocci, M., Traversari, M.** 2016, CT Scan of Thirteen Natural Mummies Dating Back to the XVI-XVIII Centuries: An Emerging Tool to Investigate Living Conditions and Diseases in History, *PLOS ONE*, Vol. 11(6), e0154349. <https://doi.org/10.1371/journal.pone.0154349>
- Pindborg, J. J.** 1970, *Pathology of Dental Hard Tissues*, Saunders, Philadelphia.
- Plischuk, M., De Feo, M. E., Desántolo, B.** 2018 Developmental dysplasia of the hip in female adult individual: Site Tres Cruces I, Salta, Argentina (Superior formative period, 400–1000 AD), *International Journal of Paleopathology*, Vol. 20, 108–113. <https://doi.org/10.1016/j.ijpp.2017.08.003>
- Roberts, C., Manchester, K.** 2010, *The Archaeology of Disease*, 3<sup>rd</sup> edition, The History Press, Gloucestershire.
- Rogers, J., Waldron, T.** 1995, *A Field Guide to Joint Disease in Archaeology*, John Wiley & Sons Ltd, Chichester.
- Rubinić, D., Gulan, G., Mikačević, M., Ravlić-Gulan, J., Schnurrer-Luke-Vrbanić, T.** 2003, Anteverzija vrata femura, vrijednosti, mjerenje, najčešći klinički problem, *Medicina: glasilo Hrvatskoga liječničkoga zbora, Podružnica Rijeka*, Vol. 40, 118–121.
- Salter, R. B.** 1999, *Textbook of Disorders and Injuries of the Musculoskeletal System*, 3<sup>rd</sup> edition, Lippincott Williams & Wilkins, Philadelphia.
- Saccheri, P., Travan, L.** 2022, The limping nuns. Two cases of hip dislocation in a medieval female monastery, *Italian Journal of Anatomy and Embryology*, Vol. 126(1), 81–91. <https://doi.org/10.36253/ijae-13633>
- Schats, R.** 2021, Cribrotic lesions in archaeological human skeletal remains. Prevalence, co-occurrence, and association in medieval and early modern Netherlands, *International Journal of Paleopathology*, Vol. 35, 81–89. <https://doi.org/10.1016/j.ijpp.2021.10.003>
- Singh, S., Potturi, B. R.** 1978, Greater sciatic notch in sex determination, *Journal of Anatomy*, Vol. 125(3), 619–624.
- Shapiro, F.** 2001, *Pediatric Orthopaedic Deformities: Basic Science, Diagnosis and Treatment*, Academic Press, San Diego.
- Shah, D. S., Zalawadia, D. A., Ruparelia, D. S., Patel, D. S., Rathod, D. S. P., Patel, D. S. V.** 2011, Morphometric study of greater sciatic notch of dry human hip bone in Gujarat region, *National Journal of Integrated Research in Medicine*, Vol. 2(2), 27–30. <https://doi.org/10.70284/njirm.v2i2.1904>
- Smith, B. H.** 1984, Patterns of molar wear in hunter-gatherers and agriculturalists, *American Journal of Physical Anthropology*, Vol. 63(1), 39–56. <https://doi.org/10.1002/ajpa.1330630107>
- Sudoł-Szopińska, I., Kwiatkowska, B., Prochorec-Sobieszek, M., Maśliński, W.** 2015, Enthesopathies and enthesitis. Part 1. Etiopathogenesis, *Journal of Ultrasonography*, Vol. 15(60), 72–84. <https://doi.org/10.15557%2FJoU.2015.0006>

- Sun, J., Chhabra, A., Thakur, U., Vazquez, L., Xi, Y., Wells, J.** 2021, The association of lumbosacral transitional vertebral anomalies with acetabular dysplasia in adult patients with hip–spine syndrome, *The Bone & Joint Journal*, Vol. 103-B(8), 1351–1357. <https://doi.org/10.1302/0301-620X.103B8.BJJ-2020-2481.R1>
- Šlaus, M.** 2006, *Bioarheologija. Demografija, zdravlje, trauma i prehrana starohrvatskih populacija*, Školska knjiga, Zagreb.
- Škiljan, F.** 2007, Kratak osvrt na razdoblje razvijenog i kasnog srednjeg vijeka i ranog novog vijeka na području stare župe Svetačje (Novska i okolina), *Zbornik Moslavine*, Vol. IX–X (2006–2007), 122–132.
- Thomas, C.** 2004, *Life and Death in London's East End: 2000 years of Spitalfields*, Museum of London Archaeology Service, London.
- Tripathy, S., Kumar, S. R., Dhatt, S., Goyal, T.** 2010, Legg-calve-perthes Disease: Current Concepts, *Webmed Central Orthopaedics*, Vol. 1(11), WMC001173.
- Van Kant, M.** 2018, Surviving Amputations: A Case of a Late-Medieval Femoral Amputation in the Rural Community of Moorsel (Belgium), in: *Trauma in Medieval Society*, Turner W. J., Lee C. (eds.), Brill, Leiden, 180–214. [https://doi.org/10.1163/9789004363786\\_010](https://doi.org/10.1163/9789004363786_010)
- Vasilcova, V., AlHarthi, M., AlAmri, N., Sagat, P., Bartik, P., Jawadi, A. H., Zvonar, M.** 2022, Developmental Dysplasia of the Hip: Prevalence and Correlation with Other Diagnoses in Physiotherapy Practice—A 5-Year Retrospective Review, *Children*, Vol. 9(2), 247. <https://doi.org/10.3390/children9020247>
- Voegt, C., Gunston, G., Nortje, M., Sealy, J. C., He, L., le Roux, P., Namayega, C., Gibbon, V. E.** 2023, Bilateral hip dysplasia in a South African male: A case study from the 17–18th century, *International Journal of Paleopathology*, Vol. 42, 27–33. <https://doi.org/10.1016/j.ijpp.2023.07.002>
- Vrdoljak, O., Kolarić, D., Vrdoljak, J.** 2019, Razvojni poremećaj kuka: prevencija i konzervativno liječenje djeteta u dobi od prvog do šestog mjeseca, *Paediatrica Croatica*, Vol. 63(2), 71–73. <https://doi.org/10.13112/PC.2019.11>
- Wakely, J.** 1993, Bilateral congenital dislocation of the hip, spina bifida occulta and spondylosis in a female skeleton from the medieval cemetery at Abingdon, England, *Journal of Paleopathology*, Vol. 1, 37–45.
- Wang, E., Liu, T., Li, J., Edmonds, E. W., Zhao, Q., Zhang, L., Zhao, X., Wang, K.** 2012, Does swaddling influence developmental dysplasia of the hip? An experimental study of the traditional straight-leg swaddling model in neonatal rats, *The Journal of Bone and Joint Surgery. American volume*, Vol. 94(12), 1071–1077. <https://doi.org/10.2106/jbjs.k.00720>
- Waldron, T.** 2020, *Paleopathology*, 2<sup>nd</sup> edition, Cambridge University Press, Cambridge. <https://doi.org/10.1017/9781108583961>
- Walker, P. L., Bathurst, R. R., Richman, R., Gjerdrum, T., Andrushko, V. A.** 2009, The Causes of Porotic Hyperostosis and Cribra Orbitalia: A Reappraisal of the Iron–Deficiency–Anemia Hypothesis, *American Journal of Physical Anthropology*, Vol. 139(2), 109–125. <https://doi.org/10.1002/ajpa.21031>
- White, T. D., Folkens, P. A.** 2005, *The Human Bone Manual*, 3<sup>rd</sup> edition, Academic Press, Oxford. <https://doi.org/10.1016/C2009-0-00102-0>
- White, T. D., Black, M. T., Folkens P. A.** 2012, *The Human Osteology*, 3<sup>rd</sup> edition, Academic Press, Oxford. <https://doi.org/10.1016/C2009-0-03221-8>
- Wolter, J. R.** 1979, Subperiosteal hematomas of the orbit in young males: a serious complication of trauma or surgery in the eye region, *The Journal of Pediatric Ophthalmology and Strabismus*, Vol. 16(5), 291–296. <https://doi.org/10.3928/0191-3913-19790901-06>
- Yamamuro, T., Ischida, K.** 1984, Recent advances the prevention, Early Diagnosis and Treatment of Congenital Dislocation of the Hip in Japan, *Clinical Orthopaedics and Related Research*, Vol. 184, 34–40.